ORIGINAL RESEARCH PAPER

Volume-6 | Issue-10 | October-2017 | ISSN No 2277 - 8179 | IF : 4.176 | IC Value : 78.46

INTERNATIONAL JOURNAL OF SCIENTIFIC RESEARCH

PAINLESS ULCER ON FINGER TIP AS THE PRESENTING COMPLAINT OF CARPAL TUNNEL SYNDROME: A RARE MANIFESTATION OF A COMMON DISEASE

Orthopaedics

Nithin M Junior Resident, Department of Orthopaedics, Baby Memorial Hospital, Calicut.

N J Mani Head of Department, Department of Orthopaedics, Baby Memorial Hospital, Calicut.

ABSTRACT

Carpal Tunnel Syndrome being the most common entrapment neuropathy is easily diagnosed in orthopaedic opd. Painless ulcer on finger tip associated with CTS is very rare and only few cases have been reported in literature. But painless ulcer as the first presenting complaint is seldom seen. We present a 53 year old diabetic female with non healing ulcer on right middle finger tip which was initially diagnosed to be trophic ulcer due to peripheral neuropathy, but later found to be ulcerative variant of carpal tunnel syndrome Our case stresses the need to be aware of this rare presentation of a very common disease to prevent the progressive changes of skin lesions leading to resorption of distal phalanges ending up in autoamputation.

KEYWORDS

Carpal Tunnel Syndrome, Digital Ulcer, Autoamputation

INTRODUCTION

The mutilating and ulcerative variant of cts was first described by Bouvier et al in 1979[1].The skin involvement in cts occurs with severe damage of autonomic fibres of median nerve along with motor and sensory fibres. It is characterised by sclerodactyly ulcerative skin lesions and acroosteolysis[2,3] as well as nail changes like onychodystrophy[4] in sensory zones of median nerve. We report a case of 53 year old lady with chronic non healing ulcer on the right middle finger tip as her presenting complaint that eventually was diagnosed as severe bilateral cts. Only one case has been reported with digital ulcers as the first manifestation of carpal tunnel syndrome [5]

CASE REPORT

A 53 year old woman presented to orthopaedic opd with non healing ulcer over the right middle finger tip which initially started as a blister one year back. She had no history of diabetes mellitus, hypothyroidism and any systemic inflammatory diseases. The patient had no history of recurrent cervicobrachialgia.There is no history of cyanosis or redness at the finger tips on exposure to cold .Physical examination revealed hypoaesthesia in right median nerve area and atrophy of thenar muscles[Fig 1]. Sclerodactyly,onycholysis were noted on right index and middle fingers.A 0.5*0.5 cm ulcer with red granulation tissue was seen on the volar aspect of right middle finger tip which was non tender[Fig 2].Hand Grip strength was abnormal due to decreased thumb opposition power.Radiological examination showed no signs of acroosteolysis.



Fig 1 Picture showing severe thenar atrophy and ulcer on right middle finger tip

MRI cervical spine showed no abnormalities Electrophysiological studies revealed severe bilateral median nerve compression at carpal tunnel.An MRI of right hand was done to assess the median nerve thickness and other anatomical abnormalities if any. Open Carpal tunnel release with extended incision and Calmitz procedure(transfer of Palmaris longus to abductor pollicis brevis insertion) was done for the right hand to regain opposition of thumb.The ulcer was left alone as spontaneous resolution is common after carpal tunnel release.

DISCUSSION

CTS usually presents with triad of nocturnal pain hypoaesthesia and thenar atrophy.Skin involvement is detected in almost 20% cases with severe cts [6].They include skin atrophy anhidrosis nail changes like onychodystrophy hyperkeratosis of cuticle and brownish discolouration of nails. Raynauds Phenomenon and skin ulceration has also been reported.These signs are due to damage of sensory fibres and autonomic nerve fibres of median nerve in severe cases. If median nerve compression is unattended and progressive it may lead to ulcerative lesions sclerodactyly, acroosteolysis purulent inflammation and even autoamputation may occur. The ulcerative and mutilating clinical variant of CTS is very rare with only 25 reported cases in literature.

It is more common in males in the sixth decade and is bilateral in 25% [7].The mechanical and other forms of trauma like thermal injuries in cigarette smokers play important role in skin lesion formation[4].The volar aspect of distal phalanx of second and third fingers are the most commonly involved sites.These fingers are affected most because the innervations of fingers is mixed originating from both median and radial nerve fibres and because they are more vulnerable to external injury.

The decreased sensation contributes to the genesis of skin involvement allowing increased chances of physical or thermal trauma due to increased thermoalgesic threshold.Anhidrosis and impaired vascularization due to autonomic disturbances and sudomotor and vasomotor changes causing edema swelling of fingers skin colour changes fibrosis sclerodactyly and nail changes.These also lead to bacterial infection, purulent inflammation and autoamputation. Resorption of distal phalanges denoted by the term acroosteolysis is usually secondary to vascular occlusion.Carpal tunnel release has been success in 60% cases associated with ulcerative skin lesions according to reports.Sensory improvement is good in 75%-93% after cts release. The autonomic disturbances also improve after surgical decompression. It can be evaluated by water immersion wrinkling test which assess the vasoconstriction mediated by autonomic fibres[8].If symptoms don't resolve a systemic inflammatory disease should be suspected. Hence carpal tunnel release is highly rewarding in this context.

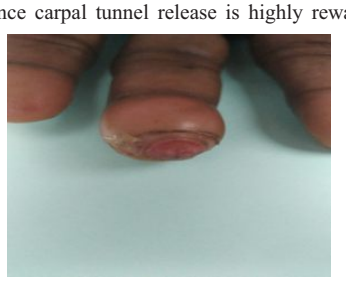

Fig 2 Fingertip showing chronic non healing ulcer

CONCLUSION:

High index of suspicion and early diagnosis can prevent motor end plate dysfunction, irreversible, bonelesions and autoamputation of digits.

REFERENCES:

[1] Bouvier M, Lejeune E, Rouillat M, Marionnet J (1979) Les forms ulcero-multilantes du syndrome du canal carpien. Rev Rhum Mal Osteoartic 46:169–176
[2] Aratari E, Regesta G, Rebora A (1984) Carpal tunnel syndrome appearing with prominent skin symptoms. Arch Dermatol 120:517–519
[3] Cox NH, Large DM, Paterson WD (1992) Blisters, ulceration and autonomic neuropathy in carpal tunnel syndrome. Br J Dermatol 126:611–613
[4] Fritz TM, Burg G, Böni R (2000) Carpal tunnel syndrome with ulcerous skin lesions. Dermatology 201:165–167
[5] Perdan-Pirkmajer K1, Praprotnik S, Tomšič M. Rheumatol Int. 2011 May;31(5):685-6
[6] 1. Aratari A, Regesta R, Rebora A (1984) Carpal tunnel syndrome appearing with prominent skin symptoms. Arch Dermatol 120:517–517
[7] Romani J, Puig L, de Miguel G, de Morages JM (1997) Carpal tunnel syndrome presenting as sclerodactylia, nail dystrophy and acro-osteolysis in a 60-year-old woman. Dermatology 95:159–161
[8] Wilder-Smith EPV, Chow A (2003) Water-immersion wrinkling is due to vasoconstriction. Muscle Nerve 27: 307–311