Volume : 4 | Issue : 7 | July 2015 • ISSN No 2277 - 8179

Research Paper

Medical Science

KEYWORDS : Parotid Gland Tumours -Benign , Malignant, FNAC

Parotid Tumours: A Cytohistopathological Correlation of 36 Cases In Khammam

Mahendranath P — Dept of Pathology , A.C.S Medical college.chennai-77

Vijay Kumar K — Dept of Pharmacology, A.C.S Medical college.chennai-77

ABSTRACT

OBJECTIVE: To evaluate the correlation of cytological findings with histopathological findings in parotid gland tumours.

MATERIALS AND METHODS: Prospective analytical study of 36 patients with parotid gland tumours subjected to fine needle aspiration and surgical excision during the period of January 2007 to August 2008.

RESULTS : Positive histological results occurred in 32 cases(88.8%) and negative correlation occurred in 4 cases(11.2%) with sensitivity for benign tumours being 96.6% and 50% for malignant tumours.

CONCLUSION :Despite the limitations offine needle aspiration in parotid gland tumours, it is an effective method in evaluating and therapeutic planning with safe and negligible complications.

INTRODUCTION

The technique of Aspiration puncture with fine needle(APFN) was initially used to investigate injuries in salivary gland in 1920[1,2] with improvement and development in 1950 and 1960 and popularization in the seventies[3,4]. It is a minimally invasive diagnostic examination and of low cost[5,6] used in neoplasia and non neoplasia injuries and being able to differentiate between benign or malignant neoplasia injury[7].

The APFN presents considerable advantages in diagnosis in relation to radiological findings and physical examination [8,9] as well as in relation surgical conventional biopsies [10] being that this procedure not always can be discharged [11].

Haemorrhages , haematomas, neoplasia dissemination and injury to the facial nerve are possible complications[12].

MATERIALS AND METHODS

Present study is a prospective analytical study of 36 parotid tumours during the period of January 2007 to august 2008, cytological and histopathological correlation of these cases were done at department of pathology, Mamata Medical College/Mamata general hospital, khammam. All patients referred to fine needle aspiration of Parotid gland tumours and where, Histopathological study was available are included in the study. After obtaining the clinical data and nothing the dimensions of the swelling and after explaining the procedure to the patients, under aseptic precautions, aspiration was done with 23g needle connected to a 5 ml or a 10 ml disposable plastic syringe. About two to four smears were prepared in each case. Some of the smears were fixed in 95 % ethyl alcohol and few were air dried. The air dried smears were stained by May GrunwaldGiemsa stain when possible and alcohol fixed smears were stained with H & E. Excision of the tumour was done at the discretion of the surgeon. Excised biopsy specimens were fixed in 10% formalin, thin sections were given from the tumour area and were processed by the routine procedure to obtain the paraffin sections that were stained with H&E. Subsequently Histopathological study was done and results were compared with the cytological diagnosis.

RESULTS

Among the sex wise distribution of 36 cases of parotid tumours, 21 cases (58.33%) occurred in females and 15 cases (41.67%)in males. Male to female ratio is 1.4:1The youngest patient presenting with a benign tumour of the parotid was 16 years old and the oldest was 70 years with a mean age of 43 years.

The youngest patient presenting with a malignant tumour was 40years and the oldest was 61 years with a mean age of 50.5 years.

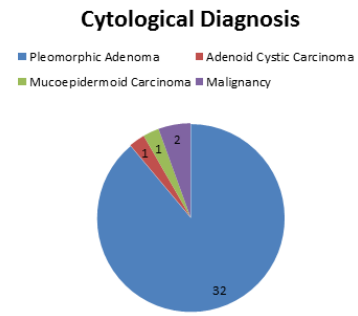

Among total of 36 cases of cytology samples, 32 were diagnosed as pleomorphic adenoma,1 case as mucoepidermoid carcinoma,1 case of adenoid cystic carcinoma and 2 cases were given as suggestive of malignancy

TABLE –1 Distribution of Parotid tumours in histopathology.

Sl.No	Tumours	No.of .cases	%
1	Pleomorphic adenoma	30	83.3
2	Adenoid cystic carcinoma	4	11.1
3	Mucoepidermoid carcinoma	1	2.8
4	Carcinoma ex Pleomorphic adenoma	1	2.8
Total		36	100

Of total 36 cases in the present study 30 cases (83.3%) were found to be Pleomorphic adenomas,4 cases were (11.4%) were adenoid cystic carcinomas,1 case (2.8%) was mucoepidermoid carcinoma and 1 case (2.8%) was carcinoma ex Pleomorphic adenoma

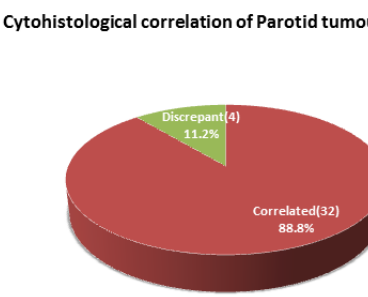

Volume : 4 | Issue : 7 | July 2015 • ISSN No 2277 - 8179

Among the total of 36 cases of cytopathology samples that were compared with histopathology 4 cases were discrepant and 32 cases correlated.

Of total 36 cases in the present study 30 were diagnosed as benign and 6 malignant on histopathology. Whereas 32 cases were diagnosed as benign and 4 as malignant in cytology.

TABLE – 2
Table showing Cyto- histologically correlated cases of Parotid tumours

Histopathological Diagnosis	No. Of. Cases with %
Benign	29 (90.7%)
Malignant	3 (9.3%)
Total	32

Of total 36 cases in the present study 32 cases correlated out of which 29 cases (90.7%) were benign and 3 cases(9.3%) were malignant.

Of 36 cases in the present study 32 cases correlated out of which 29 cases (90.7%) were Pleomorphic adenoma s,1 case (3.1%) of Mucoepidermoid carcinoma, 1 case (3.1%) of Adenoid cystic carcinoma and 1 case (3.1%) of carcinoma ex pleomormphic adenoma.

TABLE -3
Table summarizes the cytological and histological results of 36 cases included in the study.
HISTOPATHOLOGICAL DIAGNOSIS

Cytological diagnosis	Pleomorphic adenoma	Mucoepidermoid carcinoma	Adenoid cystic carcinoma	Carcinoma ex pleomorphic adenoma
Pleomorphic adenoma (32)	29	--	3	--
Mucoepidermoid carcinoma (1)	--	1	--	--
Adenoid cystic carcinoma (1)	1	--	--	--
Malignancy (2)			1	1
TOTAL	30	1	4	1

Of total no. Of 36 cases included in the present study, 32 cases were diagnosed as Pleomorphic adenoma by cytology of which 29 cases were Pleomorphic adenoma and 3 cases were Adenoid cystic carcinoma on histopathology. A single case diagnosed as Mucoepidermoid carcinoma correlated with histopathology. The single case diagnosed as Adenoid cystic carcinoma on cytology was found to be Pleomorphic adenoma on histopathology. Of the two cases which were reported as suggestive of malignancy, 1 case turned out to be Adenoid cystic carcinoma and the other Carcinoma ex- Pleomorphic adenoma on subsequent histopathology.

DISCUSSION

The general incidence of salivary gland tumours was about 3- 6% of all head and neck tumours and Parotid gland tumours account for 65% of these. About 80% of these are benign tumours and Pleomorphic adenoma is the commonest , accounting for 55% of all parotid tumours and 80% of benign tumours (memorial sloan kettering cancer center, New York Data).

The present study exhibited an incidence of 83.3% of benign tumours and 16.7% were malignant with Pleomorphic adenoma accounting for 100%. According to meorialsloan Kettering cancer center statistics 75% benign and 25% were malignant. According to present study 83.3% were benign and 16.7% were malignant.

TABLE- 4
The distribution of various tumours in comparison with Spiro series and Khalid series.

Type of tumour	Percentage in present series	Spiro series[13]	Khalid series[14]
Pleomorphic adenoma	83.3%	45.4%	66.67%
Adenoid cystic carcinoma	11.1%	10%	-
Mucoepidermoid carcinoma	2.8%	15.7%	11.1%
Carcinoma ex pleomorphic adenoma	2.8%	5.7%	-

According to the present study, Pleomorphic adenoma accounted for 83.3%, Adenoid cystic carcinoma for 11.1%, Mucoepidermoid carcinoma and Carcinoma ex pleomorphic adenoma for 2.8%. In Spiro series[13] Pleomorphic adenoma accounted for 45.4%, Adenoid cystic carcinoma for 10%, Mucoepidermoid carcinoma for 15.7% and Carcinoma ex pleomorphic adenoma for 5.7%.In khalid series[14]Pleomorphic adenoma accounted for 66.67% and Mucoepidermoid carcinoma for11.1%.

According to present study 21 cases (58.33%) were females and 15 cases (41.67%) were males with a male female ratio 1.4:1.

Among the benign tumours of the parotid the youngest was 16yrs and the oldest was 70yrs with a mean age of 43yrs.Among the malignant tumours of parotid in the present study, the youngest was 40yrs and the oldest was 61yrs with a mean age of 50.5yrs.

The highest incidence of benign tumours was in the age group of 21-30yrs and for the malignant tumours age group was 31-50 yrs.

Of the 36 cases in the present study 30 were diagnosed as benign and 6 as malignant on histopathology whereas 32 cases were diagnosed as benign and 4 as malignant on cytology.

.According to the present study ,the youngest patient was 16yrs of age while the oldest was 70yrs of age. The great majority of the patients were in 21- 40yrs of age group.

According to the present study of 36 cases, only 6 cases were found to be malignant of which adenoid cystic carcinomas were 4 cases(66.6%) of all malignant tumours. Mucoepidermoid carcinoma 1 cases (16.7%) and carcinoma ex pleomorphic adenoma 1 case(16.7%).

In the present study of 36 cases, 32 cases were diagnosed as benign on cytology, of which only 29 cases were benign i.e 3 cases were reported as false positive.

Incidence of malignancy on histopathology was 6 cases where as only 4 cases were diagnosed as malignant on cytology ,of which 3 cases were true positive and 1 was false positive.

Sensitivity of F.N.A.C for benign lesion was 96.66%, whereas sensitivity for malignant lesions was 50%.

TABLE -5
Table showing comparative studies of sensitivity of F.N.A.C of Parotid tumours

	Present study	J.P.Shah Janet et al(16)	Jayaram Verma et al(17)	Deans briggs et al(18)	iffaretti et al(19)
Sensitivity for benign tumours	96.66%	95%	100%	88%	89.7%
Sensitivity for malignant tumours	50%	65%	87%	66%	-

CONCLUSION

Despite the limitations of Fine needle aspiration cytology, it is economical and safe with negligible complication. Negative for malignancy on cytology does not rule out malignancy with only 50% of sensitivity for malignant tumours and overlapping cyto-morphological features were found to be the most frequent cause of diagnostic errors on cytology.

REFERENCE

1. Martin HE, Ellis EB. Biopsy by needle puncture and aspiration. Ann Surg 1930; 62:169-181. | | 2. Dudgeon LS, Patrick CV. A new method for rapid microscopical diagnosis of tumors. Br J Surg 1927; 15:250-261. | | 3. Mavec P, Eneroth CM, Franzen S, Moberger G, ZajicekJ.Aspiration biopsy of salivary gland tumors. ActaOtolaryngol (Stockh) 1964; 58:471-484. | | 4. Bonneau H, Sommer D. L'orientation du diagnostic des tumeurssalivairespar la ponction à l'aiguille fine. PatholBiol 1959; 7:786-791. | | 5. Frable MA, Frable WJ. Fine needle aspiration biopsy of salivary glands. Laryngoscope 1991; 101(3):245-9. | | 6. Layfield LJ, Glasgow BJ. Diagnosis of salivary gland tumors by fine needle aspiration cytology: a review of clinical utility and pitfalls. DiagCytopathol 1991; 7(3):267-72 | | 7. Atula T, Grenman R, Laippala P, Klemi P. Fine-needle aspiration biopsy in the diagnosis of parotid gland lesions: evaluation of 438 biopsies. Diagnostic Cytopathology 1996; 15:185-190. | | 8. Zurrida S, Alasio L, Tradati N, Bartoli C, Pilotti S. Fineneedle aspiration of parotid masses. Cancer 1993; 72:2306- 2311. | | 9. Owen E E R T C, Banerjee A K, Prichard A J N, Kark A E. Role of fine-needle aspiration cytology and computed tomography in the diagnosis of parotid swellings. Br J Surg 1989; 76:1273-1274. | | 10. Biaforetti G, Giannoni M, Ranieri A, Leocata P. Fine needle aspiration cytologic diagnosis of swellings in the parotid and submandibular regions. Cytologic-histologic correlations in 49 cases. Minerva Stomatol 1996; 45(1-2):9-16 | | 11. Batsakis J G, Sueige N, el Nagar A K. Fine-needle aspiration of salivary glands:its utility and tissue effects. Ann OtolRhinolLaryngol 1992; 101:185-188. | | 12. Cramer h, Layfield L, Lampe H. Fine-needle aspiration of salivary glands: its utility and tissue effects. Ann OtolRhinolLaryngol 1993; 102(6):483-5. | | 13. Spiro RH et al: Mucoepidermoid carcinoma of salivary gland origin – A clinico-pathological study of 367 cases: am. .j. surg, 136:301,1978. | 14. KHALID AHSAN MALIK ,Parotid tumours: A six years' experience, Pakistan journal of surgery ;Vol.23, Issue 2,2007. | 15. 15.Nitin M.Nagarkar et al Salivary Gland tumours. Our experience. Indian journal of Otolaryngology and Head and neck surgery Vol.56, No.1,jan- mar,2004. | 16.JatinP.Shah,, janet K.IHDE: Current problems in surgery – salivary gland tumours , Dec.1990. | 17.Jayaram G, Verma AK (Moulana Azad Medical College ,New Delhi):Fine needle aspiration of salivary gland tumours – J. Oral Path Med : 1994 July 23(6):256 – 61 | 18.Deans G.T. Briggs K , et al : An audit of surgery of the Parotid Gland – Ann.RoyColl Engl. 1995 May 77(3):188- 92. | 19.BifarettiG,Gionnoni M, Ranieri A : Fine needle aspiration in the cytologic diagnosis of wellings in the Parotid and submandibular regions - Cytopathologic correlation in 49 cases-Minerva stomatol 1996 Jan- Feb;45 (1-2): 9-16. |