Research Paper

Volume : 5 | Issue : 4 | April 2016 • ISSN No 2277 - 8179 | IF : 3.508 | IC Value : 69.48

Percutaneous Triple Release For The Management of Moderate Idiopathic Clubfoot

Medical Science

KEYWORDS : idiopathic Clubfoot, Percutaneous release, Ponseti

Dr. Manish Singh Rajpoot	Senior Resident, Department of Orthopaedics, N.S.C.B. Medical College, Jabalpur, M.P.
Dr. H.S. Varma	Professor, Department of Orthopaedics, N.S.C.B. Medical College, Jabalpur, M.P.
Dr. Digember Peepra	Assistant Professor, Department of Orthopaedics, N.S.C.B. Medical College, Jabalpur, M.P.
Dr. Krishna Kumar Pandey	Associate Professor, Department of Orthopaedics, N.S.C.B. Medical College, Jabalpur, M.P.

ABSTRACT

Background:- Idiopathic clubfoot can be managed by the technique described by Ponseti in infants which require a lot of passion and compliance of the patients. On the other hand, described surgery for congenital clubfoot has its complications. We used a different midway technique of percutaneous triple release for the management of moderate clubfoot.
Material and methods:- In 22 children(12 unilateral and 10 bilateral), total 32 clubfoot were there with moderate type of deformity, were treated with this procedure. Assessment of results was done by comparing preoperative and 3 weeks postoperative Pirani scores.
Results and Conclusion:- Our results were excellent in 12.5% cases, good in 87.5% and fair in 12.5 % cases. None of our cases had any intra-op and post-op complication. This triple releases technique is a simple and having easy learning curve by which we can treat moderate type of clubfoot in less time and cost with good to excellent outcome.

Introduction:- Idiopathic clubfoot can be managed by the technique described by Ponseti in infants[1] which has been shown to be very effective[2] but requires a lot of passion and compliance of the patients. On the other hand, described surgery for congenital clubfoot has number of complications in the post operative period such as delayed wound healing, gaping, infection and recurrence of the deformity. In subtropical countries, healing gets invariably delayed if the surgical wound gets infected or there is wound dehiscence. Maintaining the foot in corrected position in plaster cast along with a window for dressing in a hot and humid climate makes the task more difficult due to soiling of the cast leading to breakage and further infection.

We have used a different midway technique for the management of moderate clubfoot. In our technique, we used percutaneous release for three structures i.e. planter fascia, tendoachilles(TA) and flexor hallucis longus(FHL). Tendons appear to reunite clinically and functionally within 3 weeks and the deformity of the feet get corrected nicely.

Material and methods:- There were total 23 children treated with triple release technique out of which one child was lost in follow up. Remaining 22 children of age group 1m-1yr (av age 4 m) were registered for the treatment. A short history with clinical examination of spine and foot was done. Male= 16, female= 6, bilateral foot involvement in 10 patients. All these feet had moderate type of deformity as assessed by Pirani scoring system[3]. A foot with a Pirani score as modified by Flynm et al,[4] less than 2.5 and which got corrected with Ponseti weekly casting was considered as mild. A foot was considered to be having moderate deformity when the foot had a Pirani score between 2.5 and 5. These feet did not get corrected fully with weekly Ponseti's casting or recurred in a few weeks time due to poor parent compliance, ignorance, illiteracy, or low socioeconomic status[5]. A foot was said to be having severe deformity if the Pirani score was more than 5. Moderate clubfoot can be treated with this procedure at the time of presentation (mid foot score should be < or = 2). If clubfoot is severe convert it into moderate type by serial casting then do the percuteneous triple release. Syndromic, Rigid feet, neglected CTEV with bony deformity and candidates with secondary clubfoot were not considered to be fit for this procedure. Only the idiopathic congenital clubfoot of moderate variety were taken for the study.

Procedure: The surgery was done under short GA with patient in supine position. Knee kept extended and foot in dorsiflexion as much as possible so that the ligament become taught. With the help of no. 11 blade directly reach up to the planter fascia origin and release it for the correction of cavus, as in Steindler technique[6] (fig-2) then percutaneous tendoachillles released by multiple partial three level tenotomy was done and then foot was dorsiflexed to correct equinus (fig-3). After that great toe was assessed in full dorsiflexon of foot and if it was found to be tight then percuteneus release of the flexor hallucis longus was done at the midpoint of proximal crease of great toe at metatarso-phalangial joint, described by Mittal et al[8]. Correction was assessed on the table with regard to cavus and equinus. If necessary two smooth 2mm k-wire were inserted to maintain the equines and forefoot adduction, as in Turco's method[7]. Deformity always be corrected in a sequence, first planter fascia then-Tendoachilles then FHL. Correction was maintained by applying above knee CTEV cast from toe to groin for 3 weeks in over corrected position. After 3 weeks cast was removed and CTEV splint applied. In a case, where K-wires were used, that K-wires were removed and cast was applied for 3 more weeks.

Results:- In our study, there were 22 children (average age 4 month) having deformity in 32 feet which were treated by triple release technique. Deformity was assessed preoperative and 3 weeks postoperatively by Pirani's scoring system[3] and was compared and analysed. On comparing preop and postop groups Pirani score, we observed a positive linear trend and achieved significant reduction of deformity toward poorer scores (p value < .001) with in short duration of time (Graph-1). It was found that we had excellent result in 4 feet (as seen by postoperative Pirani score below 0.5), good in 24 feet (postoperative Pirani's score < 1.5) and fair result in 4 feet (postoperative Pirani's score ≤ 2). Insignificant clawing of remaining four toes was there in some cases which were managed by manual stretching later-on. None of the patients had post-operative complication and failure of

treatment.

Discussion:- Ponseti's technique is the worldwide accepted technique for the treatment of clubfoot[1] but requires a lot of time and passion, it requires repeated casting which further increase the cost of treatment. This is difficult situation for the parents to expect the child will have normal foot, at a time they prefer to accept deformity rather than come repeatedly due to poverty and illiteracy. On the other hand, soft tissue surgery has its complications and hazards. In our study, we used a mid-path technique which is actually a combination of three percutaneous release namely planter fascia for cavus[6], Tendoachilles for equinus[1] and flexor hallucis longus for great toe clawing[8]. By this technique, out of 32 feet, 4(12.5%) had excellent result and remaining 28(87.5%) feet had good to fair results.

Thus we suggest this triple release technique, for the correction of moderate type of clubfoot, which is simple and easy to learn with good to excellent outcome. Further follow-up to 2 yrs is required.

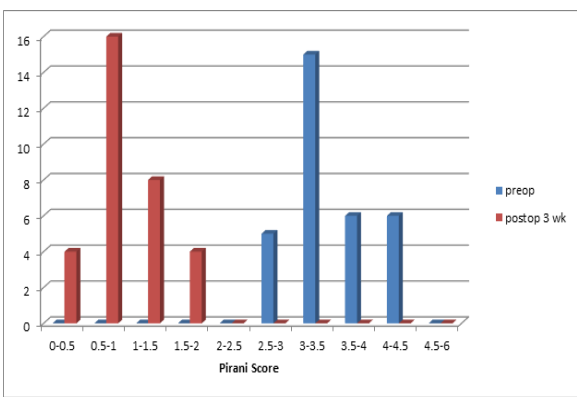

Graph-1:-Graph shows shifting of feet toward poorer Pirani score

Fig-1: Preop



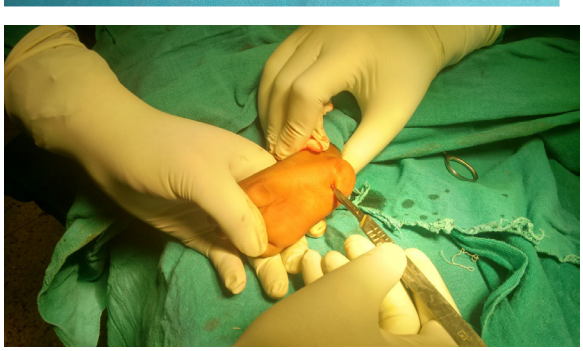

Fig-2 :- Planter fascia release

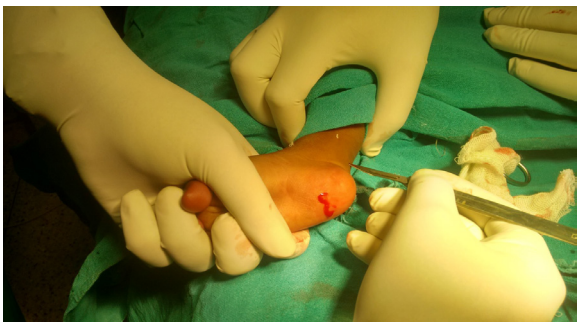

Fig-3:- Tendoachilles release



Fig-4:- Flexor hallucis release



Fig-5:- Full correction achieved by triple release



Fig-6:- Bilateral clubfoot treated with triple release after 3 weeks in 6 month old infant

Refrences:-

1. Ponseti IV. Congenital clubfoot: fundamentals of treatment. New York: Oxford University Press; 1996. p. 140.
2. Colburn M, Williams M, Colburn M, Williams M. Evaluation of the treatment of idiopathic clubfoot by using the Ponseti method. *J Foot Ankle Surg* 2003;42:259-67.
3. Pirani S, Outerbridge HK, Sawatzky B et al (1999) A reliable method of clinically evaluating a virgin clubfoot evaluation.

Volume : 5 | Issue : 4 | April 2016 • ISSN No 2277 - 8179 | IF : 3.508 | IC Value : 69.48

4. Flynn JM, Donohoe M. Mackenzie WG. An independent assessment of two clubfoot-classification systems. J Pediatr Orthop 1998;18:323-7.
5. Crawford AH, Gupta AK. Clubfoot controversies: Complications and causes for failure. Instr Course Lect 1996;45:339-46.
6. Steindler A, The treatment of pes cavus (hollow claw foot). Archives of Surgery. 1921; 2:325-337.
7. Turco VJ. Surgical correction of resistant clubfoot. One-stage posteromedial release with internal fixation: A preliminary report. J Bone Joint Surg 1971;53:477-97.
8. Aggarwal ND, Singh HS, Mittal RL. Evaluation of tibialis posterior transfer on surgical treatment of congenital clubfoot. IJS 1967;29:4-105.