ORIGINAL RESEARCH PAPER

Volume-7 | Issue-2 | February-2018 | PRINT ISSN No 2277 - 8179

INTERNATIONAL JOURNAL OF SCIENTIFIC RESEARCH

# PERIBULBAR BLOCK: OBSERVATIONAL STUDY

Ophthalmology

**Dr. Jitendra Kumar** Associate Professor & Head, Dept. of Ophthalmology, MLB Medical College Jhansi, India.

**Dr. Kanhaiya Prasad*** Junior Resident, Dept. of Ophthalmology, MLB Medical College Jhansi, India. *Corresponding Author

## ABSTRACT

Ophthalmic surgery has been performed under a wide range of anaesthetic techniques as like peribulbar, retrobulbar, Sub-tenon, topical anaethesia, intracameral etc. In Peribulbar block, the anaesthetic is injected into the extraconal compartment of the eye. Thus, most of the complications associated with retrobulbar anaesthesia are avoided. The main aims of study were- A) to evaluate the various complications of peribulbar block. B) Effect of the size of needle in peribulbar block. C) Various factors that cause complications in peribulbar block. A total of 850 Patients with peribulbar block, were included in this observational study conducted in the Department of Ophthalmology, MLBMC, Jhansi, over a period of 12 months. The preoperative assessment done and detailed clinical history was taken.After 15-20 min of peribulbar block patient were kept under observation and all cases undergone for routine ophthalmological examination like torch light examination, slit lamp examination. All cases were divided into two groups -Group A- Peribulbar block with 24 gauge needle. (NA=450), Group B- Peribulbar block with 26 gauge needle. (NB=400). The common complications were conjunctival chemosis (23.06%), periorbital edema (14.71%), Lid hemorrhage (5.53%), retrobulbar hemorrhage (1.05%), globe perforation (0.12%), and mayotoxicity (0.24%). The incidence of complications were depends on many factors like size of needle, experience hands, patient's cooperation, past history of patient's, amount of block solution etc. So, proper anatomical knowledge, preoperative assessment, proper examination, counseling of the patients play significant role to avoid these complications.

## KEYWORDS

Conjunctival chemosis, Mayotoxicity, Peribulbar block, Periorbital edema, Retrobulbar hemorrhage

### Introduction

Ophthalmic surgery has been performed under a wide range of anaesthetic techniques. The type of anaesthesia for each ophthalmic surgery depends on a large number of factors like patient co-operation, the nature of the surgery and surgeon's preference. Over the years, ocular anaesthesia has evolved tremendously, with topical anaesthesia making a comeback in the last few years. Eye surgeries had been performed with little or no anaesthesia for almost 1000 years. The "Year 1884" was a watershed year for ophthalmic anaesthesia; it was in this year that Carl Koller discovered cocaine hydrochloride as a topical anaesthetic agent for performing eye surgery and Herman Knapp used cocaine for retrobulbar injection and performed enucleation. Various local anesthetic techniques have evolved since then including both akinetic (needle-/ cannula-based technique)[1,2] and non-akinetic (topical anaesthesia) techniques.[3]

### Classification of anaesthetic technique in ophthalmic surgery:

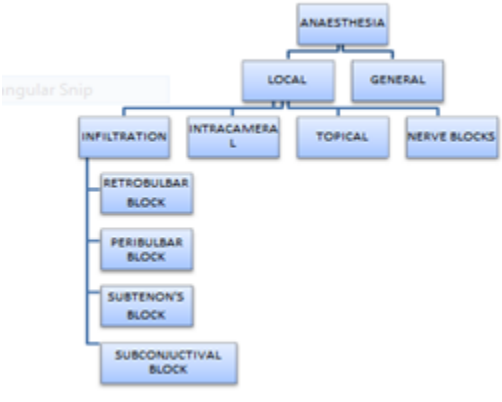


### Objectives of anaesthesia in intraocular surgery:

| | |
|---|---|
| • Akinesia of globe and lids<br>• Anaesthesia of globe and lids and adnexa<br>• Control of intraocular pressure<br>• Control of systemic blood pressure | • Relaxation of patient<br>• Absence of untoward<br>• reactions<br>• Smooth emergence<br>• Adequate post-operative analgesia |

**Peribulbar block:** In 1985, Davis & Mandel reported the use of peribulbar anesthesia. Kelman was known to have first performed this technique (unpublished) in 1970. In this procedure, the anaesthetic is injected into the extraconal compartment of the eye. Thus, most of the complications associated with retrobulbar anaesthesia are avoided.

*Technique of peribulbar block:*

5 ml bupivacaine 0.75% and 5 ml lignocaine 2% with 1:200000 adrenaline and 150 units of hyaluronidase (mixed to aid diffusion within the orbital tissue) are drawn into a 10 ml syringe. Superior & inferior injections of 5 ml each are given with a 3/4 inch, 24-26G needle. Inferior injection is given at the junction of the outer one third & inner two third of the lower orbital rim. Superior injection is given usually nasally just above the medial canthus. The superior injection may be avoided till the time the inferior injection takes effect (3-5 min), to judge the necessity for the additional injection. If good akinesia is attained by the inferior injection, there is no need for the superior injection. Gently press on the lower lid between the orbital margin and the globe to feel the inferior orbital notch and with the other hand progressively inject 5 ml of anesthetic solution starting just under the skin, progressively to just behind the equator of the globe. 1 ml is injected in the lid, about 2-3 ml in the region of the equator & 1-2 ml just posterior. The same procedure may be repeated for the upper injection if required. Fullness of the upper lid points to an increase in the orbital volume and correct site of injection. 10-20 minutes of intermittent ocular compression is applied after the injection.

### Components of peribulbar anaesthetic solution:

***Lignocaine 2%*** is the most popular agent for nerve blocks. It has a rapid onset of action and its effect will usually last for an hour.

***Bupivacaine 0.5%*** lasts for three hours or even longer; this anaesthetic can be useful for prolonged procedures such as vitreoretinal surgery.

***Hyaluronidase*** may increase the effectiveness of a block by facilitating the spread of lignocaine or bupivacaine through the tissues. Hyaluronidase can be used in a concentration of approximately 50 units/ml (range: 25 to 75 ml).

***Adrenaline*** slows the absorption of anaesthetic agents into the systemic circulation. This will provide a longer duration of action and reduce the risk of systemic toxic effects. It is used in a concentration of 1:100,000.

**Assessment and Preparation:** The preoperative assessment should always include a specific enquiry about bleeding disorders and related drugs. There is an increased risk of haemorrhage and this requires that

a clotting profile is available (and recorded) prior to injection. Patients receiving anticoagulants are advised to continue their medication.[4] Clotting results should be within the recommended therapeutic range.[4,5] Currently there is no recommendation for patients receiving antiplatelet agents.[5] Procedures under topical, subconjunctival, sub Tenon's or shallow peribulbar blocks are recommended.There are a number of risk factors that predispose the globe to needle penetration. The presence of a long eye, staphyloma or enophthalmos, faulty technique, a lack of appreciation of risk factors, an uncooperative patient and the use of unnecessarily long needles are some of the contributing causes.[6] Patients presenting with axial myopia have greater risk of globe puncture compared with patients with normal axial length. A precise axial length measurement is usually available for intraocular lens dioptre power calculation before cataract surgery. If the block is performed for other surgery and the axial length measurement is not known, close attention to the dioptre power of patients spectacles or contact lenses may provide valuable clues to globe dimension. In the presence of high myopia, a classical peribulbar block [7] or a single medial peribulbar injection is advocated.[8] Similar caution will apply where there is a pre-existing scleral buckle from an earlier retinal operative procedure.[7] Once the decision is made to operate, the anaesthetic and surgical procedures are explained to the patients to enable informed consent. All monitoring and anaesthetic equipment in the operating environments should be fully functional. [9] Blood pressure, oxygen saturation and ECG leads are connected and baseline recordings are obtained. Although the insertion of an intravenous line has been questioned for topical or sub-Tenon's injections, [10]an intravenous line must be inserted before embarking on a needle block.[9] The presence of a secure intravenous line remains good clinical practice.[11]

## Method and material

A total of 850 Patients with peribulbar block, were included in this observational study conducted in the Department of Ophthalmology, Maharani Laxmi Bai Medical College, Jhansi, Uttar Pradesh, India over a period of 12 months from Jan. 2016 to Dec. 2017. The procedures followed were in accordance with the ethical standards committee on human experimentation (institutional or regional) and with the Helsinki Declaration of 1975, as revised in 2000. The necessary permission from the Ethical and Research Committee was obtained for the study.

### Inclusion criteria:

1. Patients with peribulbar block irrespective of type of ocular surgery except evisceration and enucleation.
2. Both male and female patients were included in the study.
3. The age group of the patients to be studied was above 15 years.

### Exclusion criteria:

1. Patients with hematological and allergic disorders were not included in the study.
2. Patients below the 15 years of age were excluded from the study.
3. Patients, who had history of drugs intake like anticoagulants and antiplatelete, were excluded from the study.
4. Patients with peribulbar block and planed for evisceration and enucleation, were excluded from the study.

The preoperative assessment done and detailed clinical history was taken (Including history of specific drug intake like anticoagulants and antipaletele). After 15-20 min of peribulbar block patient were kept under observation and all cases undergone for routine ophthalmological examination like torch light examination, slit lamp examination. Random blood sugar (RBS), $SpO_2$, B-scan, OCT, and NCT was done in special cases.

All cases divided into two groups

- Group A- Peribulbar block with 24 gauge needle. ($N_A$=450)
- Group B- Peribulbar block with 26 gauge needle. ($N_B$=400)

- **Results**

**Table-1: Sex wise patient's distribution in both test groups**

| | Group A | Group B | Total |
|---|---|---|---|
| Male | 240 | 235 | 475 |
| Female | 210 | 165 | 375 |

**Table-2: Various complications seen in peribulbar block**

| Various complication | Group A (450) | Percentage | Group B(400) | Percentage | Total (850) | Percentage |
|---|---|---|---|---|---|---|
| Conjunctival chemosis | 109 | 24.22% | 87 | 21.75% | 196 | 23.06% |
| Periorbital chemosis/ edema | 73 | 16.22% | 52 | 13.00% | 125 | 14.71% |
| Injection site bleeding/ Lid hemorrhage | 28 | 6.22% | 19 | 4.75% | 47 | 5.53% |
| Retrobulbar hemorrhages | 09 | 2.00% | Nil | 0% | 09 | 1.05% |
| Myotoxicity | 01 | 0.22% | 01 | 0.25% | 02 | 0.24% |
| Globe Penetration and Perforation | 01 | 0.22% | Nil | 0% | 01 | 0.12% |
| Brainstem Anesthesia | Nil | 0% | Nil | 0% | Nil | 0% |
| Optic Nerve Damage | Nil | 0% | Nil | 0% | Nil | 0% |
| Allergy | Nil | 0% | Nil | 0% | Nil | 0% |
| Oculocardiac reflex (OCR) | Nil | 0% | Nil | 0% | Nil | 0% |
| Complications of 7th nerve block | Nil | 0% | Nil | 0% | Nil | 0% |

## Discussion

With peribulbar block the local anesthetic is deposited within the orbit but not in the muscular cone. Widespread use of the phacoemulsi fication technique has changed anesthesia requirements in which total akinesia is no longer essential. The block consists of two injections: a superior injection above the medial canthus nasally and an inferior injection given at the junction of the outer one thirds and the inner two third of the inferior rim of the orbit. In this study many complications were noted with peribulbar block. These complications were depends on many factors like size of needle, experience hands, patient's cooperation, past history of patient's, amount of block solution etc .

In this study the male female ratio was 1.27:1, which was depends on admission of patients for surgery. The commonest noted minor complication of peribulbar block was conjunctival chemosis 23.06%. Conjunctival edema (chemosis) and subconjunctival hemorrhage (ecchymosis) [12] may occur after needle block. Peribulbar block is associated with frequent chemosis and subconjunctival hemorrhage than retrobulbar block, due to anterior spread of the local anesthetic agent and the damage of minor blood vessels with needle tip, respectively. Another common complication was Periorbital chemosis/ edema (14.71%). The account of lid hemorrhage in this study was 5.53 % which was very close to various other studies. [13] In this study the incidence of retrobulbar hemorrhage was 1.05% which was slightly increases due to un-experienced hands of anaestetics. In other study, the incidence of retrobulbar hemorrhage was only 0.03%. [14 ] An incidence ranging between 0.4% and 1.7% have also been reported.[15] The risk of developing retrobulbar hemorrhage is greater, when a long (> 38 mm) needle is advanced deep into the orbit where vascular structures are most tightly packed. Larger diameter needles are more likely to cause tear in a blood vessel. [16] Other risk factors suggested, are pre-existing vascular and hemorrhagic diseases. [17] In our study the chances of retrobulbar hemorrhage were greater with 24G needles as compared to 26G needles. The account of globe perforation in this study was 0.12%with 24G needles which was similar to other study (varies from 0% [18] to 0.1%. [19]). Patients with an axial length of ≥ 26 mm are prone to globe perforation. According to Duker *et al*,45% of globe perforations occurred in patients who had an axial length of ≥ 26 mm.

The incidence of Mayotoxicity in this study was 0.24%. Johnson et al, [20] identified postoperative strabismus in 0.18% of patients receiving retrobulbar blocks with a 38 mm needle.

In this study all these complications were more common with using 24G needle as compared to 26G needle for peribulbar block. Other complication like brain stem anaesthesia, oculocardiac reflex, allergy, 7th nerve block, and optic nerve damage were not found in this study.

## Conclusion

Peribulbar block is considered by many to be easier, safer, and less painful than retrobulbar block, because the muscle cone is not entered and the need for facial nerve block is eliminated. Because the anesthetic is deposited outside the muscle cone and then must diffuse to target areas, the potential for intraocular or intradural injection is minimized, and the potential for intraconal hemorrhage and direct nerve injury is essentially avoided. However, peribulbar block typically has a higher failure rate and a longer onset time than retrobulbar block, unless the onset is accelerated by adding sodium bicarbonate to the anesthetic mixture [21]. Additionally, the larger volume of anesthetic deposited in the orbit produces increased forward pressure on the eyeball, which some surgeons find objectionable. Reported complications have included peribulbar hemorrhage, conjunctival chemosis, injection site bleeding/ Lid hemorrhage, perforation of the globe and myotoxicity.

In this study the incidence of complications were depends on many factors like size of needle, experience hands, patient's cooperation, past history of patient's, amount of block solution etc. Before attempting to perform any regional orbital block, it is essential to learn the anatomy of orbital structures and the safe block technique. So, proper anatomical knowledge, preoperative assessment, proper examination, counseling of the patients play significant role to avoid these complications.

## References:


1. Davis DB II, Mandel MR: Posterior peribulbar anesthesia: An alternative to retrobulbar anesthesia. J Cataract Refract Surg 1986;12:182-4
2. Hansen EA, Mein CE, Mazzoli R. Ocular anesthesia for cataract surgery: A direct sub-Tenon's approach. Ophthalmic Surg 1990;21:696-9.
3. Assia EI, Pras E, Yehezkel M, Rotenstreich Y, Jager-Roshu S. Topical anesthesia using lidocaine gel for cataract surgery. J Cataract Refract Surg 1999;25:635-9.
4. Konstantatos A. Anticoagulation and cataract surgery: a review of the current literature. Anaesth Intensive Care 2001;29:11-8.
5. Katz J, Feldman MA, Bass EB, Lubomski LH, Tielsch JM, Petty BG, et al. Study of Medical Testing for Cataract Surgery Team. Risks and benefits of anticoagulant and antiplatelet medication use before cataract surgery. Ophthalmology 2003; 110: 1784-8. Erratum in: Ophthalmology 2003;110:2309.
6. Hamilton RC. Complications of ophthalmic anesthesia. Ophthalmol Clin North Am 1998;11:99-114.
7. Johnson RW, Forrest FC. Anaesthesia for ophthalmic surgery. In: Prys- Roberts C, Brown Jr BR, editors. International Practice of Anaesthesia.Oxford: Butterworths, 1996.
8. Vohra SB, Good PA. Altered globe dimensions of axial myopia as risk factors for penetrating ocular injury during peribulbar anaesthesia. BrJ Anaesth 2000;85:242-5.
9. Local Anaesthesia for Intraocular Surgery. UK: The Royal College of Anaesthetists and The Royal College of Ophthalmologists, 2001.
10. Mathew MR, Williams A, Esakowitz L, Webb LA, Murray SB, Bennett HG. Patient comfort during clear corneal phacoemulsification with sub-Tenon's local anesthesia. J Cataract Refract Surg 2003;29:1132-6.
11. Kumar CM, Dodds C, Faanning GL, editors. Ophthalmic Anaesthesia.The Netherlands: Swets and Zeitlinger, 2002.
12. Rubin A. Complications of local anaesthesia for ophthalmic surgery. Br J Anaesth 1995;75:93-6.
13. Kallio H, Paloheimo M, Maunuksela EL. Hemorrhage and risk factors associated with retrobulbar/peribulbar block: A prospective study in 1383 patients. Br J Anaesth 2000;85:708-11.
14. Katz J, Feldman MA, Bass EB, Lubomski LH, Tielsch JM, Petty BG, et al. Risks and benefits of anticoagulant and antiplatlet medication before cataract surgery. Ophthalmolology 2003;110:1784-8.
15. Cionni RJ, Osher RH. Retrobulbar hemorrhage. Ophthalmology 1991;98:1153-5.
16. Troll GF. Regional ophthalmic anesthesia: Safe technique and avoidance of complications. J Clin Anesth 1995;7:163-72.
17. Hamilton RC. A discourse on the complications of retrobulbar and peribulbar blockade. Can J Ophthalmol 2000;35:363-72.
18. Davis DB 2nd, Mandel MR. Posterior peribulbar anesthesia: An alternative to retrobulbar anesthesia. J Cataract Refract Surg 1986;12:182-4.
19. Ramsay RC, Knobloch W. Ocular perforation following retrobulbar anesthesia for retinal detachment surgery. Am J Ophthalmol 1978;86:61-4.
20. Johnson DA. Persistent vertical binocular diplopia after cataract surgery. Am J Ophthalmol 2001;132:831-5.
21. Zahl, K., Jordan, A., McGroarty, J., and Gotta, A. W. pH adjusted bupivacaine and hyaluronidase for peribulbar block. Anesthesiology 72:230-232, 1990.