Research Paper

Volume : 2 | Issue : 10 | October 2013 • ISSN No 2277 - 8179

Perio - Restorative Interface: A Review

Medical Science

KEYWORDS : biologic width, crown margins, crown contour

Dr. Amit Thareja	Assistant Professor, Dept of Prosthodontics, Bharati Vidyapeeth Deemed University Dental College & Hospital, Pune-43
Dr. Priyanka Agrawal	Assistant Professor, Dept of Periodontics , Bharati Vidyapeeth Deemed University Dental College & Hospital, Pune-43
Dr. Ajay Sabane	Associate Professor, Dept of Prosthodontics, Bharati Vidyapeeth Deemed University Dental College & Hospital, Pune-43
Dr. Rajashree Jadhav	Associate Professor, Dept of Prosthodontics, Bharati Vidyapeeth Deemed University Dental College & Hospital, Pune-43
Dr. Darshana Dalaya	Assistant Professor, Dept of Periodontics, Bharati Vidyapeeth Deemed University Dental College & Hospital, Pune-43

ABSTRACT

Interdisciplinary dental rehabilitation should be contemplated as a long-term solution for esthetic and functional dental rehabilitation of patients. Various guidelines for performing periodontally compatible restorative dentistry have been reviewed here. Using these basic guidelines, restorative care can be used to directly aid periodontal treatment by restoring an esthetically pleasing, and stable dentition. This article addresses interactions between periodontal tissues and restorative procedures.

Introduction

Interdisciplinary dental rehabilitation should be contemplated as a long-term solution for esthetic and functional dental rehabilitation of patients. To obtain longevity of treatment, the therapeutic decisions must be based on biologic health of periodontal and restorative foundation and must respect the functional occlusion and dental alveolar anatomy.1

The interactions between restorative dentistry and periodontal health have been well-documented both clinically and histologically. Periodontal health at the restorative gingival interface continues to represent one of the most difficult challenges for restorative dentist. Emphasis must be placed on control of bacterial plaque, coronal contour of restoration, alloy sensitivity and margin location of restoration.2 Periodontal and Prosthodontic treatment goals include working with an interdisciplinary team for diagnosis, elimination of disease, and restoration of esthetics and function.

Proper margin location of a restoration relative to alveolar bone may be one of the most important parameters in managing to ensure long-term gingival health. Restorations that interfere with host defences create sites where microorganisms thrive and cause destruction. There are four aspects of restoration design which have direct effect on periodontium: margin placement, margin adaptation, restoration contour and occlusal function.[3] This article strives to review various considerations to be kept in mind while placing a restoration.

Periodontal Considerations

It includes: Phase 1 therapy, Periodontal surgery

Phase 1 Therapy:

Control of periodontal inflammation during phase 1 therapy results in restorative procedures of much higher quality than those carried out in an environment of gingival inflammation.

Periodontal Surgery:

In some patients periodontal surgical procedures like crown lengthening should be carried out for restorative needs of patient.

Crown Lengthening

In situations in which a tooth has a short clinical crown deemed inadequate for retention of a required cast restoration, it is necessary to increase the size of the clinical crown using periodontal surgical procedures. These crown lengthening procedures enable the dentist performing restoration to develop an adequate area for crown retention without extending crown margins deep into periodontal tissues, referred to as biologic width. It can be performed by various means such as surgical means with a surgical knife or rotary curettage, electrosurgical means, lasers.

Restorative Considerations

Margin Placement Guidelines:

Mainly there are 3 types of gingival margin design in tooth preparation: Supragingival, Subgingival and Juxtagingival margin.

Supragingival margin design enables plaque control and less risks of gingival bleeding during preparation. However, esthetics of supragingival margin design is not really suitable for esthetic zone. (i.e. anterior teeth)[5,6]



Figure 1: (Supragingival margin design. by Frank M. Spear, DDS, MSD, Using Margin Placement to Achieve the Best Anterior Restorative Esthetics.)

Subgingival margin design is the most esthetic method. As compared to the natural teeth, finish line of artificial crown below the gingival crest looks like the enamel extended from the interior sulcus, without seeing the crown-root line which may achieve a better symmetrical look with other natural teeth. Nevertheless, the risk of haemorrhage of the gingiva increases since the angle of access is not visible for the dentists.[4, 5.]



Figure 2: (Subgingival margin design. by Frank M. Spear, DDS, MSD, Margin Placement for Anterior Esthetic Restorations.)

From a periodontal and esthetic point of view, the Juxtagingival margin of restoration should be positioned at gingival margin level. Esthetics could be achieved without damaging the gingiva. Normally the technique is applied for more than one tooth preparation, for example, a bridge or a fixed denture.5, 6



Figure 3: (Juxtagingival margin design. by Dr. Patrick Lesage, Expasyl® : Protocol for Use with Fixed Prosthesis.)

The first step in using sulcus depth as a guide in margin placement is to manage gingival health. Once the tissue is healthy, following three rules can be used to place intracrevicular margins.

Rule I
If sulcus probes 1.5 mm or less, place the restoration margin 0.5 mm below the gingival tissue crest. This is especially important on the facial aspect and prevents a biologic width violation in a patient who is at high risk in that regard.

Rule II
If the sulcus probes more than 1.5 mm, place the margin one-half the depth of the sulcus below the tissue crest. This places the margin for enough below tissue so that it is still covered if the patient is at higher risk of recession.

Rule III
If a sulcus greater than 2 mm is found, especially on the facial aspect of the tooth, then evaluate to see whether a gingivectomy could be performed to lengthen the teeth and create a 1.5 mm sulcus. Then the patient can be treated as mentioned in Rule-I.

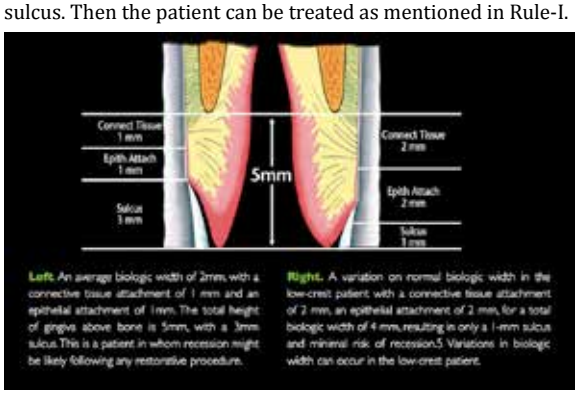

Figure 4: (Variations of biologic width. by Frank M. Spear, DDS, MSD, Margin

Placement for Anterior Esthetic Restorations.)

Tissue Retraction
To enhance access, so that damage to the soft tissues is prevented during cavity preparation and impression making, it may be desirable to carry out some degree of gingival retraction.

Retraction Cord
Tissue management is achieved with gingival retraction cords, using appropriate size to achieve the displacement required. Thin, fragile gingival tissues and shallow sulcus situations usually dictate that smaller diameter cords be chosen to achieve the desired tissue displacement.

Various chemicals used for the treatment of cords include:
- 0.1% and 8% recemic epinephrine
- 100% alum solution (potassium aluminium sulfate)
- Ferric subsulfate (Monsel's solution)
- 20% and 100% tannic acid solution

These drugs diffuse in blood circulation through crevicular epithelium which is nonkeratinized and semi-permeable and cause vasoconstriction which results in transient gingival shrinkage, cause transient ischemia and help to control seepage of blood or gingival fluid.[6]

Impression Techniques
Severe and painful periodontal reactions can occur if rubber-base impression material is introduced into the gingival tissues during impression procedures. Careful visual inspection of the impression for torn areas is needed and if evidence of tearing is detected, clinician should immediately check the tissue to remove any remnant of the impression. Otherwise a foreign body of impression material can cause severe gingival inflammation and may be misdiagnosed at a subsequent appointment.[6]

Provisional Restorations
Provisional restorations that are poorly adapted at the margins, are overcontoured, undercontoured and have rough or porous surfaces can cause inflammation, overgrowth or recession of gingival tissues. Outcome can be unpredictable and lead to unfavourable changes in tissue architecture that can compromise the success of final restoration.[7]

Crown Contour
When gingiva contacts a flat (noncontoured) tooth surface, there is a tendency to develop a thick free gingival margin. Overcontouring of restorations or faulty placement of contour is a much greater hazard to periodontal health than is lack of contour, since both supra- and subgingival plaque accumulation may be enhanced by overcontoured margins. Facial or lingual surface of a restoration should not have more than 0.5 mm bulge adjacent to the gingival margin as this may interfere with adequate plaque removal.

Furcation areas should be 'fluted' or 'barrelled out' to accommodate oral hygiene in these areas.[3]

Pontic Design
Pontics should both esthetically and functionally replace lost teeth, and at the same time be nonirritating to the mucosa and allow effective plaque control.

Classically, four options should be considered in evaluating pontic design: Sanitary, ridge lap, modified ridge lap and ovate designs. The restorative material for all four designs can be either glazed porcelain, polished gold or polished resin. There is no difference in biologic response of the tissue on contact with the restoration, regardless of the material chosen, as long as it has smooth surface finish. The sanitary and ovate pontics have convex undersurfaces that facilitate cleaning. The ridge lap and modified ridge lap designs have concave surfaces that are more difficult to access with dental floss. A modified ridge lap design can be given where there is inadequate ridge to place an ovate pontic. Whereas the facial aspect of the undersurface has a concave shape, adequate access for oral hygiene is allowed by the

more open lingual form.[8]

Hypersensitivity to Dental Materials
Only about 30% of those patients with known nickel allergy develop a reaction to an intraoral nickel chromium dental alloy. Phosphate cements and silicates are slightly irritants. Acrylic is highly irritant, although the material itself is not irritant when fully polymerized. Gingival tissues adjacent to composite resin restorations extended subgingivally will develop gingivitis even in the presence of good oral hygiene.

More importantly, tissues respond more to the differences in surface roughness of the material rather than its composition. The rougher the surface of the restoration subgingivally, the greater the plaque accumulation and gingival inflammation. The permeability of the gingival epithelium enhances the penetration of leachable components and thus the potential for toxic and allergic reactions.[9]

Crown Preparation
Whenever possible, crown margins should be placed supragingivally for ease of impressions, margin finishing and overall periodontal health. Intracrevicular margin placement may be required to cover portions of the root resected area. The crown margin should be apical to the pulpal chamber floor or root canal that was exposed by resection especially if these structures have not been sealed with amalgam. To prevent impingement on the biologic width; intracrevicular margins to cover the pulpal canal structures should be no closer than 3 mm to the alveolar crest. This may necessitate additional lengthening. To preserve remaining tooth structure and encourage a better-fitting restoration, a less complicated preparation utilizing a knife-edge finish line or a chamfer is recommended. The preparation eliminates residual ledges, roots, furcation lips or horizontal components or the furcation. In maxillary molars this includes eliminating remaining internal furcation invasions (IFI).[10]

Occlusion
Occlusal outline mirrors the gingival margin outline. The occlusal table may require extension over the area of the missing root in the following instances:

Establishing the contact with an adjacent tooth, when the bulk of metal is required for a solder joint and establishing centric stops, such as the lingual cusps of maxillary molar. Lateral forces are controlled by minimizing cuspal inclines on the resected molar and the teeth stabilizing it.

Conclusion
All phases of clinical dentistry are intimately related to a common objective: **Preservation and maintenance of natural dentition in health.** In an integrated multidisciplinary approach to dental care, it is logical that periodontal treatment precede final restorative procedures. For restorations to survive long-term, the periodontium must remain healthy so that the teeth are maintained. For the periodontium to remain healthy, restorations must be critically managed in several areas so that they are in harmony with their surrounding periodontal tissues. The integration of periodontal considerations with restorative planning is now the standard of care. Direct and frequent communication between the Periodontist and Restorative dentist is a prerequisite for predictable and satisfactory results.

REFERENCE

1. Kenneth A. Malament, DDS, MScD, Marc L. Nevins, DMD, MMSc | Thomas Singh, MDT. Interdisciplinary Solutions for Esthetic Periodontal Prosthodontic Rehabilitation. November/December 2011, Volume 32, Issue 5. Dentalaegis, AAP. | 2. Gracis S, Fradeani M, Celletti R, Bracchetti G. Biological integration of aesthetic restorations: factors influencing appearance and long-term success. Periodontology 2000 2001;27:29-44 | 3. Kois JC. The restorative-periodontal interface: biological parameters. Periodontology 2000 1996;11:29-38. | 4. Mormann W, Regolati B, Renggli H. Gingival reactions to well-fitted subgingiva proximal gold inlays. J Clin Periodontol 1974;1(2):120-5. | 5. Renggli HH. The effect of cervical subgingival restoration margins on the degree of inflammation of the neighboring gingiva (a clinical study). SSO Schweiz Monatsschr Zahnheilkd 1974;84(1):1-18. | 6. Shillingburg HT, Hobo S, Whitsett LD, Jacobi R. Fluid control and soft tissue management - fundaments of fixed prosthodontics. 3rd edition, Quintessence Publishing Co., Inc., Chicago 1997:257-80. | 7. Yuodelis RA, Faucher R. Provisional restorations: an integrated approach to periodontics and restorative dentistry. Dent Clin North 1980;24(2):285-303. | 8. Podshadley AG. Gingival response to pontics. J Prosthet Dent 1968;19(1):51- | 9. Adamczyk E, Speichowics E. Plaque accumulation on crowns made of various materials. Int J Prosthodont 1990;3(3):285-91. | 10. Malone WFP. Tylman's Theory and Practice of Fixed Prosthodontics. 8th edition 1997:71-112. |