ORIGINAL RESEARCH PAPER

Volume-8 | Issue-3 | March-2019 | PRINT ISSN No 2277 - 8179

INTERNATIONAL JOURNAL OF SCIENTIFIC RESEARCH

PERIODONTAL AESTHETIC SURGERY – A DETAILED LITERATURE REVIEW

Dental Science

Dr. Sowmiya Lingeshwaran Senior Lecturer, Meenakshi Ammal Dental College, Chennai, India

ABSTRACT

Gingival recession is the apical migration of gingival margin from the cemento-enamel junction (CEJ). The recessed tooth becomes highly unattractive and results in other consequences like hyper-sensitivity due to exposure of root surface, accumulation of plaque and calculus due to decrease in the width of attached gingiva, root caries as the surface of the root exposed to the acidic oral environment. The causes for gingival recession includes tooth malposition, alveolar bone dehiscence, high muscle attachment and frenal pull, friction from the soft tissue (gingival ablation), gingival inflammation and iatrogenic factors related to restorative and periodontal treatment procedures have been associated with the development of gingival recessions. Treatment includes identifying and eliminating the etiological factor, scaling and root planning, frenectomy / frenotomy gingival augmentation, veneers and crowns. Through screening during first visit and identifying the susceptible patients and eliminating the etiology helps in prevention.

KEYWORDS

Gingival recession, gingival augmentation, attached gingiva.

1. INTRODUCTION

Gingival recession is defined as "location of the marginal tissue apical to the cement-enamel junction(CEJ)." [1] The distance between the gingival margin and the CEJ determines the level of recession measured using William's periodontal probe. Mostly when gingival recession occurs it is symptomless, but it can progress to sensitivity and root caries when exposed to the acidic oral environment. On the other hand, even though its symptomless when it occurs in the esthetic zone it deteriorates esthetics.

2. Etiology of gingival recession

Gingival recession occurs due to

A. Mechanical/physical influence on the gingival tissues

B. Indirectly due to an inflammatory reaction in the gingival tissues.

2.1 Mechanical/physical influence on the gingival tissues

These are the factors which directly act upon the gingival tissue and cause recession. This includes

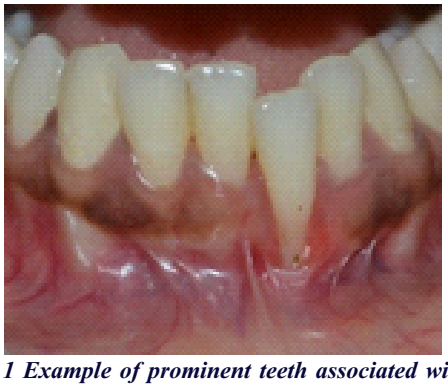

Figure 1 Example of prominent teeth associated with thin gingival biotype and recession

1. Traumatic tooth brushing habit seen mostly in patients with good oral hygiene index. Left buccal surface is mostly involved as it inflicts the right-handed individuals mostly start brushing on the left side first with full on force which can result in abrasion and recession. The recession site often appears healthy with cervical abrasion associated with it.

2. *Proclined teeth/ teeth* which is out of arch can be associated with thin alveolar bone and often may result in recession especially if there is thin gingival biotype. (Figure 1)

3. *Trauma from foreign bodies* like lip piercing, tongue piercing can cause migration of gingival tissue as the foreign bodies continuously swipe against the gingiva and might cause gingival ablation, striping and migration.

4. *Traumatic incisal relationship* can cause striping of the gingival tissues. Akerly described four incisal relationships and their effect on the soft and hard tissues [2] (Table 1).

5. *High frenal attachment* can cause migration of gingiva due to an apical pull on the gingival tissues. High frenal attachments (close to the gingival margin) may impede oral hygiene therefore leading to a localized periodontal problem and subsequent recession. (Figure 2)

6. *Iatrogenic factors* related to restorative and periodontal treatment procedures have been associated with the development of gingival recessions.

Table 1 Akerly classification of traumatic incisal relationships and their effect on soft / hard tissue [2]

Akerly classification of traumatic incisal relationships and their effect on soft / hard tissue	
Class	Description
I	Mandibular incisors impinge on the palatal mucosa
II	Mandibular incisors impinge on the palatal gingival margin of the maxillary incisors. Common in Class II Div 1 relationships
III	Mandibular incisors impinge on the palatal gingival margin of the maxillary teeth and the maxillary incisors impinge on the labial gingival margin of the mandibular incisors. Common in Class II Div 2 incisal relationship
IV	Associated with the wear facets developing on the palatal surface of the maxillary incisors and/or labial surfaces of the mandibular teeth



Figure 2 Example of aberrant frenal attachment resulting in gingival recession

Gingival recession caused by an inflammatory process

1. Presence of Sub-gingival plaque can initiate inflammation around the gingival margin. This area of inflammation rarely extends more than 1-2 mm apically and laterally therefore when the free gingival tissue is thick only a small area of connective tissue is affected. However, when the free gingival tissue is thin and delicate or in an area of alveolar dehiscence the entire connective tissue can be affected resulting in recession.

2. Periodontal disease is another common predisposing factor which results in the loss of the supporting bone around a tooth and cause gingiva to recede. Tooth affected by periodontal disease will

eventually lose bone support around the tooth through an inflammatory reaction which results in apical migration of the gingival margin.

3. Poor marginal fit, inadequate crown emergence angles, rough restoration surfaces and overhangs on restorations can act as a reservoir for plaque entrapment. This can cause gingival inflammation there by resulting in localized periodontal problems with loss of hard and soft tissue.

3. CLASSIFICATION OF GINGIVAL RECESSION

Numerous classifications are found in the literature but one of the first classifications to be proposed was by Sullivan and Atkins in 1968. [3] This classification system was based on the depth and width of the defect.

- Shallow narrow
- Shallow wide
- Deep narrow
- Deep wide

This classification had a drawback of inter-examiner variability, so this was modified by Mlinek et al (1973).[4] He quantified shallow narrow clefts as being < 3 mm in both dimensions and deep-wide defects as being > 3 mm in both dimensions. Although this modification reduced the subjective variation, there was no definite landmark specified for horizontal measurement, as variable measurement may be present at variable distances.

Miller's classification of recession defects

Miller proposed a classification system in 1985 and till date this is the most widely used system for gingival recession. [5]

Miller's Classification		
Class		Description
I		• Marginal tissue recession that does not extend to the mucogingival junction • There is no soft tissue/alveolar bone loss in the interdental areas • Complete root coverage can be achieved
II		• Marginal tissue recession that extend to or beyond the mucogingival junction • There is no soft tissue/ alveolar bone loss in the interdental areas • Complete root coverage can be achieved
III		• Marginal tissue recession that extend to or beyond the mucogingival junction • There is soft tissue/ alveolar bone loss in the interdental areas • Complete/partial root coverage can be achieved depending on clinical situation
IV		• Marginal tissue recession that extend to or beyond the mucogingival junction • Severe bone and/or soft-tissue loss in the interdental area and/or severe malpositioning of the teeth • Complete root coverage cannot be achieved

Table 5 Miller's Classification

Although, this is the widely used classification system it has various drawbacks they are

1. Miller's classification does not specify facial (F) or lingual (L) involvement of the marginal tissue.
2. The muco-gingival junction (MGJ) is used as a reference point in this classification but there are clinical difficulties in identifying MGJ. Which makes difficulty in, differentiating between class I and class II.
3. There is also difficulty in classifying between class III and IV as the severity is major criteria to differentiate between the two. A clear picture of severity of recession is hard to identify as there is no quantification specified for severity.
4. The applicability of Miller's criteria on the palatal aspect of the maxillary arch is questionable as there is no MGJ on palatal aspect.
5. Recession of interdental papilla alone cannot be classified according to the Miller's classification. It requires the use of an additional classification system.

4. Treatment for gingival recession

The aim of the treatment should be to identify and rectify the etiology. Patient's concern on sensitivity/ esthetics or both should be considered and treated accordingly. There are numerous treatment options available. It can be classified as follows (Table 3)

Table 3: Treatment for gingival recession

Non- surgical	Surgical
• Scaling and root planning • Desensitizing agents/Varnishes/Dentin bonding agents • Composite restoration • Gingival veneers/Pink porcelain • Orthodontics • Prevention and periodic monitoring	**A. Pedicle soft tissue graft** procedures *Advanced flaps* 1. Coronally positioned flap 2. Semilunar coronally positioned flap *Rotational flaps* 1. Laterally positioned flap 2. Double papilla flap **B. Free gingival graft** 1. Epithelialized soft tissue graft 2. Non epithelialized soft tissue graft (connective tissue graft)
	C. Combination grafts • 1-stage procedure - Pedicle graft with connective tissue graft -Pedicle graft with biodegradable membrane barrier • 2-stage procedure -Coronally repositioning the previously placed soft tissue graft -Non biodegradable membrane barrier plus pedicle graft

4.1 Non- surgical treatment procedures

4.1.1 Scaling and root planning

The first step in any treatment of periodontal disease is scaling and root planning (SRP). Shallow recession can be treated with SRP alone. After the SRP the gum tissues heal and there will be reachment to the root surface. For many patients along with SRP further treatment would require if the recession is severe

4.1.2 Desensitizing agents/ Varnishes/ Dentin bonding agents

When the patient's main concern is sensitivity and not the esthetics then concentrating effort should be taken to allievate the sensitivity. There are numerous products available to treat it which work either by preventing the nervous stimulation or by blocking the dentinal tubules. Varnishes, dentine bonding agents and glass ionomer cements cover the root surface and block the dentinal tubules to prevent fluid movement. They provide good resistanace to removal, off the root surface while brushing and mastication thereby they prevent sensitivity. Desenitizing tooth pastes may contain active agents like strontium, potassium, silica and oxaltes which occulude the dentinal tubules. They provide benefit when tooth paste is applied as thin layer over the exposed root surface and leaving it for approximately 30 minutes before brushing. The active agents acts on the exposed surface and reduces the sensitivity.

4.1.3 Composite restoration/ Pink porcelain

The adhesive restorations like composites have become more popular and predictable in restorative dentistry. These can be used to close the black/ dark triangles and cover the exposed root surfaces associated with the recession. Smooth finishing of composite restoration is important to ensure there are no plaque retentive areas, which can further promote gingival recession. Pink porcelain also can be used when surgical treatments are not viable option in some patients. Gingival colored porcelain or composites can be used over the root surface to eliminate dentine hypersensitivity.

4.1.4 Gingival veneers:

When the patients have large black triangles due to periodontal disease especially in the anterior zone, this might result in altered speech and deterioation in esthetics. Surgical correction of multiple areas might be imposible and unpredictable so removable gingival veneers works well in these type of patients. Removable gingival prostheses can be

made from various materials which include heat cured acrylic or silicone based soft lining materials such as molloplast B.[6,7] Heat cure acrylic materials have the disadvantage of being hard, ridgid, easy to fracture and difficult to fit around teeth. Whereas silicone base materials are flexible, have improved comfort and increased resistance to fracture.

4.1.5 Orthodontics

Buccally/ labially placed tooth may have thin gingival biotype and thin alveolar bone supporting it which is highly prone for development of gingival recession.**(Figure 1)** Orthodontic correcion of malpostioned teeth would prevent this and in some cases orthodontic treatrement plus the surgical intervention would require, in such cases surgical threapy should be postponed untill the orthodontic correction. Studies have shown orthodontic movement of the tooth lingually allows alveolar bone growth on the buccal aspect, thickening of the gingival tissue and subsequent coronal shift in the gingival margin resulting in correction of the recession defect further more it has high predictabilty. [8,9]

4.2 Surgical treatment procedures

4.2.1 Pedicle soft tissue graft:

These types of graft remain attached at their base and they retain their own blood supply during their transfer to a new location. Depending on the direction of transfer, pedicle soft tissue grafts can be divided into *advanced flap and rotational flap.*

4.2.1.1 Advanced flaps : Coronally positioned flap, Semilunar coronally positioned flap.

4.2.1.1.1 Coronally positioned flap

The coronally advanced flap can be used for root coverage of a single tooth as well as multiple teeth, provided suitable donor tissue is available. The coronally advanced flap was first described by Bernimoulin et al.[10] Since the lining mucosa is elastic, a mucosal flap raised beyond mucogingival junction(MGJ) can be stretched in coronal direction to cover exposed root surfaces.[11]

Step 1:

Two vertical incisions delineate the flap that should go beyond the mucogingival junction. Papilla can be included with the flap or preserved by giving horizontal incision at the base of the papilla. (Figure 4.b)

Internal bevel incision from the gingival margin to the bottom of the pocket to eliminate the diseased pocket wall.

Elevate a full thickness mucoperiosteal flap using careful sharp dissection. (**Figure 4.c**)

Step 2: Scale and plane the root surface.
Step 3: The flap is then sutured in place approximately 0.5 mm to 1 mm coronal to the CEJ [12] to cover up the recession site (**Figure 4.d**)

Cover the area with periodontal pack for one week.

Advantages:

- Multiple areas of root exposure can be treated
- No need for involvement of adjacent teeth
- High degree of success
- Good colour blending

Disadvantages:

- Can be done only when there is adequate amount of attached gingiva
- Vertical releasing incision delays healing

Variations

The procedure can be performed either as a one stage technique to cover shallow recession defects [13] or a two-stage technique which is combined with a free gingival graft, connective tissue graft or with guided tissue regeneration procedures.

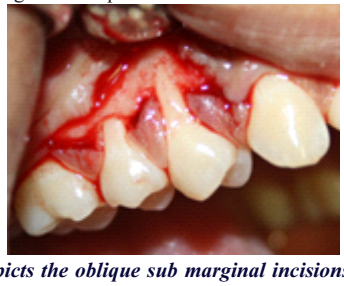

Figure 3 Depicts the oblique sub marginal incisions placed in the interdental areas

4.2.1.1.2 Coronally advanced flap procedure for multiple recessions

- Zucchelli and De Sanctis (2000) [14] described a flap design for the treatment of multiple recessions, which allows for optimal adaptation of the flap following its coronal advancement without placement of vertical releasing incisions.
- Oblique submarginal incisions are placed in the interdental areas and connected with intracrevicular incisions (**Figure 3**)
- At the most apical portion of the flap, the periosteum is incised and followed by dissection into the vestibular lining mucosa to eliminate all muscle tension.
- The remaining facial portion of the interdental papillae is de-epithelialized
- Sutures are placed to accomplish a precise adaptation of the coronally advanced flap against the teeth.



Figure 4.a Exposure of root surface in relation to 13



Figure 4.b Incisions were made

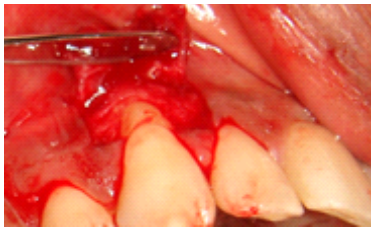

Figure 4.c Elevation of full thickness flap



Figure 4.d Suturing was done with non- resorbable suture



Figure 4.e Post-operative view after 6 months

Figure 4: Depicts upper right canine with gingival recession treated using Coronally advanced flap

4.2.1.1.3 Tarnow technique (Semilunar coronally positioned flap)

The semilunar flap, a modification of coronally positioned flap was originated by Tarnow (1986). [15] It is designed primarily for attaining esthetic root coverage where 2 to 3mm of root coverage is required. It is not recommended for mandibular teeth.

Step 1: Semilunar incision following the curvature of the gingival

margin and ending 2-3mm short of the tip of the papilla. (**Figure 5.b**) The flap derives all its blood supply from papillary area.

Step 2: Split-thickness dissection made coronally from the incision and connect to intrasulcular incision. (**Figure 5.c**)

Step 3: The flap will collapse coronally and will cover the denuded root and held in its new position for few minutes with moist gauze. There is no need to suture or pack.

Advantages:
- Simple.
- No sutures are needed.
- Provides 2-3mm root coverage.
- Can be performed on several adjoining teeth.

Disadvantage
- Not indicated for mandibular teeth as it would cause downfall of the flap and increases the recession further



Figure 5.a Gingival recession seen in relation to upper left canine



Figure 5.b Semilunar incision made



Figure 5.c Spilt thickness flap falls and covers up the recession



Figure 5.d Post- operative view after 6 months

Figure 5: Depicts treatment of gingival recession in relation to left upper canine with semilunar coronally advanced flap (Tarnow's technique)

4.2.1.2 Rotational flaps: Laterally repositioned flap, Double papilla flap.

4.2.1.2.1 Laterally repositioned flap
- The use of a laterally repositioned flap to cover areas with localized recession was introduced by Grupe &Warren (1956). [16]
- This technique involved the reflection of a full thickness flap in a donor area adjacent to the defect and the subsequent lateral displacement of this flap to cover the exposed root surface
- In order to reduce the risk of recession on the donor tooth, Grupe (1966) [17] suggested that the marginal soft tissue should not be included in the flap.
- Staffileno & Heller (1971) [18] advocated the use of a split thickness flap to minimize the potential risk for development of dehiscence at the donor tooth.

Step 1: Incise the epithelium around the exposed roots, scale and root plane the denuded surface.

Step 2: Partial thickness flap or full thickness flap is made with #15 blade by making a vertical incision 1-2mm away from the gingival margin to outline a flap adjacent to the recipient site.

- Incise the periosteum extend the incision to the base of the recipient site.
- Interdental papilla at the distal end of flap should be included to secure the flap in the interproximal space between donor and recipient site

Advantages of partial-thickness flap:
- More rapid healing in the donor site.
- Reduce the risk of facial bone height loss.

Step 3:
- Transfer the flap laterally onto the adjacent root and ensure its lying flat and firm without tension. (**Figure 6.b**)
- Fix the flap to adjacent gingiva and alveolar mucosa with interrupted sutures.

Step 4: Protect the flap and the donor site with aluminium foil, soft periodontal pack extending interdentally and onto lingual surface. Remove the pack and sutures after 1 week.

Advantages
- Good vascularity and Good colour match
- Ability to cover denuded root surface
- One surgical site
- Predictable root coverage because of uninterupted blood supply

Disadvantage
- Recession at donor site
- Dehiscence or fenestration at donor site
- Limited to 1 to 2 teeth



Figure 6.a Gingival recession seen in 41 extending up to the muco-gingival junction



Figure 6.b Flap was laterally repositioned and sutured



Figure 6.c Post- operative view after 6 months

Figure 6: Depicts the root coverage procedure using laterally reposioned flap

4.2.1.2.2 Double papilla flap

It was introduced by Waienberg in 1964 and modified by Cohen and Ross,1968.[19] It was designed to achieve adequate keratinised gingiva and root coverage by joining two interdental papillas. It is indicated when interdental papilla adjacent to receded area is sufficiently wide, attached gingiva on approximating teeth is insufficient to cause lateral displacement and when periodontal pockets are not present this procedure can be performed.

Step1: A cuff of epithelialised tissue is removed from around the recession defect to expose the underlying connective tissue

Step 2: Split thickness flaps of the papillae either side of the recession defect with vertical reliving incisions on the distal line angle and mesial line angle of the recessed tooth should be raised.(**Figure 7.a**)

Step 3:
- The two papillae are repositioned and placed over the exposed root surface and sutured together (**Figure 7.b**)
- Gentle pressure is applied for a few minutes to minimise the clot that forms under the pedicle graft and a periodontal dressing can be placed if necessary

Advantage
- Good color match and adequate blood supply
- No need for second surgical site

Disadvantage
- Inadequate suturing and inadequate stabalisation can result in separation of the two pedicle flaps resulting in failure of the procedure.

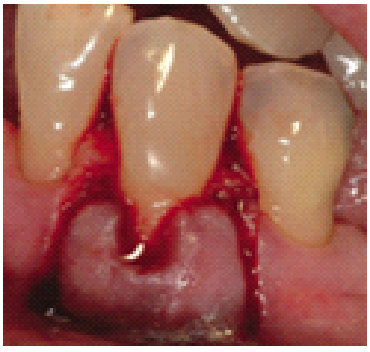

Figure 7.a Vertical incision made along the either side of the papillae on recessed tooth

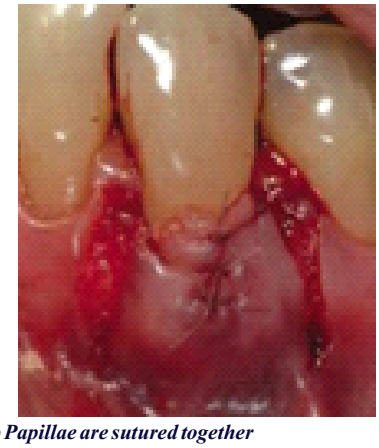

Figure 7.b Papillae are sutured together



Figure 7.c Post-operative view after 6 months
Figure 7: Depicts root coverage by Double papilla flap method

4.2.2 Free soft tissue graft procedures
These soft tissue grafts are devoid of blood supply as the name indicates and they depend upon the recipient bed for its vital nutrients.

4.2.2.1 Free gingival graft
This grafting procedure was initially described by Bjorn in 1963. [20] It is widely used to create a widened zone of attached gingiva. The surgical site of the free gingival graft heals with secondary intention within 2 to 4weeks due to the removal of the epithelial layer of the palatal mucosa. [21]

Step 1:
Scaling and root planning performed with application of saturated citric acid for 5 minutes with a cotton pledget burnishing it on the root as it promotes opening of dentinal tubules, detoxification of exposed surface and exposure of connective tissue root fibers

Step 2: Preparation of the recipient site (**Figure 8.b**)
- Horizontal papillary incision should be made in interdental papilla at right angles to create a margin at which the graft forms a butt joint with the incision.
- Two vertical incision should be made at the proximal line angles of the adjacent teeth. Periosteal bed should be extended 4-6 mm on all sides of exposed root surface.

Step 3: obtain the graft from the donor site (**Figure 8.c**)
- Graft is usually obtained from the palate; the graft should consist of epithelium and thin layer of underlying connective tissue. The epithelium undergoes degeneration whereas the connective tissue obtains its nutrients from recipient bed and regrows the epithelium during healing.
- The template made using tin foil of required size is placed over the donor site and shallow incision is made around it on the palate with blade #15.
- Then template is removed, then deep incisions are made following the previous shallow incision areas to obtain desired thickness (Figure 8.c)
- Elevate the edge and hold it with tissue forceps and separate the graft.
- Donor site is treated with hemostatic agent to attain hemostasis e.g.: gel sponge, cotton pellets, acrylic retainer.

Thickness of the graft is important for the survival.
- It should be thin enough to permit ready diffusion of nutritive fluid from the recipient site (1-1.5 mm)
- If it's too thin graft will undergo necrosis and would expose the recipient site.
- If it's too thick the peripheral layer will be jeopardized because of the excessive tissue that separates it from the blood supply and might create deeper wound at the donor site that may injure the major palatal arteries.

Step 4: Transfer and immobilize the graft
- The graft is trimmed to avoid bulbous marginal and interdental contours
- Then transfer it to the recipient site (Figure 8.d)
- Apply gently pressure against the recipient bed to remove excess tissue fluid and blood clot because it may interfere with blood supply.
- The space between the graft and underlying tissue retard the vascularization so graft should be in close contact with the periosteal bed
- The graft should be immobilized.
- Avoid excessive tension, movement and trauma. The tissue forceps should be used delicately, and minimum number of suture used to avoid tissue perforations.

Step 5: Protection of the recipient site
- Cover it with periodontal pack for one week.

Advantages
- Ability to treat multiple teeth
- Can be done in cases with reduced keratinized gingiva

Disadvantages
- Two operative sites
- Color mismatch
- Compromised blood supply
- Greater discomfort at donor site
- Large denuded surface at donor site after healing
- Lack of predictability for root coverage
- Retention of graft
- If the donor tissue is taken from the palatal rugae area, there might be tyre patch appearance at recipient site
- Technique sensitive



Figure 8.a Pre- operative view
Figure 8.b Preparation of the recipient site
Figure 8.c Outline of graft on palate




Figure 8.d Suturing of the graft at the recipient site
Figure 8.e 3 months post-operative view

Figure 8. Depicts the root coverage procedure using free gingival autograft

4.2.2.2 Free Connective tissue autograft:

- The difference between this technique and free gingival autograft is that, here donor tissue is connective tissue whereas in free gingival autograft it is the epithelium.
- It was described by Edel in 1974 [22] but it did not receive wide approval. Later Langer and Langer (1985) [23] described the sub-epithelial connective tissue graft technique for covering gingival recession of both single and multiple teeth.
- Langer & Calagna (1980)[24] and Langer & Langer (1985)[23] introduced a surgical procedure with a rectangular shaped flap design, obtaining a connective tissue graft along with a thin epithelial tissue.
- It is indicated for larger & multiple defects with good vestibular depth
- It is a bilaminar technique in which the connective tissue graft is covered with a repositioned split thickness flap to maximize the supraperiosteal and gingival blood supply to the grafted tissue.
- A free connective tissue graft is placed over the recession area while the nutrients and revascularization are derived from the recipient bed, interdental papilla and the overlying flap. Because of its high predictability it is considered the gold standard procedure in coverage of denuded roots.

Step 1:

- Raise partial thickness flap with horizontal incision 2mm away from the tip of the papilla. (**Figure 9.b**)
- Two vertical incisions 1-2mm away from the gingival margin of adjoining teeth.
- Incisions should extend, wider mesiodistally than the area of gingival recession.
- Extend the flap to the mucobuccal fold without perforation that could affect the blood supply.

Step 2: Thoroughly plane the root reducing its convexity.

Step 3: Trap door technique (Figure 9.c)

- Obtain connective tissue graft from the palate by means of three incision, one horizontal incision 5-6mm from the gingival margin of molars and premolars and two vertical incision connected with the horizontal incision.
- The flap opens like a trap door and then graft can be obtained
- The adipose and glandular tissue is removed from the connective tissue graft (Figure 9.d)

The second concern while procuring the donor tissue is the thickness, width, and length of the graft. The anatomy of the palatal vault is divided into:

- **Average palate:** The average distance from the cemento-enamel junction (CEJ) to the neurovascular bundle is 12 mm.
- **High palate:** The average distance from the CEJ to the neurovascular bundle is 17 mm.
- **Shallow palate:** The average distance from the CEJ to the neurovascular bundle is 7 mm.

Step 4: Place the connective tissue on denuded roots and suture it with resorbable suture to the periosteum. (**Figure 9.e**)

Step 5:

- Cover the connective tissue graft with partial thickness flap and suture it interdentally. (**Figure 9.f**)
- At least 1/2 – 2/3rd of the connective tissue graft must be covered by the flap for the exposed portion of connective tissue graft to survive over denuded root surface.

Step 6:

- Cover the area with tin foil and surgical pack.
- After 7 days, dressing and sutures can be removed.

Advantages:

- The predictability of the connective tissue grafting procedures to obtain root coverage is excellent, because it provides a good dual blood supply to the graft
- Also, it provides excellent esthetics with good gingival color match and minimal likelihood of keloid formation.
- Contrary to free gingival graft, the donor site wound is less extensive
- It is applicable to both isolated wide areas of gingival recession and multiple root exposure



Figure 9.a Pre- operative view with multiple recession sites

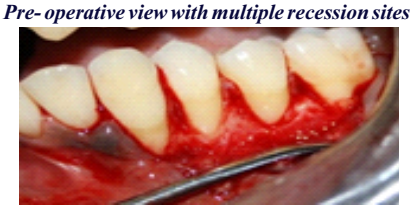

Figure 9.b Partial thickness flap raised

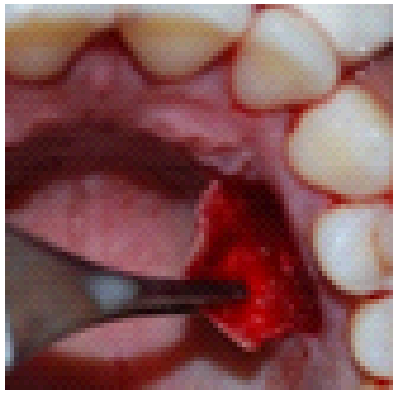

Figure 9.c Trap door technique



Figure 9.d Connective tissue graft



Figure 9.e Placement of CTG at recipient site



Figure 9.f Flap approximated coronally and sutured



Figure 9.g Post- operative view after 1 month
Figure 9: Multiple recession site treated in combination with connective tissue graft and coronally advanced flap

Disadvantages:
- The inability to obtain adequate amount of donor tissue for multiple recession sites
- Longer surgical time and technique sensitive results

3. Guided tissue regeneration (GTR)
The use of a membrane barrier, according to the principles of GTR, in conjunction with pedicle soft tissue graft procedures was introduced as a treatment modality for root coverage by Pini Prato et al.in 1992. [25]

Principles of GTR include
- Selective repopulation of periodontal ligament cells that can form new connective tissue attachment between the root surface and alveolar bone
- Maintenance of space between root surface and epithelial cells
- Clot establishment and stabilization
- Epithelial cell exclusion
- Neovascularization

Gottlow's Classification of GTR [26]
First generation: Non- resorbable membranes
Second generation: Resorbable membranes
Third generation: Resorbable membranes with growth factors

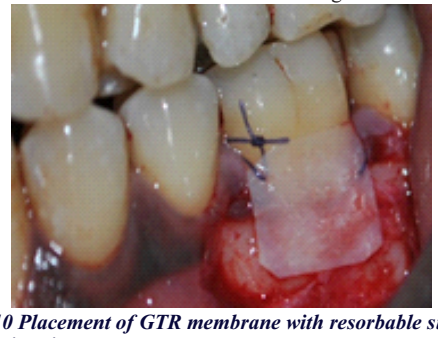

Figure 10 Placement of GTR membrane with resorbable sutures at the recession site

The use of guided tissue regeneration procedure for root coverage shows evidence of regeneration of a new periodontal tissue attachment. The outcomes have been attempted with promising clinical and histological results.[28] GTR have been mostly used in conjugation with other techniques for root coverage such as pedicle graft where membrane is placed in between the root surface and the graft to enhance the new periodontal ligament cells for formation of true new periodontal attachment (**Figure 10**)

3. Acellular Dermal Grafts(ADM)
Acellular dermal matrix graft harvested from the cadavers/human donors obtained from approved tissue banks and processed to remove the epidermal and dermal cells leaving behind a regenerative collagen matrix with preservation of the ultra-structural integrity. It provides a matrix consisting of collagen, elastin, blood vessel channels, and proteins that support
1. revascularization
2. cell repopulation and
3. Tissue remodeling.

Advantages
1. Easy to handle
2. Treats single/ multiple sites
3. Highly predictable
4. Highly esthetic
5. Multipurpose use

Many clinical studies revealed the effectiveness of ADM in the treatment of gingival recession defects. A meta-analysis comparing the efficacy of ADM allografts to other methods concluded that ADM-based root coverage therapy can be used successfully to repair gingival recession defects and to increase keratinized gingival [28].

4. Prevention and Periodic monitoring of gingival recession
The ultimate aim of the treatment should be prevention of further gingival recession. Identifying the etiological factors along with the degree of involvement is necessary. The degree of recession should be monitored to identify the signs of further progression. It is also important to maintain good oral hygiene to prevent plaque induced inflammation which can result in further recession especially in thin gingival biotypes. If recession is minimal and not in esthetic zone, then identifying the etiology for example faulty tooth brushing then explaining the patient and correcting it would be the ideal option. If recession is in esthetic zone and if there is signs of hypersensitivity or root caries, then further treatment option should be considered. Through screening during first visit and identifying the susceptible patients and eliminating the etiology along with continuous monitoring during the recall visits helps in prevention. Initially patient should be treated non- surgically. Further, if required then surgical option should be considered. Numerous technical literatures are available for root coverage. But, its clinician's experience and knowledge helps him/she to accurately assess and execute ideal procedure suitable for specific site to obtain best predictable results.

ACKNOWLEDGMENTS
First and foremost I am grateful to God Almighty and I am thankful to my father Mr.Lingeshwaran for giving me the strength and support to achieve this endeavor. I would like to show my gratitude to Dr.T. Ramakrishnan my mentor and guide for providing encouragement to bring out innovation, talent and spirit in his students.

I feel deeply indebted to my husband Mr. Prasanna kumar SJ for his constructive feedback, valuable advice and suggestions for the corrections, modification and improvement did enhance the perfection in performing my job well.

REFERENCES
1. Kassab M M, Cohen R E. Treatment of gingival recession. J Am Dent Assoc 2002; 133: 1499–1506.
2. Akerly W B. Prosthodontic treatment of traumatic overlap of the anterior teeth. J Prosthet Dent 1977; 38: 26–34.
3. Sullivan HC, Atkins JH. Free autogenous gingival grafts. 3. Utilization of grafts in the treatment of gingival recession. Periodontics. 1968;6:152–60.
4. Mlinek A, Smukler H, Buchner A.The use of free gingival grafts for the coverage of denuded roots. J Periodontol. 1973 Apr;44(4):248-54.
5. Miller Jr, P.D, 1985. A classification of marginal tissue recession. Int. J. Periodont. Rest. Dent. 5 (2), 8–13.
6. Barzilay I, Irene T. Gingival prostheses a review. J Can Dent Assoc 2003; 69: 74–78.
7. Carvalho W, Barboza E P, Gouvea C V. The use of porcelain laminate veneers and a removable gingival prosthesis for a periodontally compromised patient: a clinical report. J Prosthet Dent 2005; 93: 315–317.
8. Baker P, Spedding C. The aetiology of gingival recession. Dent Update 2002; 29: 59–62.
9. Wennstrom J L. Mucogingival considerations in orthodontic treatment. Semin Orthod 1996; 2: 46–54.
10. Bernimoulin J P, Luscher B, Muhlemann H R. Coronally repositioned periodontal flap. Clinical evaluation after one year. J Clin Periodontol 1975; 2: 1–13.
11. Harvey PM. Management of advance periodontitis. Part 1.Preliminary report of a method of surgical reconstruction. N Z Dent J 1965;61:180-7.
12. Maynard J G, Jr. Coronal positioning of a previously placed autogenous gingival graft. J Periodontol 1977; 48: 151–155.
13. Allen E P, Miller P D, Jr. Coronal positioning of existing gingiva: short term results in the treatment of shallow marginal tissue recession. J Periodontol 1989; 60: 316–319.
14. de Sanctis M, Zucchelli G.Coronally advanced flap: a modified surgical approach for isolated recession-type defects: three-year results. J Clin Periodontol. 2007 Mar;34(3):262-8.
15. Tarnow DP. Semilunar Coronally Repositioned Flap. J Clin Periodontol. 1986;13:182–5.
16. Grupe HE, Warren RF. Repair of gingival defects by sliding flap operation. J Periodontol. 1956;27:92–5
17. Grupe HE. Modified technique for the sliding flap operation. J Periodontol. 1966 Nov-Dec;37(6):491-5.
18. Staffileno H, Levy S, Gargiulo A. Histologic study of cellular mobilization and repair following a periosteal retention operation via split thickness mucogingival flap surgery. J Periodontol. 1966 Mar-Apr;37(2):117-31.
19. Cohen DW, Ross SE. The double papillae repositioned flap in periodontal therapy. J Periodontol 1968 Mar;39(2): 65-70.
20. Bjorn H. Free transplantation of gingiva propria. Sven Tandlak Tidskr. 1963;22:684–68
21. Farnoush A.Techniques for the protection and coverage of the donor sites in free soft tissue grafts. J Periodontol. 1978 Aug;49(8):403-5.
22. Edel A. Clinical evaluation of free connective tissue grafts used to increase the width of keratinised gingiva. J Clin Periodontol. 1974;1(4):185-96.
23. Langer, B., Langer, L., 1985. Subepithelial connective tissue graft technique for root coverage. J. Periodontol. 56 (12), 715–720.
24. Langer B, Calagna L.The subepithelial connective tissue graft. J Prosthet Dent. 1980

Oct;44(4):363-7.
25. Pini-Prato, G., Baldi, C., Pagliaro, U., Nieri, M., Saletta, D., Rotundo, R., et al., 1999. Coronally advanced flap procedure for root coverage. Treatment of root surface: root planning versus polishing. J. Periodontol. 70 (9), 1064–1076.
26. Gottlow J, Nyman S, Lindhe J, Karring T, Wennström J.New attachment formation in the human periodontium by guided tissue regeneration. Case reports. J Clin Periodontol. 1986 Jul;13(6):604-16.
27. Harris, R.J., 2002. GTR for root coverage: a long-term follow-up. Int. J. Periodont. Rest. Dent. 22 (1), 55–61.
28. Gapski R., Parks C.A., Wang H.L. Acellular dermal matrix for mucogingival surgery: a meta-analysis. J. Periodontol. 2005;76(11):1814–1822.