ORIGINAL RESEARCH PAPER

Volume-8 | Issue-1 | January-2019 | PRINT ISSN No 2277 - 8179

INTERNATIONAL JOURNAL OF SCIENTIFIC RESEARCH

PERITONITIS FOLLOWING POST-PLACENTAL INSERTION OF CU-T AT THE TIME OF LOWER SEGMENT CAESAREAN SECTION- CASE REPORT

Gynaecology

Paapa Dasari Professor, Dept of OBGY, JIPMER, Puducherry

ABSTRACT

A 29 year old para 2 living 2 was hospitalized through our emergency Obstetric services with complaints of pain lower abdomen and abdominal distension since 12 th post-operative day following LSCS with intracaesarean CU-T. She was febrile with abdominal distension and discoloration of abdominal skin. There was guarding and rigidity suggesting peritonitis. USG abdomen revealed loculated ascites with CU-T in situ. After diagnostic aspiration she was started on empirical antibiotics and later treated with specific antibiotics as the diagnostic grew enterococcus. Review after 5 days showed persistent ascetic fluid in POD and the same was drained through colpotomy and CU-T was removed. She made quick recovery after that and was discharged home with alternate contraceptive advice.

KEYWORDS

1. Intra caesarean Cu-T, 2. Peritonitis, 3.Sepsis

INTRODUCTION:

Post-placental insertion of CU-T is recommended by WHO and practiced recently as one of the safe and effective method of contraception. The ACOG practice bulletin [1] on long acting reversible contraception also concludes it as a safe and effective contraceptive method. Various studies comparing post-placental insertion at the time of Caesarean section with that of vaginal deliveries did not report sepsis as one of the adverse events. Prophylactic antibiotics are not recommended after post-placental insertion. Severe sepsis following an elective Caesarean is rare. It is not clear whether sepsis is associated with post-placental insertion of CU-T or due to caesarean section per se. Hence this case is reported.

CASE:

A 29 year old para 2 living 2 was hospitalized through our emergency Obstetric services with complaints of pain lower abdomen and abdominal distension since 12 th post-operative day following LSCS at some other hospital She developed increase in pain abdomen from 4 th postoperative day and abdominal distension from 10 th post-operative day. There was no history of fever, vomiting or burning micturition. She was taking oral fluids from the second post-operative day. She was treated with broad spectrum antibiotics for 5 days following her surgery. She underwent an Ultrasound examination which reported ascites and hepatomegaly , with a live rspan of 16.5 cm. At admission she was conscious and had a temperature of 100^0F, pulse rate of 116/min and a BP of 120/70 mm HG. Her respiratory and Cardiovascular systems did not reveal any abnormality. Abdomen was moderately distended with blackish discolouration above the pfannensteil insicion up to umbilicus. There was abdominal wall oedema below the umbilicus in the hypogastric region and the wound has healed. There was diffuse tenderness and guarding on palpation and shifting dullness was positive. Per speculum examination lochia was healthy No CU-T threads seen Per vaginal examination the cervix was drawn up and the size of the uterus was not made out and there was a tender boggy feel in posterior fornix. A provisional clinical diagnosis of septic peritonitis was made.USG abdomen revealed free fluid in abdomen with locules. Cu-T seen within the uterus and there was minimal endometrial collection (Fig 1). Diagnostic aspiration showed straw coloured fluid which grew Enterococus fecalis –sensitive to Gentamycin, Tetracycline and Vancomycin Ascitic fluid ADA was - 10.1 : LDH- 224. Her haemogram showed Hb-8 gm% ;TLC-14,000/cmm; Platelets- 5,00,000/cmm;Normochromic normocytic RBC PT/INR=15.2/1.16;Urea-16 mg/dl;S. Creatinine-0.9 mg/dl;Na+-143 meq/l;K+---4.8 meq/l;Total Bilirubin—0.8 mg/dl;Urine c/s –sterile;Cervical swab C/S-Candida sps sensitive to flucanozole; X-Ray chest P/A –Normal;Mantoux- Negative. She was managed conservatively and started on broad spectrum intravenous antibiotics i.e., Ceftriaxone, metronidazole and amikacin.

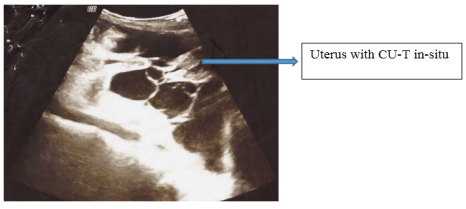

Fig 1. USG abdomen: shows loculated fluid and uterus with CU-T

After the antibiogram of ascitic fluid which grown enterococus fecalis she was treated with injection Gentamicin for 5 days USG after a course of specific antibiotics Repeat USG after 5 days showed loculated fluid pockets still persisting and POD had large fluid pocket.

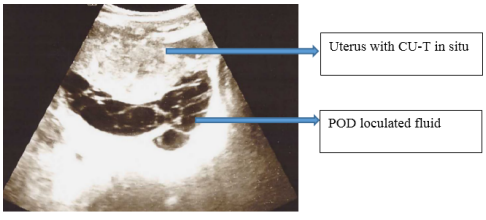

Fig 2: USG after a course of antibiotics

Hence colpotomy and drainage of pus was performed and CU-T was removed at the same time. Approximately 200 ml of blood stained thick fluid was drained .A corrugated drain was kept in POD kept for 3 days. Colpotomy fluid culture did not report any growth.

She recovered completely with a sense of well being, loss of abdominal distension and discolouration and oedema and she was discharged home with advice to use alterative contraception. The recovery was fast after removal of CU-T and drainage of the fliud.

DISCUSSION:

Postpartum insertion of IUCD is one of the effective methods of promoting contraception as the women are well motivated during this time and accept it with little hesitation. Immediate postplacental insertion specially at the time of Caesarean section is advantageous as it was found to be associated with lower expulsion rates when compared to pos-placental insertions after vaginal delivery[2] The failure rate is reported to be only 0.8% when compared to 0.5% with female sterilisation[1]. The complications of post placental insertion was studied in 653 women who underwent CU-T insertion at the time of caesarean section and 384 women after vaginal delivery by shukla and collegues in north India. The cumulative expulsion rate at the end of 6 months was 10.7% and the most common side effect was menorrhagia and there were no cases of infection[3]. The safety, efficacy of postplacental IUCD (CU-T 380 A) insertion at caesarean section was studied in 300 primparous women by Sunitha Singal and collegues. They reported 91% continuation rates .0.67% failure,5.3% expultion and 7% removal at the end of 12 months. Only one case of puerperal sepsis occurred within one month post insertion which resulted in removal of CU-T.[4]The rate of post partum endometritis was 3.4% with post placental insertion of IUCD when compared to 4.5% without IUCD and it was concluded that postpartum IUCD did not result in increased incidence of infection[5]

The study by Sevki Celen and colleagues who inserted CU-T at caesarean section in 245 cases reported high expulsion in 17.6% and removal in 8.2% for bleeding and pain and there was no report on the incidence of infection[6]. Jisha Bai CP studied 100 subjects who underwent postpartum IUCD after vaginal delivery as well as after caesarean section and found that there were no expulsions in women

after caesarean section and women who underwent Post placental IUCD were more satisfied with the method than women after vaginal delivery [7]

The Cochrane review 2015 concluded that though the expulsion rate is high when compared to interval insertion, post placental insertion outweighs the benefits in terms of eliminating the return for contraceptive visit with similar side-effects. The incidence of infection was not assessed in this review[8]

CONCLUSION:

- Sepsis to be listed as one of the rare complications of post placental insertion of CU-T at caesarean section.
- Removal of CU-T is essential for recovery from sepsis in such cases.

REFERENCES:

1. Long acting reversible contraception: Implants and Intrauterine Devices. Practice Bulletein. ACOG.2011;121.
2. Suri V. Post-placental insertion of intrauterine contraceptive device. Commentry.Indian J med Res. 2012; 370-371.
3. Manju S, Quereshi S and Chandrawathi. Post-placental intrauterine device insertion:A five year experience in a tertiary care centre in North India. Indian J med res. 2012;136:432-435
4. Singal S,Bharati R, Dewan R et al. Clinical outcome of post placental Copper T 380 A insertion in women delivering by Caesarean section. J Clin Diag Res. 2014; 8(9): OC01-OC04.
5. Welkovic S Costa LO, Faúndes A, de Alencar Ximenes R, Costa CF. Postparum bleeding and infection after post-placental IUD insertion.Contraception.2001;63:155-8.
6. Celen S, Sucak A, Yildtz Y, Danisman N.Immediate postplacental insertion of an intrauterine contraceptive device during Caesarean section.Contraception. 2011;84: 240- 243.
7. Jisha Bai CP. A study on the complications of immediate postpartum IUCD insertion.J of Evidence based Medicine and Health care.2015;2:1246-1251.
8. Lopez LM, Bernholc A, Hubacher D, Stuart G, Van Vliet HAAM. Immediate postpartum insertion of intrauterine device for contraception. Cochrane Database of Systematic Reviews 2015, Issue 6. Art. No.: CD003036. DOI: 10.1002/14651858. Cd003036. pub3