Volume : 5 | Issue : 10 | October 2016 • ISSN No 2277 - 8179 | IF : 3.508 | IC Value : 69.48

Original Research Paper

Plastic Baby with Rubber Doll-Like Skin

Healthcare

KEYWORDS : Plastic baby/ collodion baby, rubber doll, reptile scales, ichthyosis,

Akoijam Mamata Devi

ABSTRACT

Background: *Plastic baby are those babies who looks like a rubber doll and sheds skin like that of reptile scales at birth. It is also known as the collodion baby which is a descriptive term for the infant, born encased in a tight shiny membrane that resembles plastic wrap1.*

Method: *This article explains the incidence, causes, pathogenesis, signs & symptoms and various recent treatment modalities for plastic baby.*

Result: *Unfortunately, most of people are unaware that this types baby can be born and till now only 2 cases are report in India.*

Conclusion: *Recent advancement in the understanding of the causative genetic defects making DNA-based prenatal diagnosis is now possible, using chorionic villus or amniotic fluid sampling procedures early in pregnancy, with a lower risk to fetal health and with a reduced burden on the parents.*

Introduction

In Amritsar, Guru Nanak Dev Medical College and Hospital,2015 a baby' girl who looks like a rubber doll with wax and glowing skin, was born . The baby's eyes and lips are red hot, and her mother, who belongs to Amritsar's Rajasansi area, finds it difficult to feed her. Scientifically, babies born with such disorders are called collodion babies, who have extra layer of skin, which will be shedded like reptile scales. They are also known as plastic babies. Only one out of six lakh newborns have such disorders. This is a kind of genetic disorder. It is due to mutation of certain genes and is usually an autosomal recessive, congenital ichthyosis (scaly skin condition)[2]. Earlier in 2014, a plastic baby was born in the Civil Hospital but died within three days of birth[6].

The term collodion baby refers to a clinic entity used for newborns who are encompassed by a translucent, tight and parchment paper like skin sheets so called collodion membrane, on the entire body surface. Collodion baby as a term was first used by Hallopeau in 1884 . Since then approximately 270 cases were reported. Although, some other diseases and situations may lead to collodion membrane formation in almost all the cases the cause is an autosomal recessive ichthyosiform disease[3]. In order of frequency, congenital ichthyosiform erythroderma (especially, nonbullous form), lamellar ichthyosis and harlequin ichthyosis (which is usually accepted to fea turing autosomal recessive inheritance) are responsible. Rarely there may be an association with bullous congenital ichthyosiform erythroderma, Gaucher's disease and Sjögren-Larsson syndrome. Furthermore, a new form of the disease with an autosomal recessive inheritance called "self healing collodion baby" has been notified where the newborn completely recovers in a couple of weeks. Nevertheless there some other collodion baby causes that have been notified in individual publications[4].

Definition:

The collodion baby is born with tight, waxy, shiny skin resembling plastic (called a collodian membrane), while mouth resembling that of a fish, and red hot eyes and lips (caused by the tight scaly skin) — is caused by a rare inherited genetic disorder (autosomal recessive genetic disorder) called Lamellar Ichthyosis[1].

Plastic babies develop cracks in their skin after birth and baby's membrane gets peeled off automatically within a period of 15 to 30 days[6].

Incidence:

It affects about one in every 600,000 people[7].

Causes:

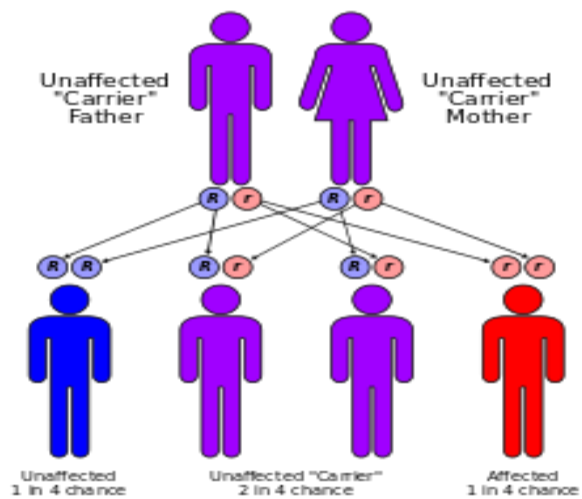

Fig. 1: Ichthyosis lamellaris has an autosomal recessive pattern of inheritance

It is a genetic disorder. It is due to mutation of certain genes and is usually an autosomal recessive, congenital ichthyosis (scaly skin condition).

This condition is an autosomal recessive genetic disorder, which means the defective gene is located on an autosome, and both parents must carry one copy of the defective gene in order to have a child born with the disorder. Carriers of a recessive gene usually do not show any signs or symptoms of the disorder [6-8].

Pathogenesis :

The collodion membrane occurs due to an epidermal cornification disorder just like all the ichthyosiform diseases. Although, the pathogenesis of molecular mechanisms apparently lead to an epidermal cornification disorder, keratinocyte protein and lipid metabolism defects resulting from autosomal recessive genetic mutations have also been notified as important cofactors [9]. The cause of both autosomal recessive lamellar ichthyosis and congenital ichthyosiform erythroderma (nonbullous) have been reported to be transglutaminase 1 gene mutation localized on the 14q11. Moreover, both varied molecular pathogenesis mechanisms and 5 different gene localizations and more than 50 gene mutations in these genes have been detected[10] .

Volume : 5 | Issue : 10 | October 2016 • ISSN No 2277 - 8179 | IF : 3.508 | IC Value : 69.48

Sign & Symptom[11-12]:

Eyes and lips are red hot

Extra layer of skin, which will be shedded like reptile scales

Lose fluid and heat from their body through the extra layer of their skin, leading to hypothermia and dehydration, apart from many other skin infections and diseases.

Desquamation or peeling, which is very painful.

The baby starts crying when someone touches her.

Looks like a rubber doll and her face appears to be similar to that of a fish.

Not able to take feed from her mother

Hypothermia

Dehydration

Associated medical problems[13-14]:

Overheating: The scaling of the skin prevents normal sweating so hot weather and/or vigorous exercise can cause problems.

Eye problems: The eyelids can be pulled down by the tightness of the skin and this can make eyelids (but usually just the lower one) very red and they are prone to drying and irritation.

Constriction bands: Very rarely children with this condition can have tight bands of skin around their fingers or toes (usually at the tips) that can prevent proper blood circulation to the area.

Hair loss: Severe scaling of the skin on the scalp can lead to patchy loss of hair, but this is rarely permanent.

Appearance and treatment at birth:
The appearance is often described as a shiny film looking like a layer of vaseline. The eyelids and mouth may have the appearance of being forced open due to the tightness of the skin. There can be associated eversion of the eyelids (ectropion)[6].

Collodion baby can have severe medical consequences, mainly because the baby can lose heat and fluid through the abnormal skin. This can lead to hypothermia and dehydration. Strategies to prevent these problems are the use of emollients or nursing the baby in a humidified incubator. There is also an increased risk of skin infection and mechanical compression, leading to problems like limb ischemia. There is also a risk of intoxication by cutaneous absorption of topical products, for example salicylate intoxication (similar to aspirin overdose) due to keratolytics[7].

The condition is not thought to be painful or in itself distressing to the child. Nursing usually takes place in a neonatal intensive care unit, and good intensive care seems to have improved the prognosis markedly. The collodion membrane should peel off or "shed" 2 to 4 weeks after birth, revealing the underlying skin disorder.The condition can resemble but is different from harlequin type ichthyosis[8].

Long term course:
The appearance can be caused by several skin diseases, and it is most often not associated with other birth defects. In most cases, the baby develops an ichthyosis or ichthyosis-like condition or other rare skin disorder.

Most cases (approximately 75%) of collodion baby will go on to develop a type of autosomal recessive congenital ichthyosis (either lamellar ichthyosis or congenital ichthyosiform erythrodema)[9].

In around 10% of cases the baby sheds this layer of skin and has normal skin for the rest of its life. This is known as *self-healing collodion baby*[3].

The remaining 15% of cases are caused by a variety of diseases involving keratinization disorders. Known causes of collodion baby include ichthyosis vulgaris andtrichothiodystrophy. Less well documented causes include Sjögren-Larsson syndrome, Netherton syndrome, Gaucher disease type 2, congenital hypothyroidism, Conradi syndrome, Dorfman- Chanarin syndrome, ketoadipiaciduria, koraxitrachitic syndrome, ichthyosis variegata and palmoplantar keratoderma with anogenital leukokeratosis. Since many of these conditions have an autosomal recessive inheritance pattern, they are rare and can be associated with consanguinity. Tests that can be used to find the cause of collodion baby include examination of the hairs, blood tests and a skin biopsy[10].

However, in the collodion babies with localized lesions local retinoic acid and calsipotriol treatments have been reported to be successful. Systemic retinoids which are currently a preferred treatment method giving impressive results in cases with generalized lesions have been notified as a perfect alternative. When systemic retinoids came into the practice the mortality rates decreased expressively. In a study, acitretin has been used at the dose of 0,5- 0,75 mg/kg/day and the mortality rate of collodion babies has decreased to 11% (1986) compared to the numbers of 1960 (50%). In cases of lamellar ichthyosis, systemic retinoids have been begun at doses of 0,5 mg/kg/day and later on the doses have eventually been increased to 2 mg/kg/day. It is notified by the authors that the greatly thick scales have improved expressively[11]. Systemic retinoids have also shown to been effective for cases with congenital ichthyosiform erythroderma. Although, harlequin fetus is rare among all the ichthyosiform diseases, without any dispute it is the severest form. Hence, high mortality rates have been observed. Nonetheless, in recent years, in these rates have also been declined because of the entrance of systemic retinoids into the clinical practice and the advanced care methods which are used in intensive care units[14-16].

Treatments
As with all types of ichthyosis, there is no cure but the symptoms can be relieved[16].

Moisturizers
Prevention of overheating

Eye drops (to prevent the eyes from becoming dried out)

Systemic Retinoids (Isotretinoin and acitretin are very effective, but careful monitoring for toxicity is required. Only severe cases may require intermittent therapy.

Psychological therapy or support may be required as well [17-18].

Reference:

1. Harting M, Brunetti-Pierri N, Chan CS et al. Selfhealing collodion membrane and mild nonbullous congenital ichthyosiform erythroderma due to 2 novel mutations in the ALOX12B gene. Arch Dermatol 2008; 144: 351-356. (Abstract) PMID: 18347291
2. Hannah Osborne. India: Tragic 'plastic baby' resembling rubber doll born in Amritsar. May 13, 2015 11:40 BST. http://www.ibtimes.co.uk/india-tragic-plastic-baby-resembling-rubber-doll-born-amritsar-1501078.
3. Gysel VD, Lijnen RL, Moekti SS et al. Collodion baby: a follow-up study of 17 cases. J Eur Acad Dermatol Venereol 2002; 16: 472-475 PMID: 12428840
4. Larregue M, Ottavy N, Bressieux JM, Lorette J. Collodion baby: 32 new case reports. Ann Dermatol Venereol 1986 French.113 (9); 773–85. PMID 3548541.
5. Van Gysel D, Lijnen RL, Moekti SS, de Laat PC, Oranje AP .Collodion baby: a follow-up study of 17 cases. J Eur Acad Dermatol Venereol Sep 2002.**16** (5): 472–5. doi:10.1046/j.1468-3083.2002.00477.x. PMID 12428840.
6. Manjeet Sehgal. Amritsar woman gives birth to a plastic baby. Chandigarh, May 11, 2015. http://indiatoday.intoday.in/story/plastic-baby-amritsar-woman-collodion-baby-guru-nanak-dev-hospital/1/437305.html.
7. Guneet Bhatia. Meet The Rare 'Plastic' Baby Born With Rubber Doll-Like Skin. May 12 2015 6:30 PM EDT. http://www.ibtimes.com/meet-rare-plastic-baby-born-rubber-doll-skin-1917780
8. Judge MR. Collodion baby and Harlequin ichthyosis. Harper J, Oranje A, Prose N. Textbook of Pediatric Dermatology. Second edition. Malden, Blackwell Publishing, 2006; 118-125.
9. Shwayder T, Akland T. Neonatal skin barrier: structure, function and disorders. Dermatol Therapy 2005; 18: 87-103. PMID: 15953139
10. Judge MR, McLean WHI, Munro CS. Disorders of keratinization. Burns T, Breathnach S, Cox N, Griffiths C. Rook's Textbook of Dermatology. 7th ed. Malden, Blackwell Publishing, 2004; 34.1-34.111.
11. Fleckman P, Digovanna JJ, The Ichthyoses. Klaus W, Goldsmith LA, Katz SI, Gilchrest BA, Paller AS, Leffell DJ. Fitzpatrick's Dermatology In General Medicine. 7th edition. New York, McGraw-Hill Medical, 2008; 401-424.
12. Jeon S, Djian P, Gren H. Inability of keratinocytes lacking their specific transglutaminase to form cross-linked envelopes: Absence of envelopes as a simple diagnostic test for lamellar ichthyosis. Proc
13. Taieb A, Labreze C Collodion baby: what's new".J Eur Acad Dermatol Venereol. Sep2002. **16** (5):436–7. doi:10.1046/j.14683083.2002.00478.x.PMID 12428832.
14. Yamamura S, Kinoshita Y, Kitamura N, Kawai S, Kobayashi Y (2002). "Neonatal salicylate poisoning during the treatment of a collodion baby". Clin Pediatr (Phila) 41 (6): 451–2. doi:10.1177/000992280204100615. PMID 12166800
15. Dermatology at the Millennium, By Delwyn Dyall-Smith, Robin Marks, Page 586, Published by Informa Health Care, 1999, ISBN 1-85070-005-2
16. James, William; Berger, Timothy; Elston, Dirk (2005). Andrews' Diseases of the Skin: Clinical Dermatology. (10th ed.). Saunders. ISBN 0-7216-2921-0.
17. Annu James. Plastic Baby' Born in Amritsar. May 11, 2015 15:23 IST. http://www.ibtimes.co.in/plastic-baby-born-amritsar-photo-632015
18. Jahanvi. Amritsar Woman Gives Birth To Plastic Baby. Indian Today. http://topyaps.com/plastic-baby-born-in-amritsar