Research Paper

Volume : 2 | Issue : 3 | Mar 2013 • ISSN No 2277 - 8179

Medical Science

KEYWORDS: Pleomorphic adenoma, minor salivary glands, palate

Pleomorphic Adenoma of the Palate- A Case Report

Dr. Sugandha Sharma	Postgraduate Student, Dept of Oral Medicine and Radiology, KLE VK Institute of dental sciences, Belgaum, Karnataka
Dr. Anjana Bagewadi	Professor, Dept of Oral Medicine and Radiology, KLE VK Institute of dental sciences, Belgaum, Karnataka
Dr. Arvind Shetti	Professor and Head, Dept of Oral Medicine and Radiology, KLE VK Institute of dental sciences, Belgaum, Karnataka

ABSTRACT

Minor salivary gland tumors are a rare clinical entity. Pleomorphic adenoma is a benign salivary gland tumor which commonly occurs in the major salivary glands. Rarely it develops in minor salivary glands of the palate. The diversity of salivary gland tumors as well as their rarity and varied morphological aspects often makes diagnosing such neoplasms difficult. We report a case of a 60 year old female with pleomorphic adenoma of the hard palate. The clinical and histopathological features, differential diagnosis and management of palatal pleomorphic adenoma are discussed.

Introduction

Salivary gland tumors are a relatively rare group of lesions comprising about 1% of all head and neck tumors. These are known for their remarkable morphological and histological diversity.1 Pleomorphic adenoma or benign mixed tumor is the most common salivary gland neoplasm.2 Parotid gland constitutes 60% of all pleomorphic adenomas while minor salivary glands constitute only 8% of them.3

Intraorally pleomorphic adenomas most often occur on the palate, followed by the upper lip and buccal mucosa.4 They can occur at any age, but the highest incidence is in the fourth to sixth decades of life with the mean age of occurrence of 46 years.4, 5 It occurs more frequently in females than in males, the ratio approximating 6:4.6

Case Report

A 60-year-old female patient reported to the Department of Oral Medicine and Radiology, with the complaint of a gradually increasing, painless swelling on the left side of palate since 4 years. The patient's medical history was noncontributory. The patient also gave a history of trauma to the swelling while chewing hard food stuffs resulting in formation of an ulcer over the swelling.

Intraoral examination revealed a solitary dome-shaped swelling measuring about 3 × 3 cm present on the left posterolateral aspect of hard palate. The surface was smooth and the covering mucosa showed an ulcer in the anterior part of the swelling (Figure 1). On palpation, the swelling was firm, nontender, and fixed to the underlying tissues. A panoramic radiograph was taken which revealed no evidence of bone involvement.

Based on history and clinical findings, a provisional diagnosis of minor salivary gland tumor was given. An incisional biopsy of the lesion was performed and histopathologic examination revealed tumor cells arranged in nests, ducts and sheets surrounded by parallel arrangement of collagen fibers suggestive of a capsule. The stroma appeared fibrocellular with eosinophilic and myxomatous areas within (Figure 2). The features were suggestive of pleomorphic adenoma. Surgical excision of the tumor was advised.

Prior to surgical excision, an irreversible hydrocolloid impression of upper arch was made and a cast was prepared (Figure 3) on which a clear acrylic obturator was fabricated (Figure 4). Wide excision of the tumor was done. Figure 5 shows gross appearance of the surgically excised tumor. The surgical obturator was placed over the defect immediately post-operatively (Figure 6). The patient was followed up for a period of 6 months during which satisfactory healing of the surgical site was observed and no evidence of recurrence was noticed.

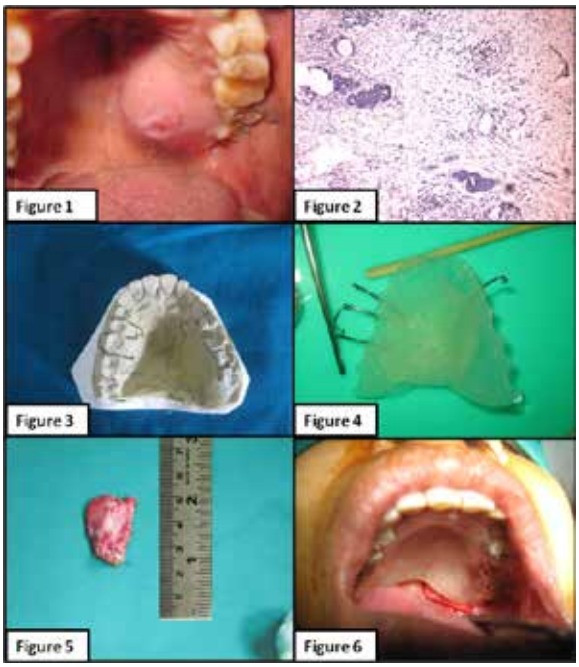

Discussion

Regardless of the site of origin, the pleomorphic adenoma typically appears as a painless, slowly growing, firm mass. The patient may be aware of the lesion for many months or years before seeking a diagnosis.2 When pleomorphic adenoma occurs in the minor salivary glands, the most common site is the palate, followed by the lip, buccal mucosa, floor of mouth, tongue, tonsil, pharynx, retromolar area, and nasal cavity. The palatal pleomorphic adenoma may appear fixed to the underlying bone, but is not invasive. In other sites the tumor is usually freely movable and easily palpated.6 Palatal tumors are almost always found on the posterior aspect of the palate, presenting as a smooth-surfaced, dome-shaped masses.2 If the tumor is traumatized, secondary ulceration may occur as seen in the present case. Pleomorphic adenoma may produce a well-defined saucerlike depression in the underlying bone. In contrast, malignant tumors invade the bone and produce a ragged radiolucent defect with poorly defined borders.7

Differential diagnosis for pleomorphic adenoma affecting palate includes palatine space abscess, adenoid hyperplasia of the minor salivary glands and benign mesenchymal tumors like lipomas, myomas and peripheral nerve tumors (neurofibroma, schwannoma).7, 8 Palatal abscess usually shows signs of pain and inflammation and is associated with a carious tooth. Ad-

enoid hyperplasia of the minor salivary glands is a rare lesion but may clinically mimic pleomorphic adenoma. Lipomas are rare in oral cavity and have a soft consistency. The plexiform neurofibroma is also uncommon intraorally and may be soft and fluctuant.

The gross appearance of pleomorphic adenoma is that of a firm smooth mass within a pseudocapsule. Microscopically they demonstrate combinations of glandular epithelium and mesenchyme like tissue. Myoepithelial cells are also present in this tumor and add to its histopathologic complexity. One characteristic feature of pleomorphic adenoma is the presence of microscopic projections of tumor outside of the capsule.2, 6

Most of the salivary gland tumors although benign in nature may have a great potential to change into malignancy.9 The incidence of malignant transformation of a preexisting pleomorphic adenoma increases progressively with the preoperative duration of the tumor. In the series studied by Eneroth and Zetterberg, the rate of malignant transformation was 1.6% in tumors present for less than five years and 9.4% in tumors present for greater than 15 years.10 A very rare variant, called metastasizing pleomorphic adenoma, is histologically benign, but inexplicably presents with distant metastasis.11

Surgical removal with adequate margins is the principal treatment for pleomorphic adenoma. Due to the presence of microscopic projections, this tumor requires a wide resection to avoid recurrence.4 Tumors of the hard palate are usually excised down to periosteum, including the overlying mucosa. In other oral sites, the lesion often enucleates easily through the incision site. With adequate surgery the prognosis is excellent with a cure rate of more than 95%.2 Recurrence rates range from 0.8% to 6.8%.5 Reasons for recurrence include incomplete excision, seeding, cutting through the microscopic extracapsular projections thereby leaving some tumor behind.12

To control the palatal defect after excision of tumor, surgical obturators have been used which minimize postoperative complications and restore oral function to a reasonable level during the postoperative period. These may be classified as immediate surgical obturators and delayed surgical obturators. An immediate surgical obturator, which was used in the present case, has several advantages which include providing support to the soft tissues, minimizing scar contracture and disfigurement, reproducing the anatomic integrity of the palate, improving postoperative oral hygiene, and protecting surgical packing from food debris contamination.13

Conclusion

Palatal swellings of long duration should raise a high index of suspicion for a minor salivary gland tumor. Though pleomorphic adenoma is a benign neoplasm, emphasis should be placed on early detection and prompt surgical excision as delayed diagnosis increases the risk of malignant transformation. Close post treatment surveillance should be maintained to detect early recurrences.

REFERENCE

1. Saraf S. Disorders of salivary glands. In: Textbook of Oral Pathology. New Delhi: Jaypee Brothers Publishers; 2006: 348-349. | | 2. Neville BW, Damm DD, Allen CM, Bouquout JE. Salivary gland pathology. In: Oral and Maxillofacial Pathology, 2nd ed. Philadelphia: W.B. Saunders company; 2002:406-413. | | 3. Baglam T, Durucu C, Cevik C, Bakir K, Oz A, Kanlikama M. Giant pleomorphic adenoma of the nasal septum. Indian J Otolaryngol Head Neck Surg. 2011 Oct; 63(4):393-5. | | 4. Fox PC, Ship JA. Salivary Gland Diseases. In: Burket LM, Greenberg MS, Glick M, Ship JA. Burket's Oral Medicine.11th ed. USA: B C Decker Inc; 2008:217. | | 5. Peel RL, Seethala RR. Pathology of Salivary Gland Disease. In: Myers EN, Ferris RL. Salivary Gland Disorders. Heidelberg: Springer; 2011: 45-47. | | 6. Rajendran R. Tumors of the Salivary Glands. In: R. Rajendran, Sivapathasundharam B. Shafer's Textbook of Oral Pathology. 5th ed. India: Elsevier; 2006:309-316. | | 7. Wood NK, Goaz PW. Peripheral Oral Exophytic Lesions. In: Differential Diagnosis of Oral and Maxillofacial Lesions. 5th ed. St. Louis: Mosby; 1997: 149-155. | | 8. Byakodi S, Charanthimath S, Hiremath S, Kashalik JJ. Pleomorphic adenoma of palate: A case report. Int J Dent Case Reports. 2011 May:1(1):36-40. | | 9. Bagewadi A, Bhoweer A. Carcinoma in gigantic adenoma of palate- A case report. JIAOMR. 2002; 13(1): 30-33. | | 10. Pilch BZ. Salivary Glands. In: Head and Neck Surgical Pathology. Philadelphia: Lippincott Williams & Wilkins; 2001: 300. | | 11. Klijanienko J, Vielh P, Batsakis JG. Adenomas. In: Salivary gland tumors. Switzerland: S. Karger AG; 2000: 22-23. | | 12. Sharma Y, Maria A, Chhabria A. Pleomorphic adenoma of the palate. Natl J Maxillofac Surg. 2011 Jul; 2(2):169-71. | | 13. Park KT, Kwon HB. The evaluation of the use of a delayed surgical obturator in dentate maxillectomy patients by considering days elapsed prior to commencement of postoperative oral feeding. J Prosthet Dent. 2006 Dec; 96(6):449-53. |