ORIGINAL RESEARCH PAPER

Volume-8 | Issue-1 | January-2019 | PRINT ISSN No 2277 - 8179

INTERNATIONAL JOURNAL OF SCIENTIFIC RESEARCH

POSTOPERATIVE ANTIBIOTICS IN THIRD MOLAR SURGERY: DECONSTRUCTING THE DILEMMA

Dental Science

Dr. Vinay Kumar Sharma*

Senior Resident, Oral and Maxillofacial Surgery Department of Dentistry, Government Medical College and Hospital Chandigarh-160030*Corresponding Author

ABSTRACT

Third molar surgeries are possibly one of the most commonly performed minor oral surgical procedures all over the world. The controversy regarding the potential benefit of postoperative use of antibiotics in these surgeries is still raging on. Numerous authors have provided varying results and evidences. The aim of this research paper was to statistically evaluate the common clinical outcomes in third molar surgeries in a controlled randomized trial and dissect the plethora of evidence available both for and against the use of antibiotics.

KEYWORDS

Third molar surgery, Postoperative antibiotics

INTRODUCTION

One of the most frequently performed techniques in oral surgery is the surgical removal of an impacted mandibular third molar. It is also a fact that most often these surgeries are carried out with local anesthesia onan outpatient basis1. Postoperative complications that have been foundto be the most common are pain, trismus, and swelling. These complications affect the patients' quality-of-life in the first few days postoperatively. Infectious complications in the surgical extractions of mandibular third molars have been reported to range from 1 to 15%. Therefore, they are usually classified under the "clean contaminated" group of surgeries2. Antibiotic use under these situations has been well documented in the literature. Indications include infections caused by susceptible microorganisms that are identified, prophylaxis of clean-contaminated or contaminated surgeries, prevention of infection in immunocompromised patients, and also for the prevention of subacute bacterial endocarditis following intraoral procedures in total joint implantation patients. However, although the third molar surgery is generally considered clean-contaminated and occasionally contaminated surgery, the use of routine antibiotic prophylaxis in patients undergoing such surgeries is considered controversial3. Scientific literature shows that numerous viewpoints have been put forth as a matter of debate, regarding the practice of antibiotic prophylaxis in third molar surgeries. Some authors have discussed that postsurgery complications are due to the trauma of the procedure itself and not due to the infectious events. Therefore, they do not consider antibiotics to be beneficial and so, advocate the use of anti-inflammatory drugs4. It is observed that few authors also recommend the use of antibiotic prophylaxis for considerable reduction in postsurgical complications, such as trismus, pain, delayed wound healing, and swelling, whenever these symptoms are infection related5. Thus, the aim of the present study was to evaluate the effectiveness of different antimicrobial therapies following surgical extraction of an impacted mandibular third molar.

MATERIALS AND METHODS

The present clinical study comprised 40 patients presenting to Government Medical College and Hospital, Chandigarh, India. Patients of ages 20 to 35 years with similar impacted mandibular third molars were included. Patients allergic to penicillin, immunocompromised patients, those suffering from any other systemic disease, as well as pregnant women were excluded. Ethical clearance was taken from the Institutional Ethical Board. Informed consent was also duly obtained from all the participants.

Surgical Procedure

All the patients underwent surgical extraction of the impacted mandibular third molars under strict aseptic techniques. 2% lignocaine with 1:200,000 adrenaline was used to administer the inferior alveolar, lingual, and long buccal nerve blocks. A total of 40 patients were randomly allocated into two study groups comprising of 20 study individuals in each group.

Group I: 625 mg of combined amoxicillin and clavulanic acid tablet for 5 days

Group II: No treatment.

Analgesics were prescribed in both groups. The individuals were examined for postoperative mouth opening (interincisal distance in millimeters) on the 1st, 3rd, 5th, and 7th days postoperatively by a single examiner using Vernier calipers. Postoperative pain was assessed using a 4-point VAS:

0 = No pain
1 = Mild:reported only as response to questioning and without any behavioral signs

2 = Moderate: reported in response to questioning and also accompanied by signs or pain being reported spontaneously without any questioning

3 = Severe: eliciting a strong vocal response or a response that was accompanied by grimaces, withdrawal of the arm, or tears

Analysis of the collected data was done using IBM SPSS version 20.0. Quantitative data were analyzed using t-test, whereas Fischer exact test was used for analysis of qualitative data; $p < 0.05$ was considered as statistically significant.

RESULTS

The present study comprised 20- to 35-year-old patients. There was no statistically significant difference between the mean ages of the two study groups. The severity of pain recorded using VAS score showed no statistically significant differences between the study groups on day 1. However, the number of study individuals with severe pain was observed to be more in both groups. On day 3, the number of study individuals with severe pain was slightly reduced in group I as compared with group II. The pain was completely reduced on the 7th day in both study groups.

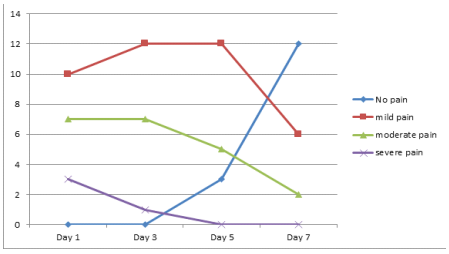

Graph 1: Pain scores in group I

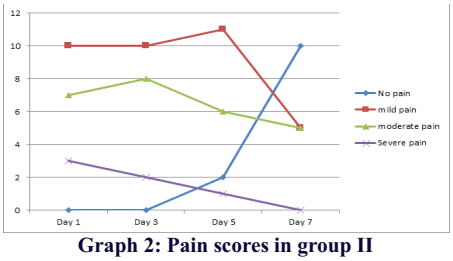

Graph 2: Pain scores in group II

A statistically significant difference in mouth opening was observed between the study groups on days 3 and 5.

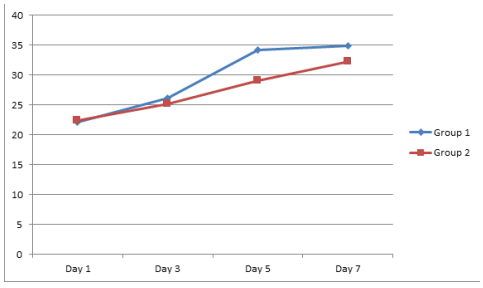

Graph 3: Comparisons of mouth opening between groups I and II

DISCUSSION

With regard to the occurrence of infections following the removal of the third molars, the microorganisms that are most frequently isolated include Streptococci, anaerobic Gram-positive cocci, and anaerobic Gram-negative rods. The antibiotic agent used for effective prophylaxis should be widely distributed in the body fluids, must have good bone penetrance, as well as be active against the microorganisms[6].

The authors observed that many reports in the previously published literature have explored the efficacy of antibiotics in reducing postoperative pain, trismus, and edema. Their results were found to favor aspects, such as an aseptic surgical site and an established technique aiming to minimize trauma7. Within the oral cavity, patient and operative characteristics may influence the risk of development of postoperative infection. It has been widely accepted that age, nutritional status, diabetes, smoking, obesity, coexisting infections elsewhere in the body, colonization with pathogens, and a compromised immune response are the factors that increase the possibility of postoperative infection8. Ness and Peterson 9 have set forth certain criteria when choosing an antibiotic for prophylaxis, advocating prescription of the correct antibiotic with the narrowest antibacterial spectrum. Further, it was recommended that a high enough dosage must be administered at the most appropriate time, with the shortest exposure. In dentistry, the gold standard for the treatment of infections, or as prophylaxis, has been amoxicillin. It has been found to be highly efficacious against Gram-positive Streptococcus and Staphylococcus species, as well as against several Gram-negative bacteria, which are common oral infection isolates10. Factors, such as good absorption in the gastrointestinal tract coupled with the capacity of reaching quick and effective concentrations at the target site are responsible for amoxicillin being the antibiotic of choice11. Trismus that has resulted as a sequel to inflammation settles by itself in time, not needing any intervention. On the contrary, trismus prolongs for a longer duration and, worse still, it may even exacerbate when there is an infection. This complication can be limited by prescribing appropriate antibiotics[12].

When the preoperative and postoperative measurements were compared, in most of the previous studies, the antibiotics which were used postoperatively did not differ significantly in their effects when prescribed for decreased maximal opening of mouth13. The present study shows that there was a statistically significant difference between the study groups with regard to mouth opening, on day 3 and 5. In contrast to the studies done by Sekhar et al14 and Kaczmarzyk et al15 no statistically significant difference was found among the study groups in terms of pain and mouth opening. Therefore, routine prescription and the use of preoperative or postoperative antibiotics during extraction of the third molars fail to show any advantage.

The present study was focused predominantly on the assessment of postoperative clinical infection including its sequelae, namely, pain and mouth opening, and its association with factors, such as the microbial load a the operated site and patient satisfaction. In the present study, there were no cases of active pus discharge or abscess formation requiring incision and drainage. Gram negative bacteria like Pseudomonas and Enterobacteria like Escherichia coli were the major isolates from the aspirates of suture sites. It may be noted that the sample contamination during collection, or further still, the combined use of amoxicillin and clavulanic acid effective against Gram-positive bacteria could be the reason for the presence of Gram-negative bacteria.

Factors, such as less virulent strains of bacteria and low bacterial colony count insufficient to overcome the host resistance to cause infection are sufficient to explain the presence of these Gram-negative bacteria in the absence of infection clinically5. The use of antibiotics in the prophylactic therapy against potential infections has been a conventional practice in third molar surgery. The topic of using antibiotics prophylactically during the third molar surgery has repeatedly been debated16. Various conclusions have been derived so far in this regard, with many found to be conflicting, from the previously conducted randomized controlled clinical trials.

This has resulted in long-established uncertainties, still continuing in clinical practice, among both those for and against antibiotic prophylaxis—each having put forth their respective substantiated documentations17. Postoperative complication occurs due to man factors, while the selection of an appropriate antibiotic is also highly influenced by the type of bacteria present at the operative site. Therefore, selecting the best antimicrobial drug and the time of administration are very important after the extraction of impacted third molars.

CONCLUSION

The present study concluded that there were no significant differences in the degree of postoperative sequelae that occurred following the extraction of impacted mandibular third molar, due to the administration of antimicrobials postoperatively.

REFERENCES

1. Eklund SA, Pittman JL. Third-molar removal patterns in an insured population. J Am Dent Assoc 2001 Apr;132(4): 469-475.
2. Olurotimi AO, Gbotolorun OM, Ibikunle AA, Emeka CI, Arotiba GT, Akinwande JA. A comparative clinical evaluationof the effect of preoperative and postoperative antimicrobial therapy on postoperative sequelae after impacted mandibular third molar extraction. J Oral Maxillofac Res 2014 Apr-Jun;5(2):e2.
3. Soodan KS, Priyadarshni P, Iyeret N, Sharma A, Khajuria V. Prophylactic antibiotics for third molar surgery: an enigma or panacea? IOSR J Dent Med Sci 2014 Aug;13(8):58-61.
4. Poeschl PW, Eckel D, Poeschl E. Postoperative prophylactic antibiotic treatment in third molar surgery-a necessity? J Oral Maxillofac Surg 2004 Jan;62(1):3-9.
5. Arora A, Roychoudhury A, Bhutia O, Pandey S, Singh S, Das BK. Antibiotics in third molar extraction; are they really necessary: a non-inferiority randomized controlled trial. Natl J Maxillofac Surg 2014 Jul-Dec;5(2):166-171.
6. Long MP, Patterson MJ, Murray DL, Kumar A. Cluster causes of septic arthritis caused by Streptococcus pneumoniae in the era of penicillin resistance. Int Paediatr 2000;15:170-173.
7. Martin MV, Kanatas AN, Hardy P. Antibiotic prophylaxis and third molar surgery. Br Dent J 2005 Mar;198(6):327-330.
8. Mangram AJ, Horan TC, Pearson ML, Silver LC, Jarvis WR. Guideline for prevention of surgical site infection, 1999. Hospital Infection Control Practices Advisory Committee. Infect Control Hosp Epidemiol 1999 Apr;20(4):250-278.
9. Ness GM, Peterson LJ. Impacted teeth In: Miloro M, Ghali GE, Larsen PE, Waite PD, editors. Peterson's principles of oral and maxillofacial surgery. 2nd ed. Ch. 8. Ontario: BC Decker; 2004. pp 139-156.
10. Ramu C, Padmanabhan TV. Indications of antibiotic prophylaxis in dental practice-review. Asian Pac J Trop Biomed 2012 Sep;2(9):749-754.
11. Gopee P, Rikhotso E. Impacted mandibular third molars: the efficacy of prophylactic antibiotics and chlorhexidine mouthwash in preventing postoperative infections. SADJ 2017 Jun;72(5):213-218.
12. Rohit S, Reddy BP. Efficacy of postoperative prophylactic antibiotic therapy in third molar surgery. J Clin Diagn Res 2014 May;8(5):ZC14-ZC16.
13. Happonen RP, Bäckström AC, Ylipaavalniemi P. Prophylactic use of phenoxymethylpenicillin and tinidazole in mandibular third molar surgery, a comparative placebo controlled clinical trial. Br J Oral Maxillofac Surg 1990 Feb;28(1):12-15.
14. Sekhar CH, Narayanan V, Baig MF. Role of antimicrobials in third molar surgery: Prospective, double blind, randomized, placebo-controlled clinical study. Br J Oral Maxillofac Surg 2001 Apr;39(2):134-137.
15. Kaczmarzyk T, Wichlinski J, Stypulkowska J, Zaleska M, Panas M, Woron J. Single-dose and multi-dose clindamycin therapy fails to demonstrate efficacy in preventing infectious and inflammatory complications in third molar surgery. Int J Oral Maxillofac Surg 2007 May;36(5):417-422.
16. Zeitler DL. Prophylactic antibiotics for third molar surgery: a dissenting opinion. J Oral Maxillofac Surg 1995 Jan;53(1):61-64.
17. Falconer DT, Roberts EE. Report of an audit into third molarexodontia. Br J Oral Maxillofac Surg 1992 Jun;30(3):183-185.