Volume : 5 | Issue : 4 | April 2016 • ISSN No 2277 - 8179 | IF : 3.508 | IC Value : 69.48

Practices Promoting Bladder Neck Opening in Voiding Cystourethrogram

Medical Science

KEYWORDS : VCUG, bladder neck, stricture urethra, Silodosin.

SATINDER PAL AGGARWAL	M.S., SMS MEDICAL COLLEGE AND HOSPITAL, JAIPUR, INDIA
VINAY TOMAR	MCh, SMS MEDICAL COLLEGE AND HOSPITAL, JAIPUR, INDIA.
Sher Singh YADAV	MCh, SMS MEDICAL COLLEGE AND HOSPITAL, JAIPUR, INDIA.
Shivam Priyadarshi	MCh, SMS MEDICAL COLLEGE AND HOSPITAL, JAIPUR
RAM DAYAL TELI	MCh, SMS MEDICAL COLLEGE AND HOSPITAL, JAIPUR
DEEPAK JAIN	MCh, SMS MEDICAL COLLEGE AND HOSPITAL, JAIPUR, INDIA.

ABSTRACT

Delineation of proximal urethra in voiding cystourethrogram (VCUG) in stricture urethra provides an anatomical road map for surgery. Aim of this study is to evaluate role of suprapubic pressure, forward tilting head end of fluoroscopy table and Silodosin in opening bladder neck in VCUG. A randomized placebo controlled prospective study of 182 stricture urethra patients from November 2014 to June 2015 was conducted. 94 patients (50.6%), who did not open their bladder neck spontaneously, did not respond either to suprapubic pressure or table tilting. Out of 46 patients, on placebo, only 8 patients (17.4%), while out of 48 patients on Silodosin, 42 patients (87.5%) opened their bladder neck (p<0.0001). There was no difference in response to Silodosin in PFUDD, penile or bulbar strictures (p=0.33).

Introduction

Cystourethrogram is cornerstone for evaluation of stricture urethra as anatomy provides a road map for surgery. Voiding cystourethrogram (VCUG) gives us information about the proximal limit of stricture, thus helps in estimating total length of stricture and hence in surgical planning. For proper visualization of proximal urethra, bladder neck must open to allow passage of contrast into the proximal urethra. However bladder neck remains closed in significant number of VCUG. In these situations one has to embark on other methods such as antegrade scopy, bougegram or MRI study for evaluation of proximal urethra [1-3].

There is no study in current literature, analyzing role of suprapubic pressure and upward tilt of head on bladder neck opening. We have conducted this study with the aim to evaluate role of surapubic pressure, upward tilting of head end of the fluoroscopy table and Silodosin on bladder neck opening in VCUG. Logic for applying suprapubic pressure was to increases intravesical pressure (as in crede's maneuver) and thus overcoming bladder neck resistance. Upward tilting of head end of fluoroscopy table provides more natural voiding position than supine position and gravity may help in opening bladder neck. α blocker acts on α1 receptors on bladder neck and help in opening the bladder neck. Silodosin has the advantage of having highly selective α1A receptor blocker and early onset of action (2.4 hours)[4].

Material & Methods

After institutional ethics committee clearance, this randomized double blind placebo controlled prospective study was conducted between November 2014 and June 2015 in 182 male stricture urethra patients requiring VCUG. Exclusion criterion were age <18 years, >60 years, neurogenic bladder, history of bladder neck surgeries like bladder neck repair, bladder neck incision, urethrocutaneous fistula, incompetent bladder neck (funnel shaped bladder neck on filling), urinary tract infection (UTI), contrast allergy and on chronic use of alpha blockers or anticholinergics. Study design is shown in fig 1.

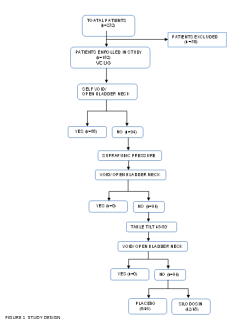

After retrograde urethrogram (RGU), VCUG was performed in supine position by filling the bladder with diluted contrast medium (made by 76% sodium diatrizoate with normal saline in the ratio of 1:3) by gravity drip method through an indwelling suprapubic catheter (SPC) or retrogradely via infant feeding tube (in those cases where SPC was not in place) under sterile conditions. When the patient felt the desire to void, bladder filling was stopped, amount of contrast used was noted and command to void was given. VCUG was done under fluoroscopy following "as low as reasonably achievable" (ALARA) principle. A patient who was not able to open their bladder neck spontaneously, suprapubic pressure was applied. Those who still were not able to open their bladder neck, head end of fluoroscopy table was tilted upwards (45º- 50º).

Patients who still failed to open their bladder neck after these maneuvers, were randomly divided by random code generator into Group 1 of 46 patients, who were given placebo and group 2 of 48 patients, who were given Silodosin 8 mg. Radiographer was assigned the work to give placebo or Silodosin, so that both

person performing VCUG and patient were blind for the drug given. Repeat fluoroscopic guided VCUG was done 3 hours after taking the medicine by filling bladder again, to study effect of Silodosin and placebo on bladder neck opening. Blood pressure of patients was monitored for hypotension. After procedure, Levofloxacin 500 mg for 3 days was given.

Statistical analysis was performed using SPSS version 22 software. The results are expressed as means and confidence intervals for continuous variables and as percentages for categorical variables. Comparative analysis was done using Chi square test. A p value <0.05 was considered to indicate statistical significance.

Results

Demographic data of 182 patients who underwent VCUG is shown in table 1.

TABLE 1 DEMOGRAPHIC DATA

VARIABLES	VCUG (n=182)	p value*
AGE (years)	34.36(32.6-36.1)	0.28
BMI	24.04 (23.5-24.5)	0.22
ETIOLOGYN		
TRAUMA	104(57.1%)	
POST CATHETERIZATION	36(19.8%)	
INFLAMMATORY	22(13.2%)	
BXO	20(10.9%)	
SITE OF STRICTURE		
PFUDD	76(41.8%)	
PENILE	64(35.2%)	
BULBAR	42(23.1%)	
NUMBER OF PATIENTS WITH SPC	95(52.19%)	0.08
DURATION OF SPC (months)	2.06 (1.9-2.3)	
VOLUME OF DILUTED CONTRAST (ml)		<0.0001
<200 ml	56(30.7%)	
>200 ml	126(69.3%)	
BLADDER NECK OPENED SPONTANEOUSLY	88(49.4%)	
ETIOLOGY		0.41
TRAUMA	46/104(44.2%)	
POST CATHETERIZATION	16/36(44.4%)	
INFLAMMATORY	14/22(63.6%)	
BXO	12/20(60%)	
SITE OF STRICTURE		0.27
PFUDD	34/76(44.7%)	
PENILE	38/64(59.4%)	
BULBAR	16/42(38.1%)	
BLADDER NECK OPENED ON SUPRAPUBIC PRESSURE	None	
BLADDER NECK OPENED ON TABLE TILT (45 – 50°)	None	
BLADDER NECK OPENED AFTER PLACEBO	8/46(17.4%)	
BLADDER NECK OPENED AFTER SILODOSIN	42/48(87.5%)	<0.0001
SITE OF STRICTURE (EFFECT OF SILODOSIN)		
PFUDD	16/18(88.8%)	0.33
PENILE	12/16(75%)	
BULBAR	12/14(85.7%)	
S/E DUE TO SILODOSIN	None	
POST VCUG FEVER	3 (0.01%)	

* Chi square test

95 patients (52.19%) had SPC in situ with mean duration of 2.06 months (SD 0.91). There were 76 PFUDD (41.8%), 64 bulbar (35.2%) and 42 penile (23.1%) strictures.

88 patients (49.4%) opened their bladder neck spontaneously. Age (p =0.28), BMI (p= 0.22), etiology (p=0.41), presence or absence of suprapubic catheter (SPC) (0.08) and site of stricture (0.27) did not impact opening of bladder neck in our study. Mean volume of diluted contrast used was 274.95 ml (SD 76.27).126 patients had > 200 ml volume of diluted contrast filled for study and 90 opened bladder neck spontaneously, as compared to none in 56 patients with less than 200 ml diluted contrast used (p <0.0001).

94 patients (51.6%) failed to open their bladder neck spontaneously (fig 2, 3a). None of these patients responded to surapubic pressure or table tilting.



fig 2 RETROGRADE URETHROGRAM





fig 3a VOIDING CYSTOURETHROGRAM WITH CLOSED BLADDER NECK fig3b VOIDING CYSTOURETHROGRAM WITH OPEN BLADDER

Out of 46 patients, who were given placebo, only 8 patients (17.4%) opened their bladder neck, while out of 48 patients on Silodosin, 42 patients (87.5%) voided (p<0.0001)(fig 3b). There was no difference in response to Silodosin in different sites of stricture (p=0.33) (fig 4).

Fig 4 bar diagram showing effect of Silodosin and placebo in opening bladder neck in various stricture types

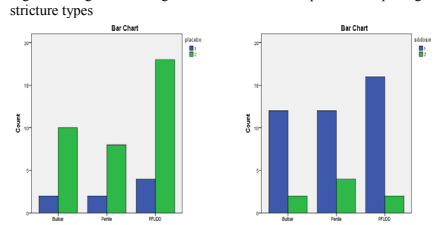

1 MEANS YES
2 MEANS NO

None of the patient reported any drug related side effect due to Silodosin. 3 patients (0.01%) developed fever after study, which was managed with broad spectrum antibiotics.

DISCUSSION

For management of stricture urethra, location and length of stricture plays primary role in deciding type of surgical procedure. Retrograde and voiding cystourethrogram are the traditionally primary mean of evaluation. RGU and VCUG are the imaging study, surgeon most accustomed and comfortable with. But a significant number of patients didn't open their bladder neck on VCUG, thus incomplete evaluation of stricture. In our study, 51.6% patients did not open their neck on VCUG. This situation forces surgeon to evaluate proximal limit of stricture by other measures such as bougegram, antegrade scopy (both are invasive procedures) or MRI (a costly and less accustomized imaging for surgeon) [1-3]. Adequate VCUG is important preoperative tool in planning of stricture surgery, while other more invasive procedures are usually done prior to definitive surgery.

We arbitrarily fixed 200 ml as the minimum amount of fluid required for detrusor contraction in adult male. >200 ml diluted contrast must have been able to contract detrusor muscle more effectively than <200 ml diluted contrast, leading to bladder neck opening in significant amount of patients.

Upward tilting of table provides more natural and comfortable position for voiding. However in our study, it did not impact opening of bladder neck. Suprapubic pressure in adults might not be effective due to well-developed abdominal musculature.

Volume : 5 | Issue : 4 | April 2016 • ISSN No 2277 - 8179 | IF : 3.508 | IC Value : 69.48

Silodosin, an alpha adrenoreceptor blocker, has been used for management of BPH. Silodosin has rapid onset of action (within 2.6 hours) and higher affinity for α 1A receptors on bladder neck than other α blockers[4]. Being highly selective and fast acting, VCUG can be performed same day after giving Silodosin. Silodosin have minimal cardiovascular side effects, therefore it is also preferred in old age patients[5]. Silodosin can cause postural hypotension, but in our study none patient develop hypotension on BP monitoring.

There are few studies on effect of α blockers on bladder neck opening in VCUG. Nandan R Pujari conducted a placebo controlled prospective randomized trial in 2013, comparing Tamsulosin 0.4 mg with placebo in opening bladder neck in MCU study in PFUDD patients[6]. In their study, all the patients of Tamsulosin group were able to open their bladder neck whereas none in placebo group. Similarly, Nagathan DS et al demonstrated affectivity of Silodosin in opening bladder neck in PFUDD patients [7]. In their study 28 patients out of 40 (70%) opened their bladder neck spontaneously, whereas 34 patients out of 76 PFUDD patients (44.7%) opened their bladder neck spontaneously in our study. In their study, 12 PFUDD patients were given Silodosin 8 mg and VCUG was done after 3 hours and 10 patients (83.3%) opened their bladder neck. Similarly in our study 16 out of 18 PFUDD patients (88.8%) open their bladder neck after giving Silodosin.

8 patients (17.4%) out of 46 that were put on placebo opened bladder neck. It may be because of resolution of performance anxiety on second attempt.

Blind ending strictures like PFUDD, as well as, penile strictures cannot be fully evaluated with RGU only. Urethra proximal to penile stricture may not fully dilate on RGU, due to less amount of contrast flowing proximal to stricture, thus overestimating stricture length. This limitation of RGU can be overcome by visualization of proximal urethra on VCUG. Both previous studies were done in PFUDD patients only, while our study included PFUDD, bulbar and penile strictures. So far role of α blockers in VCUG was evaluated only in cases of PFUDD. Our study includes other strictures also. 88.7% PFUDD, 75% penile and 85.7% bulbar strictures opened their bladder neck in respond to Silodosin, while only 0.17% PFUDD, 0.2% penile and 0.17% bulbar strictures responded to placebo. Our study is the first study that clearly shows that Silodosin can be effectively utilized in stricture other than PFUDD during VCUG.

Our study clearly demonstrated that suprapubic pressure and table tilting have no effect while Silodosin is effective in opening bladder neck in stricture patients during VCUG studies. We recommend giving Silodosin before VCUG for proper evaluation of stricture length and thus help in pre-operative planning, avoidance of invasive procedures.

Limitations of our study are that it is a single center study and upward tilt of head end was limited to 45 degree.

CONCLUSION

We recommend a single dose Silodosin 8 mg 3- 4 hours before VCUG study in stricture urethra patient for visualization of proximal urethra**.** Single dose Silodosin is safe and helps in avoiding invasive procedures for evaluating proximal urethra in significant number of cases.

BIBLIOGRAPHY

1) Goel MC, Kumar M, Kapoor R. Endoscopic management of traumatic posterior urethral stricture: Early results and follow-up. J Urol 1997 ; 157:95-7.
2) Sung DJ, Kim YH, Cho SB, et al. Obliterative urethral stricture: MR urethrography versus conventional retrograde urethrography with voiding cystourethrography. Radiology. 2006;240:842-8.
3) Goel A, Gupta A, Dalela D. Antegrade urethrogram: A technique to visualise the proximal bulbous urethral segment in anterior urethral stricture. Indian J Urol. 2009; 25:415-6.
4) Rossi M, Roumeguere T. Silodosin in the treatment of benign prostatic hyperplasia. Drug Des Devel Ther. 2010 ; 4:291-7.
5) McNicholas TA, Kirby RS, Lepor H. Evaluation and Nonsurgical Management of Benign Prostatic Hyperplasia.In: Kavoussi LR, Novick AC, Partin AW, Peters CA,eds. . Campbell - Walsh urology. 10th ed. Philadelphia,Pa: Saunders, 2012 ; 2611–2694.
6) Pujari Nandan R, Kulkarni Sanjy B. The use of tamsulosin in voiding cystourethrogram for pelvic floor urethral distraction injuries. UroToday Int J. 2013 August ;6(4):art 42.
7) Deepak Sharanappa Nagathan, Divakar Dalela etal. Single Dose Silodosin Prior to Voiding Cystourethrogram: A Pharmacological Adjunct to Enhance Visualization of Posterior Urethra. Urology journal. 2014;11