ORIGINAL RESEARCH PAPER

Volume-7 | Issue-4 | April-2018 | PRINT ISSN No 2277 - 8179

INTERNATIONAL JOURNAL OF SCIENTIFIC RESEARCH

PRENATAL DIAGNOSIS ADRENAL NEUROBLASTOMA: CASE REPORT

Radiodiagnosis

Dr. Rajasbala Dhande* Professor,Department of Radio-diagnosis, Jawaharlal Nehru Medical college, Sawangi[Meghe] , Wardha , Maharashtra, India-442001*Corresponding Author

Dr. Sakshi Daga Resident, Dept. of Radio-diagnosis, Jawaharlal Nehru Medical College, Sawangi (Meghe), Wardha, Maharashtra, India - 442001.

ABSTRACT

This article reviews a case of right retroperitoneal mass detected in fetus on ultrasound at 37 weeks of gestation. Post natally ultrasound and CT was performed. The neonate was later operated. Histopathological examination confirmed the diagnosis of adrenal neuroblastoma.

KEYWORDS

Retroperitoneal Mass, Ultrasound, Ct , Histopathological , Adrenal Neuroblastoma.

INTRODUCTION:

Evaluation of fetal urogenital tract is an essential part of obstetric ultrasound examination. Accurate Prenatal diagnosis of urogenital anomalies may alter the obstetric management and facilitate immediate post-natal treatment.[1] Neuroblastoma is the most common extracranial solid malignant tumor of infancy . In more than 90 % cases the most common origin of fetal neuroblastoma is adrenal gland.[2]

CASE PRESENTATION:

A 27 yrs old healthy primigravida came for routine third trimester antenatal ultrasound examination at our hospital with previous two antenatal ultrasound scan done in first and second trimester respectively being normal. The detailed ultrasound examination revealed a retroperitoneal hypoechoeic mass of approximate size 6.5 x 3.4 cm noted on right side. The mass was abutting right kidney anteriorly with mild dilatation of its pelvi-calyceal system. Few calcification of approximate size 1mm were seen in mass. [FIGURE1]On color Doppler vascularity was noted within the mass [FIGURE 2].

Left kidney was normal in size shape and echotexture. No other fetal structural abnormalities were seen. The possibility of neuroblastoma was kept. A healthy male fetus weighing 3180 kg was delivered by full term normal delivery. Apgar scrore was 8/10 at 1 min ,9/10 at 5mins and physical examination was normal.

Post natal ultrasound was performed revealing adrenal tumour of size .Plain and contrast enhanced CT of abdomen and pelvis was obtained.CT findings showed a large well defined heterogeneously enhancing lesion in retroperitoneum on right side in the right paravertebral region measuring approximately 7.4 x 4.1 x 4 cm. The right adrenal gland was not seen separately from lesion. Medially the mass was extending across midline at level of D11 posterior to aorta , displacing it anteriorly . No evidence of extension into interverterbral neural foramina was seen. Laterally the lesion was causing displacement of right kidney postero-laterally which showed moderate hydronephrosis with parenchymal thickness measuring 5.2 mm, 3.2 mm, and 6.1 mm at upper, mid and lower pole respectively. [FIGURE3]

The lesions was extending from levels of T9 vertebral level superiorly upto the level of L4 vertebra inferiorly. Anteriorly the lesion was abutting the caudate lobe of liver with maintained intervening fat planes superiorly and displacing bowel loops inferiorly . Left adrenal gland was normal without any focal lesion within it. Rest of the abdominal organs were normal in morphology and attenuation pattern. Visualized lung bases appeared normal. Possibility of right adrenal neuroblastoma was raised.

[FIGURE 1]



[FIGURE 2]

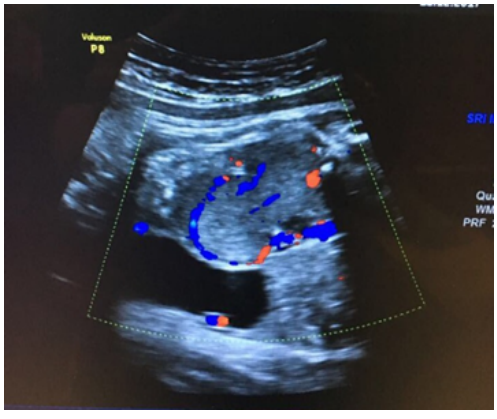

[FIGURE 3]

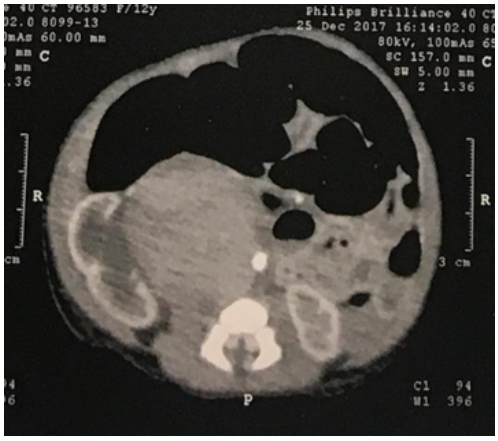

Neonate was later operated. Histopathological finding confirmed the diagnoisis. Histopathological findings showed presence of small, round tumor cells arranged in a diffuse pattern. Cells were separated by delicate septae and neutrophils were seen in between the cells. Rosettes were seen at places. Cells contained hyperchromatic nuclei with indistinct nucleoli.

DISCUSSION

Neuroblastoma is a poorly differentiated tumor arising from primordial neural crest cells and is one of the most common malignant tumour of infancy. The widespread use of prenatal obstetric ultrasound has helped in accurate diagnosis and therapeutic management of such tumours.[3]

Adrenal neuroblastoma although is a most common suprarenal malignancy, the other differential includes adrenal haemorrhage, extrapulmonary sequestrartion , bronchogenic cyst or uropathy. The diverse appearance of adrenal neuroblastoma on ultrasound vary from solid with or without calcification , cystic and mixed variety comprising of both solid and cystic components.cystic neuroblastomas have better prognosis of all other neuroblastoma. Ultrasound delineates the exact localization , size and features of tumor and search for metastasis. Colour Doppler shows diffuse vascularity within the tumour. Follow up ultrasound helps in monitoring the size of tumour , its extent and detecting metastatic complications.[4]

After ultrasound , axial imaging studies such as CT or MRI can be performed to assess the exact location and size of tumour , staging for tumour resectability and metastatic work up. On CT or MRI neuroblastoma appear as a heterogenous solid mass crossing midline , causing vascular encasement and displacement of adjacent organs. Presence of stippled calcification is seen in 85% cases of neuroblastomas.[5]

Various classification systems are used for neuroblastoma tumors which include Shimda classification, modified form of Shimda classification was renamed as International neuroblastoma pathology classification system [INPC] and International neuroblastoma staging system[INSS]. INPC further divided neuroblastoma into three subtypes :undifferentiated , poorly differentiated and differentiating.[6]

The treatment of neuroblastoma is based on International NBL risk grouping system which is based of age, stage and selected biological system. The treatment options include surgery or chemotheraphy followed by surgery. Follow up with help of ultrasonography and other imaging modalities helps in monitoring tumor regression or acceleration , metastatic work up and any other associated complications.[7]

REFERENCES:

1. Hindryckx A, De Catte L. Prenatal diagnosis of congenital renal and urinary tract malformations. Facts, views & vision in ObGyn. 2011;3(3):165.
2. Cho JY, Lee YH. Fetal tumors: prenatal ultrasonographic findings and clinical characteristics. Ultrasonography. 2014 Oct;33(4):240.
3. Jennings RW, LaQuaglia MP, Leong K, Hendren WH, Adzick NS. Fetal neuroblastoma: prenatal diagnosis and natural history. Journal of pediatric surgery. 1993 Sep 1;28(9):1168-74.
4. Erol O, Süren D, Büyükkınacı Erol M. Prenatal diagnosis of adrenal neuroblastoma: a case report with a brief review of the literature. Case reports in obstetrics and gynecology. 2013;2013.
5. Kembhavi SA, Shah S, Rangarajan V, Qureshi S, Popat P, Kurkure P. Imaging in neuroblastoma: An update. The Indian journal of radiology & imaging. 2015 Apr;25(2):129.
6. Omoseebi O, Odubanjo MO, Akinde OR, Ikeri NZ, Ademuyiwa AO, Adeyomoye AA. Neonatal neuroblastoma with adrenal primary and metastasis to the liver: A case report and a review of literature. African journal of paediatric surgery: AJPS. 2016 Oct;13(4):217.
7. Papaioannou G, McHugh K. Neuroblastoma in childhood: review and radiological findings. Cancer Imaging. 2005;5(1):116.