ORIGINAL RESEARCH PAPER

Volume-8 | Issue-1 | January-2019 | PRINT ISSN No 2277 - 8179

INTERNATIONAL JOURNAL OF SCIENTIFIC RESEARCH

PRIMARY BONE LYMPHOMA REVEALED BY COMPLICATION: TWO CASES REPORT

Orthopedics

Sid'Ahmed Mohamed Limam* Unit of orthopedic & trauma surgery – Cheikh Zayed's Hospital- Nuakchott- Mauritania *Corresponding Author

Erebih Cheikh Elmoustapha Trauma orthopedic and major burns center- Nuakchott- Mauritania

Mohamed Kah Trauma orthopedic and major burns center- Nuakchott- Mauritania

Habib Nouri Mediterranean clinic- Tunis- Tunisia

KEYWORDS

Bone lymphoma, Surgery, Pathological fracture

1- Background:

Primary bone lymphoma (PBL) is a rare manifestation of non-Hodgkin lymphomas (NHL), accounting for less than 1 % of all cases of malignant lymphomas and 3- 15 % of extra-nodal non-Hodgkin lymphomas, but only 3% of malignant bone tumors [1] [2] [3] [4] [7] [8].

Diffuse large B-cell lymphoma (DLBCL) is the most common pathological type, representing over than 80 % of PBL [2] [4] [7].

The aim of this paper is to report two new cases of PBL and to show the good response after surgery, chemotherapy and radiotherapy. And to show the good outcome.

2- Cases reports:

First case: A 50-years- female presented with history of fever, generalized weakness and right knee pain for 2 months. On physical examination she was pale and febrile. Local examination of the right knee found swelling and pain of distal end of femur. X-ray and CT scan of right knee showed lytic areas involving the lower end of distal femur, with pathological supracondylar fracture (**figure 1**). MRI showed a devastating involvement of soft tissues (**figure 2**). The extension assessment showed a lytic lesion on D8. Biopsy showed small round cell tumor. Immunohistochemistry (IHC) showed massive positivity for CD 20, Bcl-2 and Bcl-6. Final diagnosis was diffuse large B cell lymphoma (DLBCL), staged as Ann Arbor stage II, because of spinal localization (**figure 3**). Curettage with fixation buy DCP (dynamic compression plate) of the pathological fracture was made. Postoperative regimen was R-CHOP (Rituximab, Cyclophosphamide, Hydroxy dauno-rubicine, Vincristine and Prednisolone), followed by radiotherapy.

At follow-up of 20 months; she walks without crutches with slight limp. Ossification of distal femur was obtained (**figure 4**), healing of soft tissues proliferation, but stiffness of knee in flexion was observed.

Second case: A19-years- man admitted to emergency because of acute dorsal pain. On examination:

He was febrile with sphincters disorders and paraplegia. MRI showed sclerotic lesion of D7 with epidural lesion, epidural thinking, filling of the spinal canal, compression of the dural sheath (**figure 5**). Diagnosis of acute spinal cord compression was made and spinal cord decompression was performed with biopsy, Histopathological features found a small cell proliferation. IHC showed large positivity with CD 20, CD 10 and Bcl-6. Ki67 marked 90 % of cellular population. The final diagnosis was high grade B lymphoma Burkitt's type (**figure 6**). After surgery chemotherapy with R-CHOP and radiotherapy was followed.

At 11 months postoperative; he is pain free, he walks without crutches and complete nerve recovery was noted (**figure 7**).

3- Discussion:

Primary bone lymphoma (PBL) is a lymphoma localized to the bone with no evidence of disease elsewhere for at least six months after diagnosis (Coley 1950) [1].

Parker & Jakson reported the first case series of PBL, in 1939; named reticulsarcoma [3] [4].

PBL remains rare, complicated PBL is rarest between diagnosed cases. Often described in the literature as clinical case [7] [8] [10] [11] [14] [16].

Predominance of male is commonly seen: Jamshidi: 1, 3: 1 [7] and Kenen Bayrakci [4]

The peak incidence for the presentation is in the Fifth and sixth decades mean age at presentation of 44 years [3].

PBL occurs in almost every bone. But long bones of the lower limb, especially the femur are the most common site according to the literature. The second most common site is the spine. That we have seen in our two cases: one on the distal femur, the other in the spine [1] [7].

On the long bones; the involvement of metaphysis is more common than diaphysis and epiphysis [15].

The radiological aspects are variables from near-normal-appearing bone to diffusely permeative process with cortical destruction and soft tissue Involvment [15].

The histological type most seen is B-lymphoma [2]. In the small biopsy specimens malignant lymphoma may be impossible to differentiate from Ewing sarcoma and undifferentiated small cell carcinoma; this mistake can led to misdiagnosis with worse prognosis [3].

Chemotherapy and Radiotherapy remain the cornerstones of treatment of all lymphomas, even if surgery does in some cases like fails of radiotherapy and chemotherapy to halt growth of tumor, it become necessary in complications: pathological or impending fractures (as occurred in our first case), vertebral involvement with neurological complications (as occurred in our second case). Surgical ablation for local disabling necrosis can also be required. Little is reported about surgical procedures in PBL [4] [5].

Pathological fracture is reported in 10 – 43 % of series. His presence was found to be a negative prognostic factor by some authors but this finding wasn't confirmed by others [3]. In our first case we found good functional outcome and good local control of the tumor.

Early surgical treatment before starting of chemotherapy, allowed a much higher quality of life for the patient during subsequent treatment [3] [4].

4- Conclusion:

PBL is a rare but curable cancer, diagnosis is suspected on clinical and morphological aspects. Pathology with Immunohistochemistry confirms the diagnosis. Association chemotherapy- radiotherapy is the gold standard of treatment. Surgery is indicated in complications; surgical treatment should aim to restore function and eliminate pain while minimising potential delays in chemotherapy initiation.

Conflicts of interest: there are no conflicts of interest relating to this paper.

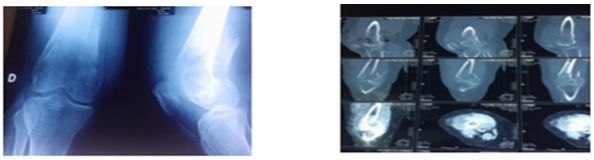

a b

Figure 1: a- X-Ray: lytic lesion with b- CT-scan on distal femur pathological fracture

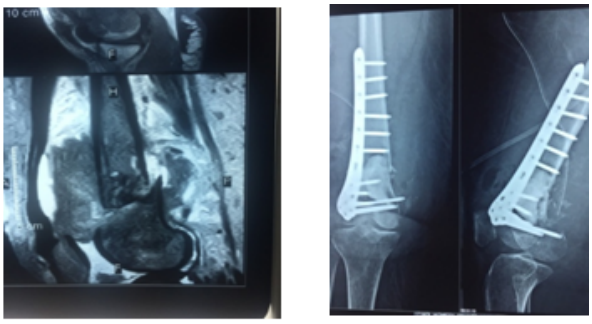

a b

Figure 2:

a- MRI of distal femur showing huge tumor with involvement of soft tissue

b- Postoperative x-ray showing fixation by DCP with cement.

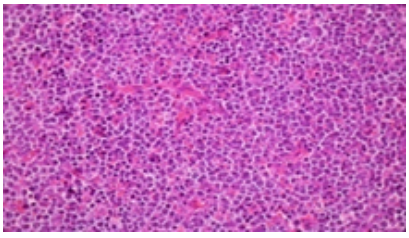

Figure 3: pathologic features of case 1



Figure 4: ossification of distal femur and good integration of the hardware.

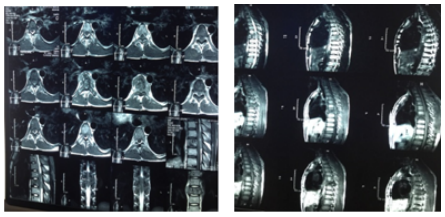

Figure 5: MRI of second case showing condensing lesion of D7 with epidiritis

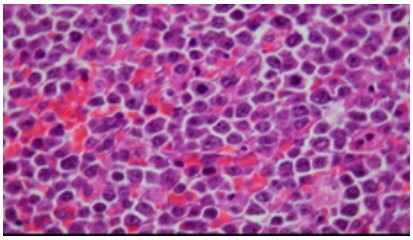

Figure 6: pathologic features of second case

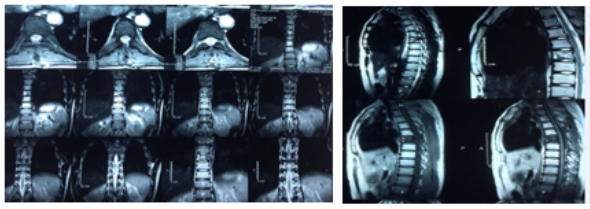

Figure 7: second case's MRI at latest follow-up with healing of epidiritis.

REFERENCES:

1- Faiza Lazrak, Latifa Tahiri, Rahma Boussaadani Soubai, Hicham Hachimi and Taoufiq Harzy: The primary bone multifocal lymphoma: A case report Rev Mar Rhum 2013; 25: 42-4

2- Yao-chuung liu, Jy-pyng Gau, Yuan-Bin Yu, Ying-Chung Hong and al. Prognostic factors and treatment efficacy in patients with primary diffuse large-B cell lymphoma of the bone: Single Institute Experience over 11 years. Intern Med 53: 95-101, 2014. (DOI 10.2169\internalmedicine.53.0967)

3- Kenan Bayrakci, Yusuf Yildiz, Yener Saglik, Murat Altay, Hamit Ogut, Mustapha Samur, Salim Erekul: Primary lymphoma of Bone International Orthopedics (SICOT) 2001 25: 223-226 DOI 10.1007\ s002640100224 Guido Soccianti, Luigi Rigacci, Benedetta Puccini, Domenico Andrea Campanacci, Gabriele Simontracchi, Alberto Bossi, Rodolfo Capanna International Orthopedics (SICOT) 2013 37: 2437-2442 DOI 10.1007\ s00264-013- 2055-6

4- Huanwen Wu, Marilyn M Bui, Douglas G Leston, Haipeng Shao, Lubomir Sokol, Eduardo Sotomayor and LImg Zhang : clinical characteristics and prognostic factors of Bone lymphomas: Focus on the clinical significance of multifocal Bone involvement by primary Bone large-B Cell lymphomas BMC Cancer 2014 14 : 900

5- Hiroko Nishida, Masao Hori and Katsuyuku Obara Primary isolated bone marrow diffuse large B-cell lymphoma with the initial presentation as severe thrombocytopenia, successfully treated with chemotherapy: as case report and review of the literature Journal oh Therapeutics & Research 2012 ISSN 2049-7962 DOI 10.7243\2049-7962 – 1- 28

6- Khodamorad Jamshidi, MD, Mahmoud Jabalameli, MD, Mohammad Ghorban Hoseini, MD, Abolfazl Baghrifard, MD Arch Bone Jt Surg. 2015 ; 3(1) 39-44

7- Kathryn Beal, MD, Laura Allen MD, Joachim Yahalom MD. Primary bone lymphoma: Treatment Results and Prognostic Factors with Long-Therm Follow-Up of 82 patients' cancer 2006; 106: 2652-6. American Cancer Society. DOI 10.1002| cncr.21930

8- E. Belembaogo, J. Bouguikouma, J. Moussavou-Kombila et al. Lymphome osseux primitif révélé par une fracture pathologique Médecine d'Afrique Noire 1997, 44 (5)

9- Monika Gupta, Shalini Shah, Nisha Marwah, Mega Kathuria, Sonia Chhabra, Rajjev Sen. Primary bone marrow B-cell lymphoma : Correlation of Results of Flow Cytometry and Morphological Findings. J Hematol.2015; 4(4) : 242-245

10- Tejinder Singh et al. Primary bone lymphoma: A Report of two Cases and review of the literature. J of Cancer research and Therapeutics- July- September 2010- volume 6- Issue 3

11- Hai Yan Zhou et al. Primary bone lymphoma: A Case Report and review of the literature. Oncology letters 8 : 1551-1556, 2014

12- Provost M al. 65eme congres de la SFCO, 02003 (2017) DOI 10,1051/ sfco/20156502003

13- Xuan Ye Zhang et al. clinical characterization and outcome of Primary bone lymphoma: A retrospective study of 61 Chinese patients Scientific Reports|6: 28834| DOI 10.1038\srep28834

14- Anant Krishnan et al. Primary bone lymphoma: Radiographic MR Imaging Correlation RadioGraphics 2003; 23: 1371-1387. Published online 10.1148\rg.236025056