Volume : 5 | Issue : 3 | March 2016 • ISSN No 2277 - 8179 | IF : 3.508 | IC Value : 69.48

Research Paper

Primary Glioblastoma Multiforme in Pineal Region: A Case Report

Medical Science

KEYWORDS : brain tumor, pineal gland, glioblastoma multiforme

Dr Mukesh P Patel	Proffessor and Head of department, Department of neurosurgery, Smt NHL municipal medical college, V.S. hospital Ahmedabad
Dr Kalpesh B Shah	Associate Proffessor, Department of neurosurgery, Smt NHL municipal medical college, V.S. hospital Ahmedabad
Dr Anish Kumar Goyal	Third year Neurosurgery Resident, Smt NHL municipal medical college, V.S. hospital Ahmedabad
Dr Nilay Adhvaryu	Third year Neurosurgery Resident, Smt NHL municipal medical college, V.S. hospital Ahmedabad
Dr Sandip Patel	Second year Neurosurgery Resident, Smt NHL municipal medical college, V.S. hospital Ahmedabad
Dr Dinesh tiwari	Second year Neurosurgery Resident, Smt NHL municipal medical college, V.S. hospital Ahmedabad

ABSTRACT

Introduction: Glioblastoma multiforme in the pineal region is extremely rare with only a few cases reported in the literature.

Case: 43 year old man presented with severe headache, vomiting, blurring of vision and gait disturbances. Magnetic resonance imaging of the brain showed a heterogeneously enhanced tumor in the pineal region with obstructive hydrocephalus. After an urgent ventricular-peritoneal shunt, this mass was subtotally removed and diagnosed as a glioblastoma multiforme. Thereafter the patient was recommended to undergo radiotherapy and chemotherapy.

Conclusion: Although glioblastoma multiforme is rare in pineal region, it should be considered in the differential diagnosis due to available treatments and prognosis.

Introduction

The pineal region consists of the pineal body, the posterior wall of the third ventricle, tela choroidea and velum interpositum. Despite its small size, a wide variety of brain tumors can arise in the pineal region. Tumors of the pineal region may be of pineal parenchymal origin, extragonadal germ cell origin and neuroglial origin. Approximately 11-28% and 50-75% of tumors in the pineal region are pineal parenchymal tumors and germ cell tumors, respectively [1]. In addition, glioma, meningioma and mesenchymal tumors are encountered occasionally. Glioblastoma, which is the most malignant and frequent glioma in brain tumors, is extremely rare in the pineal region with only few cases being reported in the literature [2, 3, 4, 5, 6, 7, 8, 9, 10, 11, 12]. Here we present a case of glioblastoma multiforme arising in the pineal region and discusses its clinical course, radiological findings and treatment strategies with a review of the relevant literature.

Case

43 year man presented with persistent severe headache, vomiting, blurring of vision and gait disturbances. Neurological examination revealed ataxic gait and bilateral papilloedema with upgaze palsy. The computed tomography (CT) scan revealed obstructive hydrocephalus caused by a round hypodense ill-defined lesion in the pineal region. A magnetic resonance (MR) imaging study demonstrated a 40 × 36 ×3 4 mm mass at the pineal region with hydrocephalus which was hypointense on T1, hyperintense on T2(figure 1) and heterogeneously enhancing with central necrosis on contrast (figure 2). He underwent an urgent ventricular-peritoneal shunt. After the ventricular-peritoneal shunt, he improved dramatically. CSF report was within normal limits. Surgery was performed by the infratentorial supracerebeller approach. During the operation, a very soft, grey-colored mass was located in the pineal region, which was barely demarcated from the surrounding structures. The mass was subtotally removed due to its adhesions and severe bleeding. The histopathologic examination revealed a high grade astrocytoma WHO-IV (glioblastoma multiforme) consisting of frequent mitotic figures, a high proliferation index, microvascular proliferation with endothelial cell hyperplasia, and extensive necrosis with focal pseudopalisading (figure 3). Immunohistochemistry showed a positive reaction to vimentin, glial fibrillary acidic protein, S-100 and p53. On the other hand, it showed a negative reaction to CD34, synaptophysin and NFP-MH. After surgical resection, he received radiotherapy and chemotherapy.

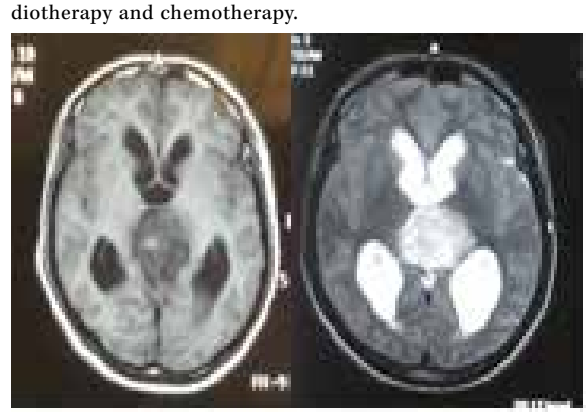

Figure 1: MRI showing a pineal region tumor which is hypointense on T1, hyperintense on T2

Volume : 5 | Issue : 3 | March 2016 • ISSN No 2277 - 8179 | IF : 3.508 | IC Value : 69.48

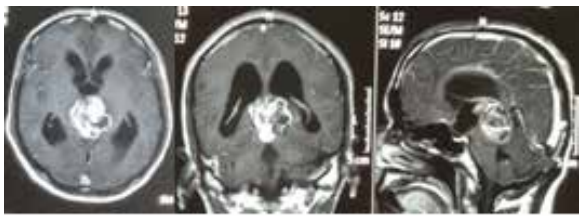

Figure 2: Contrast MRI showing a heterogenous enhancement of a pineal region tumor with obstructive hydrocephalus

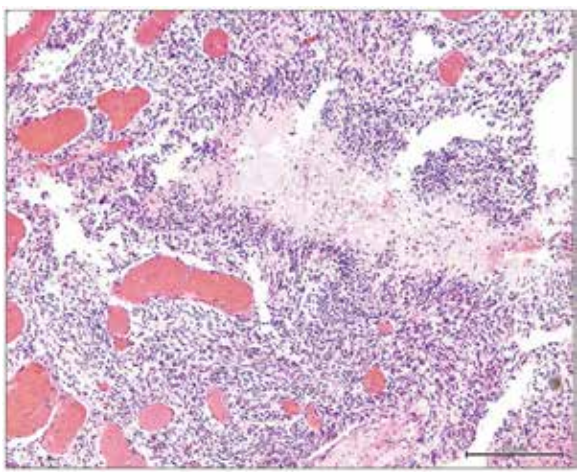

Figure 3: Histopathological findings showing the feature of glioblastoma multiforme composed of poorly differentiated pleomorphic tumor cells with marked nuclear atypia and brisk mitotic activity and focal necrosis with pseudopalisading.

Discussion

The pineal region is defined as the space formed superiorly by the splenium of the corpus callosum and choroid plexus of the third ventricle, anteriorly by the third ventricle, antero-inferiorly by the lamina quadrigemina, inferiorly by the anterior face of the cerebellum culmen and laterally by the thalami and medial faces of the cerebral hemispheres [13]. The tumors of the pineal region are uncommon, ranging from 0.5 to 2% of all intracranial neoplasms in several review papers [7, 8, 9, 10, 11, 12]. The origin of the tumors of this region can be the pineal gland itself, the posterior portion of the third ventricle and the quadrigeminal cistern. The symptoms are generally related to the compression of the adjacent structures and not related to the histopathology of the tumor. The most frequent symptoms are hydrocephalus (compression of the aqueduct of Sylvius) and dysfunctions of the eyes movement. CT-scan and MRI make the diagnosis of the presence of the pineal region tumor. These tumors are usually variable in shape, often irregular, with thick walls (more than 2 mm), larger than 20 mm, frequently compressing neighboring structures and infiltrative. The MRI is essential to analyze the tumor characteristics and its relation to neural and vascular structures. The association of the MRI (or CT image) and the clinical data may suggest a possible diagnosis. For instance, a young man with a homogeneous, round tumor probably has a germ cell tumor. The hypodense pineal mass with heterogeneous contrast enhancement and invasion of the adjacent thalamus presented in our case denotes a malignant lesion and has to be differentiated from any other malignant lesion of the pineal region. However, the final diagnosis should only be given with the histopathological examination. The majority of the pineal region tumors appears to be of germ cell origin and include germinomas, teratomas, and less commonly, embryonal carcinoma and choriocarcinoma. In fact, the pineal region is the most common site of intracranial germinomas and teratomas. These tumors usually develop in the first two decades of life and predominate in males [3]. The germinomas would appear hyperdense on CT-scan, with a strong contrast enhancement. MRI would show a lesion isodense to the grey matter. The teratomas do not have a specific image characteristic usually appearing as mixed density/intensity lesions.

The neoplasms originating from the pineal parenchymal cells occur with considerably less frequency. These tumors include pineocytoma, which is composed of relatively mature pineal cells, and the pineoblastoma, a more immature, poorly differentiated neoplasm. These tumors tend to occur in a slightly older age group and occur evenly in males and females [6, 7, 11]. The pineocytomas are radiologically indistinguishable from the benign pineal cysts. The pineoblastomas appear as big non-encapsulated masses with a strong or heterogeneous contrast enhancement and frequently invade the adjacent parenchyma.

Additional tumors arising from the glial components of the pineal gland include ganglioneuroma, ganglioglioma, chemodectoma, meningeoma, and gliomas, more frequently low-grade astrocytomas. The gliomas origin either from the glial tissue of the pineal gland or from the glial cells of the vicinity of this gland, such as the posterior portion of the third ventricle or the lamina quadrigemina. The low-grade astrocytomas would appear on CT-scan as iso or hypodense lesions with heterogeneous moderate contrast enhancement. MRI would show an iso or hypointense lesion on T1-wheighted image and hyperintese on T2-wheigthed images. Edema, hemorrhage and contrast enhancement are common features. Non neoplastic processes that may also simulate a pineal tumor at this location include epidermoid, dermoid and glial cysts [2,3,6].

Although GBM (WHO's astrocytoma grade IV) is the most frequent brain tumor, it is exceedingly rare at the pineal region with only few-reported cases [7, 8, 9, 10, 11, 12]. The age ranged between 6 and 68 years (mean age: 50 years). The predominant symptoms were related to hydrocephalus and ophthalmologic symptoms (especially Parinaud's syndrome). The CT scan examination often shows hydrocephalus [5, 7, 8]. The lesion on CT has different patterns such as a calcified mass in the midline, a mass lesion in the posterior third ventricle, or a rounded hyperdense mass at the pineal region with ring enhancement after contrast administration. MR imaging of pineal glioblastomas demonstrate characteristic features. Heterogeneous enhancement with a centrally located non-enhanced portion indicates central necrosis. Infiltration into the surrounding structures, such as midbrain and thalamus, is shown as hyperintensity on the T2-weighted MR image, extending beyond the margin of the enhanced mass.. Despite all available treatment protocols, GBM is a progressive malignant tumor with aggressive course and short survival. The mean survival in patients undergoing radiotherapy and chemotherapy after surgical resection in pineal region GBMs was shown to be 7 months. Longer survival durations were also noted in the literature of pineal GBMs. The presented case underwent surgery followed by RT/CHT as per treatment protocol.

Conclusion

The presented case, along with the others previously reported cases; suggest that although glioblastoma multiforme is rare in pineal region, it should be considered in the differential diagnosis due to available treatments and prognosis.

REFERENCES

1. Hirato J, Nakazato Y. Pathology of pineal region tumors. J Neuro-Oncol. 2001; 54:239-249.
2. Bailey S, Skinner R, Lucraft HH, Perry RH, Todd N, Pearson ADJ. Pineal tu-

mours in the north of England 1968-93. Arch Dis Child 1996;75:181-185.

3. Prahlow JA, Challa VR. Neoplasms of the pineal region. South Med J 1996;89:1081-1087.
4. Cho BK, Wang KC, Nam DH, et al. Pineal tumors: experience with 48 cases over 10 years. Child Nerv Syst 1998;14:53-58.
5. De Girolami U, Schmidek H Clinicopathological study of 53 tumors of the pineal region. J Neurosurg 1973;39:455-462.
6. Frank F, Gaist G, Piazza G, Ricci RF, Sturiale C, Galassi E. Stereotaxic biopsy and radioactive implantation for interstitial therapy of tumors of the pineal region. Surg Neurol 1985;23:275-280.
7. Kalyanaraman UP. Primary glioblastoma of the pineal gland. Arch Neurol 1979;36:717-718.
8. Norbut AM, Mendelow H. Primary glioblastoma multiforme of the pineal region with leptomeningeal metastases: a case report. Cancer 1981;47:592-596.
9. Vaquero J, Ramiro J, Martinez R. Glioblastoma multiforme of the pineal region. J Neurosurg Sci 1990;34:149-151.
10. Pople IK, Arango JC, Scaravilli F. Intrinsic malignant glioma of the pineal gland. Child Nerv Syst 1993;9:422-424.
11. Moon KS, Jung S, Jung TY, Kim IY, Lee MC, Lee KH. Primary glioblastoma in the pineal region: a case report and review of the literature. J Med Case Rep. 2008;2:288.
12. Ozgural O, Kahilogullari G, Bozkurt M, Heper AO, Savas A. Primary pineal glioblastoma : a case report. Turk Neurosurg. 2013;23:572–574.
13. Caldas, JG, Doyon D, Lederman H, Carlier R. Estudo por ressonancia magnetica da regiao pineal: pineal normal e cistos simples. Arq Neuropsiquiatr 998;56:237-244.