Primary renal hydatid cyst : A case report and surgical management

Medical Science

KEYWORDS : Hydatid, Renal, Hydatiduria

Dr A.O.Noyda (MS)	Associate professor in General surgery, Room No 46, New PG Hostel, M.P.Shah Medical College, Jamnagar,
Dr Nirav Satasia (MS)	Assistant Professor in General surgery, Room No 46, New PG Hostel, M.P.Shah Medical College, Jamnagar,
Dr Ankur Sangal	3rd year Resident in surgery, Room No 46, New PG Hostel, M.P.Shah Medical College, Jamnagar,
Dr Mohd Aizaz Khan	2nd year Resident in surgery, Room No 46, New PG Hostel, M.P.Shah Medical College
Dr Alaknanda Atara	3rd year Resident in surgery, Room No 46, New PG Hostel, M.P.Shah Medical College, Jamnagar,

ABSTRACT

We present a rare case of primary left renal hydatid cyst in a 50 year male patient admitted with left lumbar pain. Radiological investigations were suggestive of Hydatid cyst of left kidney upper pole. The hydatid cyst was treated by preoperative course of Tab Albendazole followed by open surgical cystecomy and postoperative Tab Albendazole therapy. This case emphasizes the need for a better detection and evaluation of such rare case to identify better treatment modality.

Introduction:
Kidney involvement in Echinococcosis caused by tapeworm is extremely rare and it comprises of only 2-3% of all cases [1]. Isolated involvement of kidney is even rarer. Patient may be asymptomatic or present with symptoms of lumbar pain, hydatiduria, hematuria [1,2].

Case Report:
A 50 years old male, farmer, resident of Jamnagar, Gujarat presented with left lumbar pain with no history of hematuria, dysuria or pyuria since four months. Clinical examination did not reveal any significant findings. Hematological profile showed increased level of IgE and CRP with Eosinophilia. Urine examination was normal with no ova or cyst. Abdominal Ultrasonography revealed multiloculated, exophytic, heterogenous lesion arising from upper pole of left kidney with mild hydronephrosis. Computed tomographies of abdomen showed a well defined capsulated cystic lesion with internal septas and membrane in upper pole of left kidney and appear to communicate with upper calyx suggestive of Hydatid cyst [Fig.1].

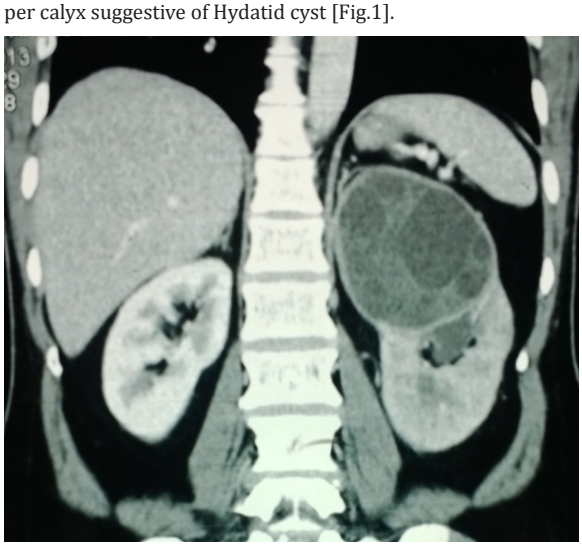

[Fig.1: CT scan of abdomen showing hydatid cyst involving the upper pole of left kidney.]

Patient received eight weeks of Tab Albendazole followed by open surgery was planned. Open Hydatid cyst excision was done under general anesthesia via a left lumbar incision. The left kidney with cyst in its upper pole was identified and made free from adjoining tissue adhesion. Cyst is confirmed by aspirating cystic fluid and thereafter scolicidal agent Cetrimide solution is injected in cyst. Mop soaked in diluted cetrimide solution is spread around the operating field to prevent contamination. A small incision was made in cyst wall, daughter cyst & all other membranous contents were evacuated [Fig. 2].

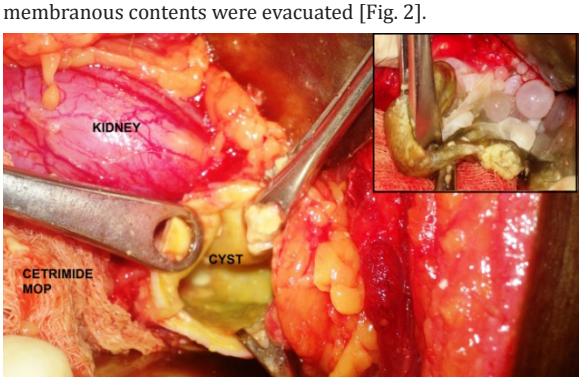

[Fig. 2: Intraoperative cystic cavity over upper pole of left kidney. Inset: daughter cyst in cystic cavity]

Nephrotomy on left side was done and proximal & distal patency was checked. Thereafter a Double 'J' stent 6Fr. was kept in situ. Excess of cyst wall was excised and remnant of parenchyma of upper pole of left kidney was closed [Fig.3].

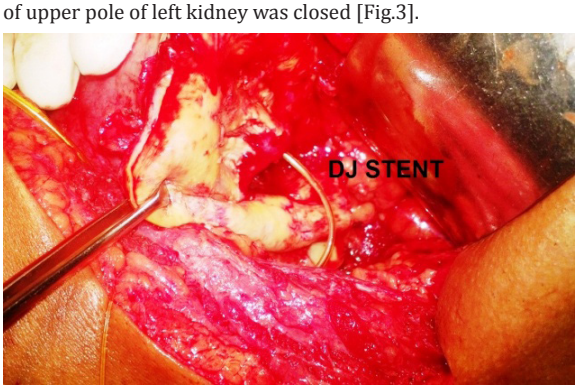

[Fig.3:Nephrotomy with pericystectomy with DJ stent in situ]

The patient was given Tab Albendazole for 1 month post operatively. Histopathological report was consistent with left renal hydatid cyst.

Discussion:

Echinococcosis is zoonoses produced by larval stage of E.granulosus. the adult worm lives in the proximal small intestine of definitive host and attaches to mucosa by hooklets. Eggs are released in intestine of host & excreted in faeces. The humans become intermediate host by contact with definite host (dog) or from ingestion of soil, water or vegetable. The ovum loses its protective coating on undergoing digestion in the duodenum. Once the parasite embryo passes through the intestinal wall to reach to reach portal venous system or lymphatic system, the Liver which is first defense is involved(75%), lungs(15%). Secondary involvement due to hematogenous may be seen in almost any anatomic location. Kidney involvement is extremely rare(2-3%) [1,3,4]. It is postulated that hydatid embryo must pass through the portal system into the liver & retroperitoneal lymphatics in primary renal hydatid. The hydatid cyst of kidney is considered closed if all three layer i.e pericyst, ectocyst and endocyst are intact. When the cyst is without pericyst it is considered exposed cyst. When all 3 layers rupture resulting in free communication with calyx & pelvis, it is called an open or communicating cyst. Cystic rupture into the collecting system, causing hydatiduria is pathognomonic, though seen in only 10-15% of renal hydatidosis & is usually microscopic [5]. Serological test in primary renal hydatidosis are usually negative. On ultrasonography, the hydatid cyst may be seen as unilocular(type 1) or multiseptate daughter cyst with pathognomonic 'falling snowflake pattern' appearance(type 2) or a cyst which exhibit a bright echogenic focus with strong posterior acoustic shadow (type 3). The diagnostic CT finding of renal hydatid disease reveal a unilocular cyst(type 1), a multilocular cyst(type 2) & a complete calcified cyst(type 3)[6]. The MRI shows the cyst adequately but MRI offers no real advantage over CT scan[5]. Surgery is the treatment of choice in cases of renal hydatid cyst[7]. Kidney sparing hydatid cyst removal (Cystectomy with pericystectomy) is possible in 75%, Nephrectomy (25%) is considered only if kidney is destroyed by the cyst. Both open & laparoscopic techniques have been described. There is fear of cyst rupture & dissemination during laparoscopy. Care must be taken to prevent spillage & resultant disseminated hydatidosis during surgery. Scolicidal agents such as hypertonic saline or cetrimide should be used before opening the cavity to kill the daughter cyst. Preoperative and postoperative course of Tab Albendazole is recommended to sterilize the cyst, decrease the chance of anaphylaxis also reducing the risk of spillage during surgery and recurrence post operatively [8].

Conclusion:

Most cases of renal hydatidosis are dealt with open surgery i.e cystectomy with pericystectomy. In this case a kidney sparing cystectomy with nephrotomy with Double'J' stent in situ in done. More study on such cases of primary renal hydatidosis to definite a standard treatment modality. Also minimally invasive approaches need to be studied in comparison with open approach.

REFERENCE

1. Pedrosa I, Saiz A, Arrazola L, Ferreiros J, Pedrosa CS. Hydatid disease: Radiologic and pathologic features and complications. Radiographics 2000:20:795-817. | 2. Von Sinner WN, Hellstrom M, Kagevi I, Norlen BJ. Hydatid disease of the urinary tract. J Urology 1993;149:577-80. | 3. Mongha R, Narayan S, Kundu AK, Primary hydatid cyst of the kidney and the ureter with gross hydatiduria: A case report and evaluation of radiological features. Indian J Urol 2008;24:116-117. | 4. Saxena S, Gupta R, Nigam DK, Tahiliani ND, Saxena KN. Hydatid cyst of kidney presenting as hydatiduria. J Assoc Physicians India 1990;38:359-69. | 5. Unsal A, Cimentepe E, Dilmen G, Yenidunya S, Saglam R. An unusual cause of renal colic: Hydatiduria. Int J Urol 2001:8:319-21. | 6. Polat P, Kantarci M, Alper F, Suma S, Koruyucu MB, Okur a. Hydatid disease from head to toe. Radiographics 2003;23(2):475-94. | 7. Zmerli S, Ayed M, Horchani A, Charmi I, El Ouakdi M, Ben Slama MR. Hydatid cysts of the kidney: diagnosis and treatment. World J Surj 2001;25(1):68-74. | 8. Sir Alfred Cushieri, Steele RJC, Moosa AR, Treatment of Hydatid Cyst, Essential Surgical Practice, 4th ed. Arnold Publishers;350. |