ORIGINAL RESEARCH PAPER

Volume-8 | Issue-1 | January-2019 | PRINT ISSN No 2277 - 8179

INTERNATIONAL JOURNAL OF SCIENTIFIC RESEARCH

PROLONG CHOLESTATIC JAUNDICE AFTER ACUTE VIRAL HEPATITIS (HAV)? IS CORTICOSTEROID BENEFICIAL

General Medicine

Dr. V. N. Mishra* Professor, Pt.J.N.M.Medical college, Raipur(C.G.) *Corresponding Author

Dr. S. Varma Associate prof, Pt.J.N.M.Medical college, Raipur(C.G.)

Dr. A. Toppo Associate prof, Pt.J.N.M.Medical college, Raipur(C.G.)

Dr. M. Patil Assistant Prof, Pt.J.N.M.Medical college, Raipur(C.G.)

Dr. A. K. Shadani Senior Resident Pt.J.N.M.Medical college Raipur(C.G.)

Dr. Meena Patel Resident Pt.J.N.M.Medical college Raipur(C.G.)

ABSTRACT

Hepatitis A is usually a self-limited, asymptomatic infection. However, severe manifestations of hepatitis may occur rarely in adult patients.Severe cholestasis is one of the important causes of prolonged hospitalization in patients with acute hepatitis A. In such cases, higher chances of additional complications and increased medical costs are inevitable.

We present a case of prolonged cholestasis secondary to acute hepatitis infection (hepatitis A) in an adult patient who showed favorable responses to oral corticosteroids. A 21-year old male patient presented with complaints of weakness, abdominal pain, loss of appetite, nausea and yellowish discoloration of urine. A week later, he had been diagnosed with acute hepatitis A infection. He admitted to our hospital two months after the first episode with complaints of unresolved symptoms and intense pruritus which disturbed his sleep . His laboratory results included a serum (ALT) level of 385 U/L, (AST) of 395 U/L, total bilirubin of 29.4 mg/dl and direct bilirubin of 23.0 mg/dl. (UDCA) & cholestyramine,antihistaminics and supportive therapy was started due to protracted jaundice, severe itching and a marked elevation in bilirubin levels,subsequently prednisolone therapy at a dose of 1 mg/kg/day at day 70 started. Most of his clinical symptoms resolved with much lower serum bilirubin level. There are few case reports in literature about the use of corticosteroids for treatment of prolonged cholestatic jaundice in patients with hepatitis A infection.

KEYWORDS

HAV-hepatitisAvirus,ALT-alanineaminotransferase,AST-aspartate ransferase ,UDCA-ursodeoxycholic acid.

1.INTRODUCTION

Hepatitis A virus (HAV) is a member of the picornaviridae family and the most common cause of viral hepatitis cases worldwide. Globally, about 1.5 million new cases of HAV infection occur each year but the true incidence is estimated to be 10-fold greater.HAV infection exhibits three different patterns of endemicity (high, intermediate and low) based on its incidence.

HAV usually causes self-limiting, asymptomatic, subclinical infections in chidlhood, whereas the clinical spectrum in the adult age group ranges from mild, anicteric form to fulminant hepatitis. Atypical HAV infections occur in approximately 7% of cases and three forms of hepatitis A were identified including prolonged cholestatic, relapsing and fulminant forms. Prolonged cholestatic form is characterized by persistently elevated bilirubin levels for more than eight weeks above 15 mg/dl as well as itching, fatigue, diarrhea and weight loss. Here, we present a case of prolonged, cholestatic form of hepatitis A infection in an adult patient who failed to show clinical response to initial adjuvant therapy but successfully treated with prednisolone.

2.CASE REPORT

A 21-year old male patient had visited a physician about two months ago due to complaints of malaise, abdominal discomfort, nausea and yellowish discoloration of urine , hospitalized following diagnosis of acute hepatitis A and received therapy. .Subsequently,he was admitted to our hospital for his intense pruritus and jaundice .

The patients denied history of taking any medicines, excessive drinking, and presence of chronic liver disease. Laboratory work-up showed: hemoglobin: 12.6 g/dL, leukocyte count: 6250 /mm3 (61.8% neutrophils, 22.7% lymphocytes, 10.1% monocytes, 4.6% eosinophils), platelet count: 313.000/mm3, AST: 385 U/L, ALT:395 U/L, ALP:532 U/L, total bilirubin: 29.4mg/dl, direct bilirubin: 23 mg/dl, indirect bilirubin:6.4 mg/dl, PT:13.6 sec, INR:1.2, . Indirect and direct Coombs' tests were negative. Serologic assays showed: HAV-IgM positive, HBsAg negative, Anti-HBs negative, AntiHBc-total negative, Anti-HCV negative, Anti-HEV IgM negative. Abdominal ultrasonography examination showed hepatomegaly possibility of obstructive jaundice ruled out by CT scan focusing billiary radicals,biopsy was not done as patient gave negative consent for procedure.

His initial treatment regimen ursodeoxycholic acid capsules, lactulose suspension cholestyramine antihistaminics,Along with above regimen Prednisolone at a dose of 1 mg/kg was added to his treatment regimen on Day 5 of hospitalization (approximately 70 days after occurrence of his first symptoms) due to persistently troulblesome itch ,loss of appetite and raised billirubin levels. On the 7 th day of this therapy, blood bilirubin level fell to 17.0 mg/dL and continued to decrease in the following days. Prednisolone dosage was gradually tapered .

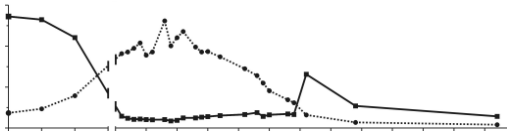

Figure 1. Bilirubin and ALT serum levels during the clinical course of the HAV infection. Bilirubin levels (dotted line) improved dramatically once corticosteroids was initiated. Aminotransferase activities (continued line) remained normal throughout the latter phase of the disease.

TABLE 1. DEMOGRAPHIC DATA AND CLINICAL COURSES OF THE PATIENTS WITH CHOLESTATIC HEPATITIS A

1. Peak serum ALT (IU/L)-2100
2. Peak serum total bilirubin (mg/dL)-33.80
3. Pre-prednisolone treatment serum ALT (IU/L)-434
4. Pre-prednisolone treatment serum total bilirubin (mg/dL) -27.9
5. Hospital days before administration of prednisolone (day)-70
6. Time to discharge after prednisolone use (day)-8
7. Time to decrease below the half level of pretreatment bilirubin (day)
8. Time to normalization of serum bilirubin (day)
9. This includes admission periods of 30 days at a local hospital for symptomatic treatment.
10. This includes admission periods of 25 days at a local hospital for symptomatic treatment.

3.DISCUSSION

While hepatitis A virus infections are common in developing countries, they rarely occur and cause epidemics in developed countries. Hepatitis A disease may manifest itself in clinical and subclinical forms depending on age and cases of prolonged, relapsing

or cholestatic hepatitis were reported at a global incidence of 5-10% in literature. Cholestatic VHA with high bilirubin levels for months,is very rarely seen (WHO/CDS/CSR/EDC/2000).

Cholestasis result from any defects in the step of the bilirubin metabolism; decreased uptake of bilirubin, impaired conjugation in the hepatocytes, disorders of bile excretion into biliary system, or obstruction of bile ducts may involve.the lack of a chronic process and the temporary increase of bile capillaries permeability influence reversibly the osmotic gradientand the activity of Na+, K+, ATP-transport, and the disturbed production, secretion and drainage of bile.The cholestatic form of hepatitis A was first identified in 1984 in a patient who presented with cholestasis accompanied by severe pruritis, diarrhea and weight loss and was treated successfully with corticosteroid therapy without any sequelae. Since then, cholestatic form which is defined as a variant of acute hepatitis A was reported in 10% of symptomatic patients as isolated cases or in small case series. However, there is one report in literature concerning a case of hepatic necrosis and persistently elevated transaminase levels despite use of corticosteroid therapy. Concurrent cholestasis in the setting of a clinical hepatitis A infection is the result of an inflammatory process. Excessive secretion of systemic and intrahepatic endotoxins as well as cytokines including TNF-alpha and IL-1 are implicated Additionally, the synthesis of a transporter protein, multidrug resistance-associated protein 2 (mrp2) was reported to be inhibited during this process; mrp2 is responsible for excretion of bilirubin out of hepatocytes during bilurubin metabolism.In addition, there are several glucocorticoid responsive elements on the promoter region of the mrp2 gene.

In this report, we presented a patient with cholestatic hepatitis A infection who had very high direct bilirubin levels and was successfully treated with prednisolone. The value of corticosteroids in the treatment of hepatitis is controversial. The genotype of the viral hepatitis A is also reported to affect the severity of the cholestasis..Although spontaneous clinical improvement was reported in some cases with cholestatic form of the disease.However, exact causes of prolonged cholestasis are unknown so use of corticosteroids may provide rapid correction of clinical manifestations in selected non-immunocompromised patients presenting with very severe symptoms associated with cholestatic form of the disease under close supervision.

REFERENCES

1) Corpechot C, Cadranel JF, Hoang C. Cholestatic viral hepatitis A in adults. Clinical, biological and histopathological study of 9 cases. Gastroenterol Clin Biol 1994;18(8-9):743-50.
2) Coppola N, Genovese D, Pisaturo M, Taffon S, Argentini C, Pasquale G, et al. Acute hepatitis with severe cholestasis and prolonged clinical course due to hepatitis A virus Ia and Ib coinfection. Clin Infect Dis 2007;44:e73-77.
3) Trauner M, Fickert P, Stauber RE. Inflammation-induced cholestasis. J Gastroenterol Hepatol 1999;14:946-959.
4) Wolkoff AW. The hyperbilirubinemias. In: Fauci AS, Braunwald E, Kasper DL, Hauser SL, Longo DL, Jameson HL, eds. Harrison's principles of internal medicine. Vol II. 17th ed. Mc Graw Hill, 2008:1927-1931.
5) Roelofsen H, Schoemaker B, Bakker C, Ottenhoff R, Jansen PL, Elferink RP. Impaired hepatocanalicular organic anion transport in endotoxemic rats. Am J Physiol 1995;269:G427-434.
6) Kauffmann HM, Schrenk D. Sequence analysis and functional characterization of the 5'-flanking region of the rat multidrug resistance protein 2 (mrp2) gene. Biochem Biophys Res Commun 1998;245:325-331.
7) Demeule M, Jodoin J, Beaulieu E, Brossard M, Beliveau R. Dexamethasone modulation of multidrug transporters in normal tissues. FEBS Lett 1999;442:208-214.
8) Sherlock S. Viral Hepatitis; General Features, Hepatitis A, Hepatitis E and Other Viruses. In: Sherlock S, Dooley J, eds. Diseases of the Liver and Biliary System. Oxford: Blackwell Scientific, 2002:272-276.
9) Hepatitis A vaccines. Wkly Epidemiol Rec 2000; 75: 38-44
10) Gordon SC, Reddy KR, Schiff L, Schiff ER. Prolonged intra-hepatic cholestasis secondary to acute hepatitis A. Ann Intern Med 1984; 101: 635-7.
11) Grünhage F, Spengler U, Fischer HP, Sauerbruch T. Au-toimmune hepatitis—sequel of a relapsing hepatitis A in a 75-year-old woman. Digestion 2004; 70: 187-1.
12) Radha Krishna Y, Saraswat VA, Das K, Himanshu G, et al. Clinical features and predictors of outcome in acute hepatitis A and hepatitis E virus hepatitis on cirrhosis. Liver Int 2009;29(3):392-8.