ORIGINAL RESEARCH PAPER

Volume-8 | Issue-1 | January-2019 | PRINT ISSN No 2277 - 8179

INTERNATIONAL JOURNAL OF SCIENTIFIC RESEARCH

PROSPECTIVE STUDY OF CLOSURE OF COMPOUND WOUNDS WITH STAINLESS STEEL WIRES

Plastic Surgery

Dr. Pokkula Ramesh Associate Professor, Department of Plastic Surgery, Gandhi Medical College, Secunderabad, Telangana, India.

Dr. Challuri Anita* Associate Professor, Department of Bio-Chemistry, Osmania Medical College, Hyderabad, Telangana, India. * Corresponding Author

Dr. Arige Subodh kumar Professor and Head of the Department, Department of Plastic Surgery. Gandhi Medical College, Secunderabad, Telangana, India.

Dr. Erugurala Mahendar Assistant Professor, Department of Plastic Surgery, Gandhi Medical College, Secunderabad, Telangana, India.

Dr. Valluri Mukesh Krishna Postgraduate, Department of Plastic Surgery, Gandhi Medical College, Secunderabad. Telangana, India.

ABSTRACT

INTRODUCTION: Chronic compound wounds are common due to increase in trauma. Wound closure using external fixators is described , bringing the inherent skin properties into play, and here 24 guage Stainless Steel wire was used .

AIM: To study the effectiveness of wound closure in compound chronic wounds using 24 guage Stainless Steel wire.

RESULTS: Study was done on 15 males, and five females , aged between 10 to 60 years, with wounds on leg, varying in sizes between 15 and 96 square centimeters. The wound closure was achieved in two weeks. Two complications of wire cutting, were addressed by skin grafting

MATERIAL AND METHODS: Prospective study was done using 24 guage Stainless steel wire on 20 patients in Gandhi hospital in 2017. Under Local anesthesia , two 24 guage wires were introduced in the sub-dermal plane, twisting was done on alternate days to narrow down the wound size, till approximation.

DISCUSSION: Skin has inherent properties like elasticity, stress relaxation and creep. Stainless steel wire, was used towards achieving wound closure by expanding the skin, and in all local anaesthesia, was used on out-patient basis, needing lesser time than the flap cover. The approximation time was less than three weeks.

KEYWORDS

Compound wound, Wound closure, Stainless steel wire, skin properties, wire twisting.

INTRODUCTION:

Compounds wounds [1,2,3] generally are addressed by providing flap cover [4,5]. Due to increase in admission of such patients and with limited man power and infrastructure, primary flap cover is becoming difficulty. People have been using external fixators [6] and dermaclips to attain wound closure, putting into play the inherent skin properties. Such simpler procedures led us to think about using 24 guage stainless steel wire. With this method we were able to bring approximation of the skin on the compound wound in good number of patients under local anaesthesia and on out-patient basis.

MATERIAL AND METHODS:

The study was a Prospective study and was done using 24 guage Stainless steel wire on 20 patients in the department of Plastic surgery at Gandhi hospital, Secunderabad, Telangana in 2017.

Patients were explained about the procedure, consent was taken. Measurements of the wound [7] were taken, along with Photographs. Area was cleaned, draped. Xylocaine sensitivity is tested.

1% Xylocaine (2% Xylocaine at a dose of 3 mg/kg body weight is diluted in the ratio of 1:1 with distilled water) is infiltrated along the longitudinal border of the wound at one inch distance from the wound margin.

After waiting for the local anesthesia effect , Stainless steel wire 24 guage is passed along the sub-dermal plane from a distance of about an inch in the direction of the wound and is retrieved from the wound margin . The same maneuver is done with the other end of the same wire to retrieve it through again the wound margin a little away from the first emergence of the wire (Figure.1A). Another wire is used on the other side of the wound and the same procedure is repeated (Figure.1B). Now we have two ' U' shaped wires exactly facing each other in each section of the wound. The wires of each limb of 'U' are caught of opposite Stainless Steel wires and few twists are made with the twister. Now the same thing is done using the other limbs of opposite 'U' shaped SS wires. These wires are twisted alternatively and reduction of wound size is observed (Figure.1C). This is done till the skin begins to go into tension, ensuring that the wires are not twisted over- enthusiastically. Depending on the laxity of the skin we can approximate the margins of the wound by 3-6 mm on either side reducing the total width of the wound by 6-12mm in the first sitting itself with- out much tension on the wound, then onwards wire twisting is done on alternate days till the wound edges come into approximation. Once the margins of the wound come close, they are approximated by using 3-0 Prolene suture (Figure.1D). Stainless steel wires are removed the next day and the Prolene sutures are removed at the end of one week of application (Figure.1E). In case of larger wounds, multiple Stainless steel wires were used making more than two to three "U" shaped loops facing each other at intervals (Figure.1F).

INCLUSION CRITERIA :

1) Patients willing to give consent
2) Patients with compound wounds on forearm, leg and foot
3) Patients between 10 and 70 years of age.
4) Patients with chronic wounds not suitable for skin grafting or persistent wound with graft loss after 2 sessions of skin grafting.
5) Wounds with- in 3X15 Cm.

EXCLUSION CRITERIA:

1) Those not willing to give consent
2) Defects more than 3X15 Cm. size
3) Diabetics
4) Smokers
5) Hypertensives
6) Those with other serious medical problems
7) Patients on immune- supressant drugs
8) Patients with surrounding Cellulitis
9) Patients with scarred areas near the defect.
10) Wounds nearer to structures where skin expansion is likely to cause disfigurement of natural landmarks and vital areas.

FOLLOW UP:
After the wound is approximated, patient is instructed to come on follow-up at intervals of two weeks for two visits and then at monthly interval for three months. Patients were told to come at any time, if there were to be any problem, related to the wound in the limb after discharge, from the hospital.

RESULTS:
The study was done using 24 guage Stainless steel wire on 20 patients in the department of Plastic surgery at Gandhi hospital, Secunderabad, Telangana in 2017.

The study was done on patients aged between 10 and 70 years. 15% (3/20) were aged between 10 – 20 years. 35% (7/20) were between 21 and 30 years, 15% (3/20) were between 31 and 40 years, 20% (4/20) werebetween 41 and 50 years, 10% (2/20) were between 51 and 60 years and 5% (1/20) were between 61 and 70 years of age.

70% (14/20) of the patients were males and 30% (6/20) were females.

35% (7/20) of the patients had defect on the leg, another 35% (7/20) had defect on the foot. 10% (2/20) had defect on the knee, 5% (1/20) had it on the forearm, 10% (2/20) had the defect on the elbow, and 5% (1/20) had the defect on the forehead.

The size of the defect was about 3X15 cm (15Sq.cm) in 5 % (1/20) patients. It was 4X8cm (32Sq.cm) in 45% (9/20) patients , 5 X 10 cm (50Sq.cm) in 20% (4/20) patients, 6X15cm (90Sq.Cm) in 15% (3/20) patients, 7X15cm (105 Sq.cm) in 5%(1/20) patients and 8 X 12 cm (96 Sq.cm) in 10% (2/20) patients.

30% (6/20) of the patients needed twists of the wires on 6 occassions, for the approximation of the wound to be achieved. Another 30% (6/20) of the patients needed it on 7 occassions, 25% (5/20) needed it on 8 occassions, 5%(1/20) of the patients needed it on 10 occassions, 10% (2/20) needed it on 12 ocassions and 10% (2/20) of the patients needed it on 12 occassions.

Wound approximation was achieved in 60% (12/20) of the patients in less than 2 weeks period, in another 30% (6/20) of the patients it needed 3 weeks and in 10% (2/20) of the patients it was achieved in less than 4 weeks period.

Results have been categorized as good, if complete approximation was achieved, average if the wound needed a small skin graft and as poor, if unable to bring approximation or had cut-through of the wire. In 45% (9/20) of the patients, we had good result, in 35% (7/20), the result was average and in 20% (4/20) of the patients, it was poor and they were on the feet. (Figure 5).

The complication rate was 20% (4/20). Of them, in 10% (2/20) , there was the wire cutting through the margins and in another 10% (2/20) patients, the wire got broken and needed reapplication.

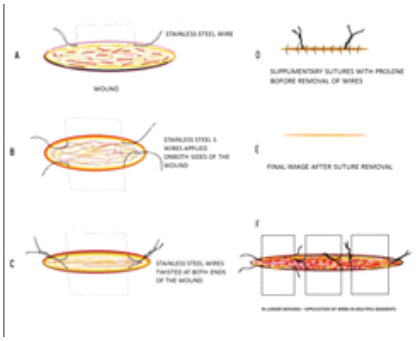







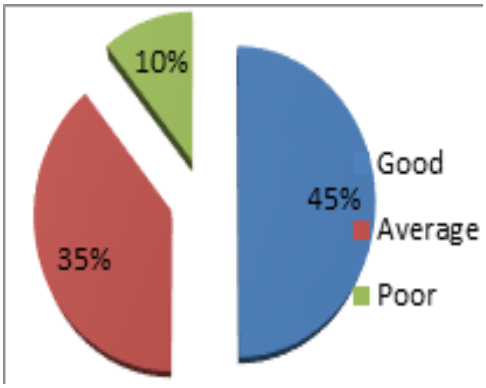

DISCUSSION:

Compound wounds invariably need flap cover. Flap cover is usually done under major anaesthesia and is time consuming. Patient would have to be an in-patient. Donor morbidity is an accompaniment of the flap cover.

In Public sector tertiary unit, with limited infrastructural and human resources, and with a lot of patients needing surgery in waiting, alternative methodologies would have to be adopted which help in providing early skin cover without any major anaesthesia and in such an attempt, this study has been done using 24 guage Stainless steel wire.

Skin has inherent properties[8,9] namely Stress relaxation[10,11], elasticity, and creep. These properties can be put into play and bring about providing skin cover using the native skin adjacent to the defect.

Studies have been done using external fixators, in achieving wound closure of the compound wounds, but the external fixator of certain particular specifications are meant to be used and it involves certain amount of cost, in procuring them.

Here, in the department, Stainless steel wires of 24 guage are in regular supply and has been used in place of the external fixator to bring about wound approximation.

The viscoelastic properties of skin viz., "creep", and "stress relaxation" are put into play in this process. "Creep", occurs when skin is stretched and the force applied for it is kept constant, while in "stress relaxation", the force required gradually decreases, in achieving the stretching of the skin. It is important to understand that "time" is required to achieve the stretch of the skin [12].

Majority of the patients were males, aged between 10 and 50 years. Defects on the legs were the predominant ones addressed with sizes ranging from 5-6 cm X 6-10 cm. Majority of the patients needed an average of seven attempts of twist procedures and wound closure was achieved in three weeks.

In majority of the defects on the leg and forearm we were able to get either good (45%) or average (35%) results, but for those on the foot, the procedure ended up as poor result (20%).

Through this study, defects on forearm (Figure 2), and leg (Figure 3, Figure 4) , wherein the soft tissue defect around the critical area of compound nature is not fit for placing the tissue expander, usage of stainless steel wire, was found to be quite beneficial.

Through this technique, we have been able to obviate the need for flap cover under major anaesthesia, for patients with defects on forearm and leg. This procedure has shortened the stay of the patient in the ward, unlike those given flap cover, who had to be as inpatients till delay and then division and inset were completed.

We found the following advantages and disadvantages.

ADVANTAGES:

1) Very simple technique taking less than half an hour time.
2) Done under local anaesthesia
3) Avoids major flap surgeries
4) Lesser morbidity
5) Avoids multiple stages of flap surgeries
6) No need of donor site skin grafting
7) Cosmetically near normal in appearance
8) No need for expertise in major flap technique.
9) Less hospital stay
10) Can be done on O.P. basis
11) Less financial burden in govt. institutes
12) Less financial burden on patients

DISADVANTAGES:

1) Not an option for compound wounds with exposed tendons, nerves, and vessels where immediate flap cover is required.
2) Not suitable in certain areas where skin elasticity is less.
3) Not suitable for larger wounds

CONCLUSION: Simple device like Stainless steel wire of 24Guage can certainly be considered to bring about selected wounds on the forearm and leg by putting into application the inherent skin properties of " Creep", and " Stress relaxation", but would have to be done over a period of time , which on an average was about 3 weeks in our study. The same at present, has not been found to give encouraging results on the foot.

ACKNOWLEDGEMENTS:

I thank Dr.G.Rangaswamy, , Assistant Professor in the Department who have helped me during the study. I thank Dr.Chandralekha, Senior resident , Dr.Kavitha, Dr.Arjun, Dr.Mabu, Dr.Vijay, Dr. Deepthi.K., Dr.Deepthi.A., postgraduates who have helped me during the study.

REFERENCES:

[1] Scharfenberger, Angela V. MD, FRCS; Alabassi, Khaled MD; Smith, Stephanie MD, FRCP; Weber, Donald MD, FRCS; Dulai, Sukhdeep K. MD, MSc, FRCS; Bergman, Joseph W. MD, FRCS; Beaupre, Lauren A. PT, PhD; Primary Wound Closure After Open Fracture: A Prospective Cohort Study Examining Nonunion and Deep Infection ; Journal of Orthopaedic Trauma: March 2017 - Volume 31 - Issue 3 - p 121–126
[2] Weaver, Michael J. MD*; Owen, Trevor M. MD†; Morgan, Jordan H. BS*; Harris, Mitchel B. MD ; Delayed Primary Closure of Fasciotomy Incisions in the Lower Leg: Do We Need to Change Our Strategy? ; Journal of Orthopaedic Trauma: July 2015 - Volume 29 - Issue 7 - p 308–311
[3] Weaver, Michael J. MD*; Owen, Trevor M. MD†; Morgan, Jordan H. BS*; Harris, Mitchel B. MD ; Delayed Primary Closure of Fasciotomy Incisions in the Lower Leg: Do We Need to Change Our Strategy? ; Journal of Orthopaedic Trauma: July 2015 - Volume 29 - Issue 7 - p 308–311
[4] Beltran, Michael J. MD*; Blair, James A. MD*; Rathbone, Christopher R. PhD†; Hsu, Joseph R. MD ; The Gradual Expansion Muscle Flap ; Journal of Orthopaedic Trauma: January 2014 - Volume 28 - Issue 1 - p e15–e20
[5] VandenBerg, James BS; Osei, Daniel MD, MSc; Boyer, Martin I. MD; Gardner, Michael J. MD; Ricci, William M. MD; Spraggs-Hughes, Amanda BS, MA; McAndrew, Christopher M. MD, MSc ; Open Tibia Shaft Fractures and Soft-Tissue Coverage: The Effects of Management by an Orthopaedic Microsurgical Team ; Journal of Orthopaedic Trauma: June 2017 - Volume 31 - Issue 6 - p 339–344
[6] By G. Hierholzer, Th. Ru¨edi, M. Allgo¨wer and J. Schatzker. Pp. 100 with 104 figures. (Berlin, Heidelberg, New York and Tokyo: Springer-Verlag, 1985). Price DM 86; Manual on the AO/ASIF tubular external fixator ; British Journal of Plastic Surgery, Volume 38; Issue 4; October 1985, Pages 593-594
[7] Rahul Shetty, H Sreekar, Shashank Lamba, Ashish Kumar Gupta Department of Plastic and Reconstructive Surgery, Christian Medical College, Vellore, Tamil Nadu, India;A novel and accurate technique of photographic wound measurement ; Indian Journal of Plastic Surgery; Year :2012| Volume: 45 | Issue: 2 | Page : 425—429.
[8] Pietramaggiori G, Liu P, Scherer SS (2007) Tensile forces stimulate vascular remodeling and epidermal cell proliferation in living skin. Ann Surg 246(5):896-902PubMed Cross Ref Google Scholar
[9] Austad ED, Pasyk KA, McClatchey KD, Cherry GW (1982) Histomorphologic evaluation of guinea pig skin and soft tissue after controlled tissue expansion. Plast Reconstr Surg 70:704–710PubMedCrossRefGoogle Scholar
[10] Bandikatla Venkata Ratnam ; Department of Plastic Surgery, NMCS Hospital, Abu Dhabi, United Arab Emirates ; A simple external tissue expansion technique based on viscoelastic properties of skin to attain direct closure of a large scalp defect: A case report ; Indian Journal of Plastic Surgery; Year: 2015 | Volume: 48 | Issue: 3 | Page: 309--312.
[11] PROF. MIRA SEN (BANERJEE) C.M.E. ARTICLE ; K Agrawal, S Agrawal; Tissue regeneration during tissue expansion and choosing an expander. Indian Journal of Plastic Surgery; Year : 2012 ; Volume : 45 Issue : 1 Page : 7—15
[12] Gibson, T., and Kenedi, R.M.: Biomechanical properties of skin. Surg.Clin. North Am., 47:279, 1967.