ORIGINAL RESEARCH PAPER

Volume-8 | Issue-7 | July - 2019 | PRINT ISSN No. 2277 - 8179

INTERNATIONAL JOURNAL OF SCIENTIFIC RESEARCH

PROSPECTIVE STUDY OF JUVENILE NASOPHARYNGEAL ANGIOFIBROMA

ENT

Ashish Keche Department of Ear, Nose and Throat, Government Medical College, Nagpur, Maharashtra, India- 440021

Dr Prafulla Sakhare Associate Professor, VNGMC, Yavatmal

Dr Seema Patel* Associate Professor, GMC, Nagpur *Corresponding Author

ABSTRACT

Aims and Objectives: To study the role of various diagnostic modalities and to analyze the efficacy of pre operative embolisation in management of angiofibroma; lastly to evaluate the role of hormonal factors in pathogenesis of angiofibroma.

Material and Method: In present study, 31 patients diagnosed clinically and radiologically as a case of Juvenile Nasopharyngeal Angiofibroma. After diagnosis they were subjected for angiography and pre operative embolisation of feeding vessels. Usually after 20-40 emboli were introduced check angiography was done. Patients were treated surgically using various surgical approaches. After surgery, total intraoperative blood loss was calculated. In all patients serum testosterone assay was done using Elisa method.

Results: The mean age of the patient was found to be 17.8 years. The preoperative diagnosis was done by clinical findings and CT findings and the patient was staged accordingly. We found that internal maxillary artery was the most common feeder in all the cases. 26 patients underwent temporary embolisation using gel foam and 5 patients underwent permanent embolisation using PVA particles. Blood loss was not so severe, only one patient had blood loss around 2350 ml. Serum testosterone was found raised in one patient and normal in 30 patients.

Conclusion: Juvenile Nasopharyngeal Angiofibroma was clinically diagnosed and should be managed by surgery, without much bleeding intraoperatively due to preoperative embolisation and minimal recurrence and there seems to be a role of androgen in pathogenesis of angiofibroma.

KEYWORDS

Juvenile Nasopharyngeal Angiofibroma (JNA), Embolization, Angiography, Pathogenesis, androgen

INTRODUCTION

Juvenile Nasopharyngeal Angiofibroma is a highly vascular, benign but locally invasive and destructive fibrovascular neoplasm, with a tendency to local recurrence. It is a rare lesion occurring predominantly in adolescent male.[1,2] and accounts for less than 0.5% of neoplasm of head and neck tumours.[1,2].The reported incidence from 1/5000 to 1/50,000 (one new case per 5000 to 50,000 patients) of otolaryngological admissions in hospitals of different countries.[3] The management of JNAs is a challenge owing to their rich vascular supply, complex adjacent anatomical structures and aggressive growth pattern[4]. Although angiofibromas are histologically benign, it may act in an aggressive fashion characterized by recurrences that may extend into and destroy the adjacent bony structures. The tumor is extremely vascular and found in the nasopharynx.[1,2] The major causes for concern are recurrent life threatening epistaxis and symptoms associated with space occupying lesion of the nasopharynx.[1,2]

JNA originating from area surrounding sphenopalatine foramen commonly presents with nasal obstruction and epistaxis. The extent of JNA growth is studied clinically and radiologically by contrast enhanced computerized tomography (CT) scan and staged accordingly [5]. CT is best utilized for determining bony changes and magnetic resonance imaging (MRI) for soft tissue destruction[6]. Due to the vascular nature of JNA, angiography is often performed to identify the primary vessels that feed the tumor and allow for embolization to reduce intraoperative blood loss[7]. Surgery is considered to be the gold standard JNA treatment. Other treatment options include radiation therapy (external beam), chemotherapy and hormone therapy antiandrogen (flutamide)[8]. Several authors are reporting the use of endoscopic excision for JNA limited to nose and pterygopalatine fossa [9,10]

Being a highly vascular tumor, surgical excision of angiofibroma carries a significant risk of intraoperative bleeding. But due to emergence of newer interventional modalities and help of pre operative embolisation of feeders of tumor mass, intraoperative bleeding hardly trouble the head and neck surgeons. But despite such extensive and efficient management modalities there are high rate of residual and recurrences attributed to angiofibroma and it causes a lot of burden on health care.

The purpose of this study is to present a clear clinical and pathological picture of angiofibroma to emphasise on treatment modalities and blood loss during surgery and also to look for role of embolisation in reducing the blood loss.

MATERIAL AND METHOD

A prospective hospital-based study carried out to analyze 31 consecutive cases of Juvenile Nasopharyngeal Angiofibroma (JNA) operated at Government Medical College, Nagpur, India. All the patients of adolescent age group having the history of nasal obstruction and epistaxis and on clinical examination showing nasal mass and mass in nasopharynx, come to ENT O.P.D were included in the study. Initially, a detailed case history, physical examination with emphasis in lesion of head and neck were done for all the patients. Clinically all the patients seem to be JNA was subjected to radiological investigation (including X ray PNS, X ray Nasopharynx and CT PNS) and nasal endoscopy for confirmation of diagnosis. The patients were staged both clinically and radiologically prior to surgical treatment using Fisch classification of staging (Table 1).

Table 1. Fisch Staging System

Types	Details
I	Tumor limited to the nasopharyngeal cavity; bone destruction negligible or limited to sphenopalatine foramen.
II	Tumor invading the pterygopalatine fossa or the maxillary, ethmoid or sphenoid sinus with bone destruction.
III	Tumor invading the infratemporal fossa or orbital region • Without intracranial involvement • With intracranial extradural (parasellar involvement).
IV	Intracranial intradural tumor • Without infiltration of the cavernous sinus, pituitary fossa or optic chiasm • With infiltration of cavernous sinus, pituitary fossa or optic chiasm.

All the patients underwent measurement of serum testosterone by using Elisa method with an aim to look for role of androgens in pathogenesis of Juvenile Nasopharyngeal Angiofibroma. After diagnosis of JNA patients were advised to undergo angiography and preoperative arterial embolization prior to surgery. Then saline was injected to prevent reflux into the intracranial circulation. Usually after 20-40 emboli were introduced check angiography was done. Check angiography reveals decreased in blushing of tumor mass and then procedure is terminated.

The surgery of patients was planned within 48 hours of embolisation and patients were treated surgically using various surgical approaches

like lateral rhinotomy, transoral, endoscopic, weber fergueson and transpalatal approach depending on their JNA stage. During surgery general anaesthesia was given with throat packing done. All patients received labetalol to maintain intraoperative blood pressure between 90/60 mmhg so as to reduce intraoperative blood loss.

After surgery patient is packed with anterior nasal pack and post nasal pack which was kept for 48 hrs. The intraoperative blood loss is calculated by measuring amount of blood collected in suction machine bottle and substracting amount of Normal saline used for flushing purposes. Additionally we measure weight of blood soaked mops and deducted it from weight of normal mops and accordingly blog loss using mops was calculated (1gm=1ml). Then total intraoperative blood loss is calculated by addition of blood lost in suction and blood loss in mops. Blood transfusion was given to patient according to intraoperative blood loss and post operative haemoglobin status.The patients were followed up post operatively for a period of 3 months minimum.

OBSERVATION AND RESULTS

During the period under study, a total of 31 patients were studied. All patients were male, with a mean age of 17.8 years (12-22 years). The staging outlined in Table No.2 shows that 17 out 31 cases had stage III (54.84%) lesions,11 patients had stage II (35.48%) and 3 patients were of stage I (9.68%). Out of 17 stage III patients, 5 showed intracranial extension. Nasal obstruction was most common complaints and seen in all cases. The next most common symptom was epistaxis (28 cases i.e. 90.32%) followed by cheek swelling which was present in 17 patients (54.84%).Other symptoms were hyponasal speech, rhinorrhea, headache, facial pain and eye swelling. 3 patients did not have complaint of epistaxis which may be attributed to smaller size of the tumor mass as all these patient have small size of tumor on CT PNS and belongs to stage II.

On angiography we found that internal maxillary artery was the most common feeder and found in all the cases. Along with Internal maxillary artery concurrent supply with Internal Carotid artery was found in 5 patients. None of the patient shows supply from ascending pharyngeal arteries and vertebral arteries. After embolisation of feeding vessels all patients was underwent surgical excision. Total surgical excision was a treatment of choice in our study and in most of the patients the mass was removed by lateral rhinotomy approach used in stage III patients. Stage II and stage I patients was managed by transoral and endoscopic approach (Figure 1).

Table 3 and 4 depicted the intraoperative blood loss and blood transfusion required during surgery respectively. Blood loss was not so severe due to preoperative embolisation and most of the patients require 1-2 units of blood transfusion. Only one patient had blood loss around 2350 ml which is due to traumatic aneurysm of internal maxillary artery.

Serum testosterone was found raised in one patient (13.16 mg/ml) and normal in 30 patients. Recurrence and residual tumor was found in 4 and 3 cases respectively. After using anti androgen in 6 patients for 6 weeks, 5 patients shows reduction in the tumor volume but does not shows complete regression of tumor. The average tumor volume reduction was found to be 1.04 cu cm.

DISCUSSION

The patients in second decade of life which emphasise on the importance that Juvenile Nasopharyngeal Angiofibroma are a disease of adolescent age group. All the 31 patients were males between the ages 12–22 years with an average age of 17.8 yrs and no female case was reported in the present series which was comparable to the observations made in the literature.

The significance of staging of tumor lies in their application for proper surgical approaches so as to excise tumor with ease. We have staged the tumor according to Fisch classification for proper management and staging of tumor was done on the basis of CT PNS findings. In our study 17 patients belong to stage III out of which 5 cases had intracranial extension of tumor. The importance of this lies in the fact that such patients might require neurosurgical intervention and considerable precaution is taken during excision of tumor to avoid CSF leak. Any CSF leak occurring as a complication of surgery can be better managed using neurosurgical backup. In present study none of the patients having intracranial extension develops CSF leak. The stage III patients were managed by lateral rhinotomy approach. One patient was being operated using Weber Fergueson incision. In the study11 patients belong to stage II and 3 patients belong to stage I which was managed by transoral, endoscopic and transpalatal approach thus avoiding external incision.

According to literature review most surgeons afraid for surgical excision of tumor considering the troublesome bleeding occuring during the excision of tumor. If the tumor excision was attempted it was associated with high morbidity. But with the introduction of preoperative embolisation of feeding vessels the tumor can be excised with comparably less bleeding. In our study all patients underwent preoperative embolisation prior to surgical excision and shows Internal Maxillary artery as a primary feeding vessel of tumor. Some patients shows supply from ipsilateral Internal Carotid Artery (which could not be embolised). Our initial patients were permanently embolised using PVA particles. But after PVA particles was banned by FDA, temporary embolisation done with gelfoam showing same efficacy. We reported that internal maxillary artery was the most common vessel supplying Juvenile Nasopharyngeal Angiofibroma. Similarly Glenn Roberson et al[11] and Zeba Ahmed et al[12] also shows internal maxillary artery as a common feeding vessel. In the study one patient having large tumor with intracranial extension and other patient developing the traumatic aneurysm of internal maxillary artery during embolisation and requiring post operative temporary embolisation.

In the present study blood loss ranges from 150 ml to 2350 ml, majority of the patients had intraoperative blood loss between 500-1000 ml. Two patient shows blood loss of more than 2000 ml. The average blood loss was 865 ml which was comparable to other studies mentioned in literature[11-19]. The blood transfusion requirement was maintained on the basis of intraoperative blood loss, intraoperative vitals and post operative haemoglobin. Thirty patients in our series require blood transfusion. Most of the patients require either 1 or 2 units of blood transfusion. So considering this we can conclude that preoperative embolisation plays a vital role in decreasing the intraoperative blood loss and thus associated morbidity.

On measurement of serum testosterone using ELISA method, only one patient show marginal raised level of serum testosterone (13.16 ng/ml) and rest of the patients shows normal level of serum testosterone. However 3 patients had residual tumor and 4 patients had recurrence of tumor of which 1 patient opted for surgical excision. We started tab Flutamide in 6 patients for a period of 6 weeks and pre treatment CT PNS and post treatment CT PNS done to look for tumor volume reduction. 5 of the 6 patients showed reduction in tumor volume but no patients shows complete regression of tumor. On applying paired T test we found p value <0.05 (0.025) which was stastically significant. The patients were in close follow up and CT PNS done every 3 monthly which did not shows any increase in the tumor mass. Our study comparable with the study of Alok Thakkar et al[20]and A.M.Shenoy et al[21]. So considering the age group and effect of flutamide on reduction of tumor volume, we found that there was a possible role of hormonal factors in pathogenesis of angiofibro.ma but further research is needed to elaborate the same.

CONCLUSION

In conclusion, Juvenile Nasopharyngeal Angiofibroma was a disease which can be clinically diagnosed and should be managed by surgery, without much bleeding intraoperatively due to preoperative embolisation and minimal recurrence and there seems to be a role of androgen in pathogens is of angiofibroma which needs further studies and evaluation.

ACKNOWLEDEMENT

We sincerely thank the Department of Ear, Nose and Throat, Government Medical College, Nagpur, Maharashtra, for providing facility and granting permission to carry out the work.

Table 2. Stage distribution of patients according to Fisch Classification

Stage	No of patients	Percentage
Stage I	3	09.68%
Stage II	11	35.48%
Stage III	17	54.84%
Stage IV	00	00%

Table 3. Blood loss during surgery

Blood loss in ml	No of patients	Percentage
100 to 500 ml	01	03.23%
500 to 1000 ml	17	54.83%
1000 to 1500 ml	07	22.58%
1500 to 2000 ml	04	12.90%
2000 to 2500 ml	02	06.45%

Table 4. Blood transfusion required during surgery

No of blood transfusion (in Units)	No of patients	Percentage
0	01	03.23%
1	08	25.81%
2	15	48.38%
3	04	12.90%
4	02	06.45%
5	00	00%
6	00	00%
7	00	00%
8	01	03.23%

Figure 1. Diagrammatic presentation of various surgical approaches used for surgery

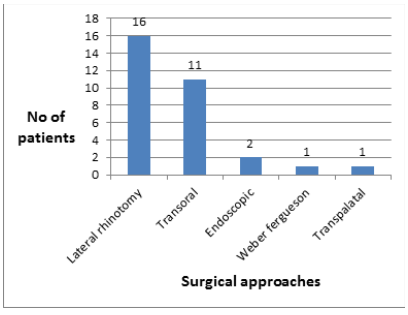

REFERENCES

1. Scott-Browns textbook of otolaryngology and Head and neck Surgery,7th Edition:Angiofibroma by Michael Gleeson.
2. Scott-Browns textbook of otolaryngology and Head and neck Surgery,6th Edition:Angiofibroma by O.H.Shaheen.
3. Schiff- Juvenile Nasopharyngeal angiofibroma:- A theory of pathogenesis Laryngoscope 1959; 8:981-1016.
4. Renkonen S, Hagström J, Vuola J, et al. The changing surgical management of juvenile nasopharyngeal angiofibroma. Eur Arch Otorhinolaryngol. 2011;268(4):599-607.
5. Moorthy PNS, Ranganatha B Reddy, Hamid Abdul Qaiyum, Srivalli Madhira, and Srikanth Kolloju. Management of Juvenile Nasopharyngeal Angiofibroma: A Five Year Retrospective Study. Indian J Otolaryngol Head Neck Surg. 2010; 62(4): 390–394.
6. Lloyd G, Howard D, Phelps P, Cheesman A. Juvenile angiofibroma: the lessons of 20 years of modern imaging. J Laryngol Otol 1999;113:127–134.
7. Moulin G, Chagnaud C, Gras R, et al. Juvenile nasopharyngeal angiofibroma: comparison of blood loss during removal in embolized group versus nonembolized group. Cardiovasc Intervent Radiol 1995;18:158–161.
8. Blount A, Riley KO, Woodworth BA. Juvenile nasopharyngeal angiofibroma. Otolaryngol Clin N Am. 2011;44(4):989-1004.
9. Mitskavich MT, Carrau RL, Synderman CH, Weissman JL, Fagan JJ. Intranasal endoscopic excision of a juvenile angiofibroma. Auris Nasus Larynx (1998);25(1):39-44.
10. Arne W. Scholtz, Elisabeth Appenroth, Keren Kammen -Jolly, Lars U. Scholtz, Walter F. Thumfart. Juvenile Nasopharyngeal Angiofibroma:Management and Therapy. Laryngoscope (2001);(4):681-687.
11. Glenn H. Roberson, Ann C. Price, James M. Davis, Amar Gulati : Therapeutic Embolization of Juvenile Angiofibroma:Asian Journal of Rhinology:133;1979:657-653.
12. Zeba Ahmed, Salman Mutiullah, Danish-Ur-Rahim and Muhammad saleem Marfani: Juvenile nasopharyngeal angiofibroma:stage and surgical approach: JLUMHS 2009;8(1):37-40.
13. Andrews JC, Fisch U, Valavanis A. The surgical management of of extensive nasopharyngeal angiofibroma with the infratemporal approaches.Laryngoscope. 1989; 99:429-437.
14. Sheldon P.E. et al., A rapid immunoassay for serum testosterone.steroids. 1977; 30:149.
15. Isteraj Shahabi,M Rafiq khan and Abdur Rashid:Management of Juvenile nasopharyngeal angiofibroma- a study of 20 cases.JPMI. 1995;9(1):26-32.
16. Ted L Tewfik, Andre K., W.Tan, Khalid Chowdhury, Donatella Tampeiri, Jean Raymond and Te Vuong : Juvenile Nasopharyngeal angiofibroma : The journal of otolaryngology. 1999;28:145-151.
17. Sinha A, Gupta S :Nasopharyngeal Angiofibroma : Staging + and management – A review of the case series report; Indian Journal of otolaryngology and head and neck surgery. 2000;52(4):366-370.
18. Desarda KK, Pande Bora MP. : Importance of preoperative embolisation in the surgery of nasopharyngeal angiofibroma. Indian Journal of Otolaryngology and Head Neck Surgery. 1998;50:36-39.
19. John M. Hodges AS. Mc devitt, ME. Sebelik: Juvenile nasopharyngeal angiofibroma:current treatment modalities and future considerations:Indian Journal of otolaryngology and head and neck surgery. 2010;62(3):236-247.
20. Thakkar A, Gupta G, Bhalla A, Jain V, Sharma R:Adjuvant therapy with flutamide for presurgical volume reduction in Juvenile nasopharyngeal angiofibroma:Head and neck. 2011:1747-1753.
21. Shenoy AM, Grover N, Janardahan N, Jayakumar PN, Hedge T, Satish S. Juvenile nasopharyngeal angiofibromas:A study of recurrence pattern and role of pre operative embolisation-A decade experience:Indian Journal of otolaryngology and head and neck surgery. 2002;54(4):274-279.