Volume : 4 | Issue : 6 | June 2015 • ISSN No 2277 - 8179

Research Paper

Medical Science

KEYWORDS :

Prostate Biopses :A Five Year Study at a Tertiary Care Centre

Dr. Poonam Burdak	Resident Mahatma Gandhi Medical College and Hospital, RIICO Institutional Area, Sitapura, Jaipur.
Dr. Narayani Joshi	Professor and Head Of Department Mahatma Gandhi Medical College and Hospital, RIICO Institutional Area, Sitapura, Jaipur.
Dr. B.P.Nag	Professor, Mahatma Gandhi Medical College and Hospital, RIICO Institutional Area, Sitapura, Jaipur.
Dr. R.M.Jaiswal	AssociateProfessor Department of Pathology Mahatma Gandhi Medical College and Hospital, RIICO Institutional Area, Sitapura, Jaipur.

ABSTRACT

BACKGROUND

Intussusception is one of the classic subjects of paediatric surgery.It is defined as telescoping of one segment of bowel into other. It is one of the most common paediatric emergencies, and an important cause of small bowel obstruction in children: if left untreated leads to fatal complications.

AIM

To study the clinical profile of paediatric patients with intussusception in a tertiary care hospital.

PATIENTS AND METHODS

A prospective case series study of 50 children admitted to a tertiary care Hospital,Hyderabadwith a diagnosis of acute intussusception between May 2012 to April 2014 were included in the study.All children clinically suspected of having intussusception were evaluated by real time ultrasonography and those with positive findings were entered into the study.

RESULTS

Male preponderance was observed in our study with predominant symptoms being excessive crying/Abdominal pain 100%(50 cases), followed by vomiting and mass per abdomen 80% (40).Most of the cases were idiopathic type and 22% (11) cases were secondary to lead points most common lead points being mesenteric lymph nodes 54.5% (6) cases followed by Meckel's diverticulum and gut associated lymphoma seen in 18.1% (2) cases..The most common type of intussusception was found to be ileo-colic with 62% (32) cases being reported.

INTRODUCTION

- The prostate gland is the largest accessory sex organ in the males (1). Prostate gland occupies center stage in the lives of many elderly males. Because of its location at bladder neck, enlargement of the gland leads to problems related to urinary obstruction .Incidence of prostatic disease, Nodular Hyperplasia (NH) and carcinoma increases with age. Recently there has been a significant advance in understanding of various prostatic diseases.
- Benign prostatic hyperplasia (BPH) is a common urological condition in men. The prevalence of BPH increases from 20% at 40 years of age to 90% by the eighth decade of life(2). Prostate cancer is an important growing health problem, presenting a challenge to urologists, radiologists and pathologist(3,4). Carcinoma of the prostate is the most common malignant tumor in men over the age of 65 years(5),. Prostatic carcinoma is globally the second most frequently diagnosed cancer and the sixth leading cause of cancer death in males (6). In India, it constitutes about 5% of all male cancers (7).
- Prostate-specific antigen (PSA), digital rectal examination, and transrectal ultrasound are the tools most commonly used to screen for prostate cancer. However, biopsy remains the gold standard for final diagnosis. Histological diagnosis of prostatic cancer is usually based on morphological features such as growth pattern, nuclear atypia, and absence of basal cells.

AIMS AND OBJECTIVES

1). To study the incidence of various morphologic types of prostatic lesions encountered at MGMC jaipur.

2). To study the age incidence, clinical manifestations and their correlation with benign and malignant lesions.

3). To study the mimickers of prostatic carcinoma like basal cell hyperplasia, squamous metaplasia ,nodular hyperplasia and atypical adenomatous hyperplasia

4). To study the incidentally detected prostate carcinoma and prostate carcinoma found in a screening program.

5). To know the incidence of Benign Prostatic Hyperplasia in TURP specimens.

6). To study the histomorphological spectrum of non-neoplastic and neoplastic lesions of the Prostate in TURP specimens.

7). To study the association of Benign Prostatic Hyperplasia in different prostatic lesions.

8). To compare the current study with other studies.

MATE-RIALS & METHODS

- This was a cross-sectional study of 775 cases of prostate biopsies diagnosed in the Department of Pathology in a large tertiary care teaching hospital in Jaipur Rajasthan India from January 2009 to Dec 2013.

- The present study included prostatic tissue specimen received in the pathology laboratory at Mahatma Gandhi Medical College Jaipur during the period from December 2013 to January 2009. Brief clinical data were noted from the case records, which included the age presenting symptoms, digital rectal examination findings, serum PSA levels, urine retention and clinical diagnosis. The specimens thus obtained were fixed in 10% formalin after detailed and careful examination. In case of TURP, approximately 5gm of tissue was processed in one cassette and embedded. The entire tissue was processed in case of TURP and needle biopsy and in cases of prostatectomy representative bits were processed.

Then sections 4 to 6 microns thick were prepared. Other special stains like Alcian blue pH 1, periodic acid schiff (PAS) and Zie-

Volume : 4 | Issue : 6 | June 2015 • ISSN No 2277 - 8179

hl Neelson were performed wherever necessary. The procedure followed for tissue processing and staining technique are those given in "Cellular Pathology technique" by CFA Culling.(15)

All the lesions were graded into non-neoplastic and neoplastic lesions. The cases of prostatic adenocarcinoma were graded using Gleason microscopic grading. The clinical and histological data so obtained were analyzed and compared with another similar studies.

RESULTS

- The present study constituted a total of 775 cases. All prostatic specimens were broadly classified into nonneoplastic and neoplastic. The age distribution of nonneoplastic and neoplastic lesions is depicted in Table 1. Non neoplastic lesions were more commen and was observed in 716 of the 775 cases (92.4%) Maximum numbers of Nonneoplastic lesions were seen in the age group of 61 to 70 years.

Table 1: Age distribution of the patients.

Age	Nonneoplastic n(%)	Neoplastic n(%)
Age (yr)	Nonneoplastic n (%)	Neoplastic n (%)
<50	78(11)	02(3.4)
51-60	190(26.5)	16(27)
61-70	300(42)	18(30.5)
71-80	123(17)	16(27)
81-90	22(03)	07(12)
>90	03(0.4)	00(00)
Total	716	59

- BPH was the most frequent finding and was observed in 619 of the 775 cases (79.87%). Maximum numbers of lesions were seen in the age group of 61 to 70 years. BPH was associated with acute and chronic prostatitis in 103 cases (13.3%), granulomatous prostatitis both nonspecific and tubercular in 10 (1.3%), basal cell hyperplasia (BCH) in 01 (0.1%), nodular hyperplasia in 06 (0.8%) , infarct in 03 (0.4%), squamous metaplasia in 11 (1.4%) . One case of atypical adenomatous hyperplasia (AAH) and four cases of abscess formation constituted 0.1% and 0.5% of the total cases, respectively. Two cases of tubercular granulomatous prostatitis (0.2%) was seen during our study period.

- The majority of cases in the neoplastic group were encountered in the age group of 61 to 70 years . Prostatic adenocarcinoma accounted for almost all neoplasms of the prostate gland. Most of the patients presented with symptoms of urinary obstruction, frequency of micturition, nocturia and hesitancy. No of cases with incidentally detected prostate cancer were 45(76.27%). No of cases with aiready suspected prostate cancer were 14(23.27%) as given in table no 2 and 3 respectively . Of the 59 cases of prostatic adenocarcinoma, Gleason grading was done in 46 cases. The majority of cases were of an intermediate grade (n=19, 41.30%), followed by low grade (n=18, 39.13%) and high grade (n=08, 17.39%). No grading and scoring was done in 13 cases because of the paucity of tissue and lack of specific pattern.

Table 2: Incidentally Detected Prostate Cancer.

Features	No/Total No. (%) of cases
No of cases with incidentally detected prostate cancer	45/59 (76.27%)
Poorly differentiated adenocarcinoma	10/45(22.22%)
Moderately differentiated adenocarcinoma.	32/45 (71.11%)
Well differentiated adenocarcinoma	03/45(06.67%)
Gleasons score	
<6	14/45(31.11%)
7(3+4)	14/45(31.11%)
7(4+3)	02/45(4.44%)
8-10	04/45(8.89%)

Table 3: Already Suspected Prostate Cancer.

Features	No/Total No.(%) of cases
Suspected cases of prostate cancer	14/59(23.27%)
Poorly differentiated adenocarcinoma	03/14(21.42%)
Moderately differentiated adenocarcinoma	07/14 (50%)
Well differentiated adenocarcinoma	04/14(28.57%)
Gleasons score	
<6	5/14(35.71%)
7(3+4)	02/14(14.28%)
7(4+3)	01/14(7.14%)
8-10	04/14(28.57%)

DISCUSSION

Enlargement of prostate is an age related process and incidence increases with increasing age beginning in the forties. Prostatic specimens constitute a good percentage of the surgical pathology workload. This study was undertaken to evaluate the various histological lesions in prostatic specimens.

The age of the patients in our study ranged from 20 years to 95 years; however, the predominant population was in the 6th to 7th decade . No significant difference was noted in the age group of the nonneoplastic and neoplastic groups. The decline in the number of cases beyond the age of 80 years reflects the average life span of people in our country.

In our study, of 775 cases, 716 (92.4%) were nonneoplastic lesions, whereas neoplastic lesions constituted 59 of the total cases (7.6%). This agrees with the studies conducted by Mittal et al. (8), Anjorin et al. (9), and George et al. (10), in which nonneoplastic lesions formed the bulk of the cases. These results are shown in Table 4. Prostatitis was seen in 103 of 775 cases (13.3%). Mittal et al. [8] in a study of 185 prostatic specimens reported that prostatitis constituted 38.4% of the cases, of which 26.3% of cases were chronic prostatitis, and acute prostatitis with or without abscess formation was noted in 12.1% of cases.

Granulomatous prostatitis was seen in 10 of 775 cases (1.29%). Two of 10 cases showed tuberculoma granulomas ,rest were nonspecific granulomas. BCH (basal cell hyperplasia) accounted for 0.13% (01 cases) of the total cases. The present study showed squamous metaplasia in 11 cases, accounting for 1.42% of the total cases.

In the present study, one case of AAH(atypical adenomatous hyperplasia) was observed, constituting 0.13% of the total cases. This is comparable to the reported incidence of less than 1% by Hameed and Humphrey (11), who stated that AAH is invariably an incidental histological finding, usually localized in the transi-

tion zone, and is thereby seen more often in transurethral prostatectomy chips.

- Carcinoma of prostate is common cancer in India due to increasing life expectancy and relatively better diagnostic method(14). The prevalence of prostatic carcinoma in the present study was 7.6%, i.e., 59 of 775 cases. Similar results were obtained by Mittal et al. (8) and George and Thomas (10). Most cases of prostate cancer are diagnosed after 50 years of age, but prostate cancer can be seen in younger adults. The frequency increases with age. 45 of the total 59 cases (76.27%) of prostate cancer were detected incidentally on biopsy while rest of the 14 cases(23.27%) had already suspected prostate cancer.

In the present study, the age range was widespread i.e (20–95 years) . However, the majority of cases (n=18, 30.5%) were seen in the age group of 61 to 70 years, closely followed by the age group of 71 to 80 years. Two cases were seen below the age of 50 years and no case was seen above the age of 90 years. Histological grade has been recognized as a powerful prognostic predictor of prostate cancer. Various other studies including ours highlight a score of 7 to 8 as a predominant score (10,12,13).

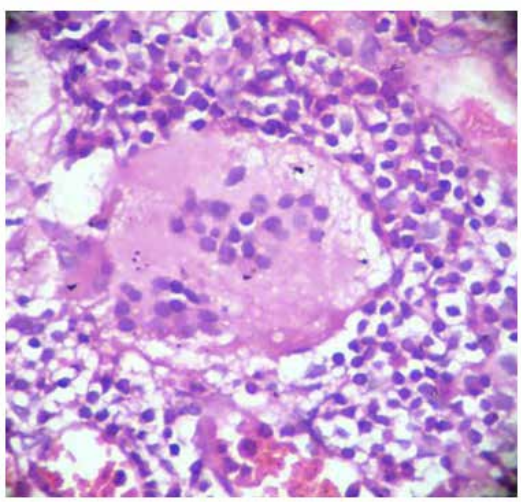

Fig 1: Photomicrograph of Non specific granulomatous prostatitis showing multinucleated giant cell and histiocytes. (40x)

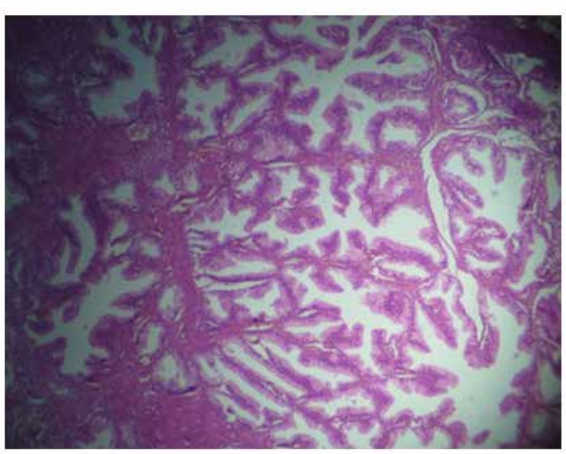

Fig 2: Photomicrograph of Benign prostatic hyperplasia (10x)

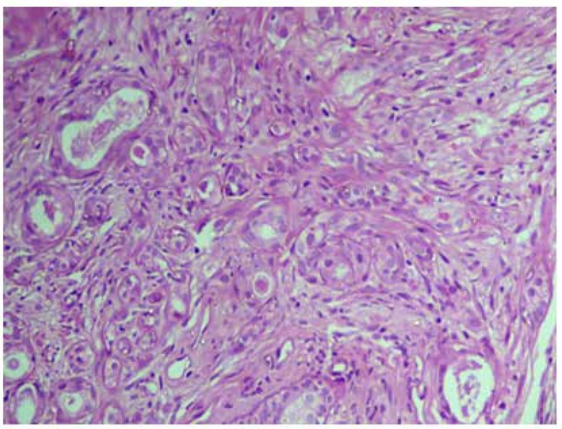

Fig 3: Photomicrograph of Adenocarcinoma – Gleason's grade 2 (10x)

CONCLUSION

Out of 775 prostatic specimens studied Nonneoplastic lesions were common, which accounted for 92.4% and Neoplastic lesions accounted for 7.6%. Nonneoplastic lesions were common in the age group of 61-70yrs, with common symptoms of frequency, difficulty in voiding and acute retention.. BPH is the most common lesion of the prostate in the elderly and was commonly encountered in the age group of 61-70yrs. Chronic nonspecific prostatitis is the commonest inflammatory condition of the prostate and was commonly found in the age group of 61-70yrs. Granulomatous prostatitis ,Nodular hyperplasia, Basal cell hyperplasia Squamous metaplasia ,Atypical adenomatous hyperplasia are rarely encountered.

Malignant lesions showed a peak incidence in the age group of 61-70 years with a common symptoms of frequency, incomplete voiding and dysuria. Conventional adenocarcinoma is the commonest type of prostatic carcinoma accounting for 7.6% of the total cases. Gleason's microscopic grading was adopted for grading prostatic adenocarcinoma in which the commonest Gleason score was score 7 (35.55%), in incidentally detected prostate adenocarcinoma , while Gleason' score of <6 is the most common score in prostate carcinoma found in the screening program.

Volume : 4 | Issue : 6 | June 2015 • ISSN No 2277 - 8179

REFERENCE

(1) Anderson's pathology vol 1 edition 8 page 816. | (2). Lakhtakia R, Bharadwaj R, Kumar VK, Mandal P, Nema SK. Immunophenotypic characterization of benign and malignant prostatic lesions. Med J Armed Force India 2007;63:243-8. | (3). Ries LAG, Eisner MP, Kosary CL, et al. (eds). SEER Cancer Statistics Review, 1975- 2001, National Cancer Institute. Bethesda, MD, 2004. | (4). Sasagawa I, Nakada T. Epidemiology of prostate cancer in East Asia. Arch Andro 2001;47(3):195-201. | (5). Neal D. The prostate and seminal vesicles. In: Mann CV, Russel RCG, William NS, eds. Bailey and Love's short practice of surgery. 22nd ed. Chapman Hall; London: 1995. p 970–85. | (6). Dabir PD, Ottosen P, Hoyer S, Hamilton-Dutoit S. Comparative analysis of three- and two-antibody cocktails to AMACR and basal cell markers for the immunohistochemical diagnosis of prostate carcinoma. Diagn Pathol 2012;7:81. | (7). Consolidated report of population based cancer registries 2001-2004: incidence and distribution of cancer. Bangalore (IND): Coordinating Unit, National Cancer Registry Programme, Indian Council of Medical Research; 2006. | (8). Mittal BV, Amin MB, Kinare SG. Spectrum of histological lesions in 185 consecutive prostatic specimens. J Postgrad Med 1989;35:157-61. | (9). Anjorin AS, Adeniji KA, Ogunsulire IA. Histopathological study of prostatic lesions in Ilorin, Nigeria. Cent Afr J Med 1998;44:72-5. | (10). George E, Thomas S. A histopathologic survey of prostate disease in the sultanate of oman. Internet J Pathol 2005;3(2). | (11). Hameed O, Humphrey PA. Pseudoneoplastic mimics of prostate and bladder carcinomas. Arch Pathol Lab Med 2010;134:427-43. | (12). Coard KC, Freeman VL. Gleason grading of prostate cancer: level of concordance between pathologists at the University Hospital of the West Indies. Am J Clin Pathol 2004;122:373-6. | (13). Monika Garg, Gurmeen Kaur, Vineeta Malhotra, Ravish Garg Histopathological spectrum of 364 prostatic specimens including immunohistochemistry with special reference to grey zone lesions. Prostate Int 2013;1(4):146-151. | (14) Jasmin H. Jasani, Himani B.Patel,Bijol Gheewala ,Hetal V.Vaishnani,Kaushik Bhuva,Sankalp Sancheti, Anand Patel,Rakesh Tandon DIAGNOSTIC UTILITY OF PROSTATE SPECIFIC ANTIGEN FOR DETECTION OF PROSTATIC LESIONS International Journal of Biomedical and Advance Research (2012) 03(04) 268-72. | (15) Culling CFA, Allison RT, WT. Barr (editors). In Cellular Pathology technique; 4th edition: London; Butterworth and Co., 1985.