ORIGINAL RESEARCH PAPER

Volume-7 | Issue-10 | October-2018 | PRINT ISSN No 2277 - 8179

INTERNATIONAL JOURNAL OF SCIENTIFIC RESEARCH

PULMONARY HYDATID CYST PRESENTING AS CYSTOCUTANEOUS FISTULA- A CASE REPORT

Surgery

Dr. Sourabh Damani Senior Resident, Department of Surgery, LG Hospital

ABSTRACT

Hydatid disease or echinococcosis is a zoonosis that occurs primarily in sheep grazing areas of the world but is common worldwide because dog is a definite host1. It can produce a variety of symptoms like abdominal pain, dyspepsia, vomiting, jaundice and fever. Here we present a rare case of pulmonary hydatid cyst which presented itself as a cystocutaneous fistula.

KEYWORDS

Pulmonay Hydatid Cyst , Cystocutaneous Fistula, Rare Presentation

INTRODUCTION :

Hydatid disease is a parasitic infestation caused by *Echinococcus Granulosus* characterized by cystic lesions in the liver and lungs but rarely in other parts of the body[2,3]. Humans contract the disease from dogs but there is no human to human transmission.[1a,1b] They are diagnosed in equal numbers of men and women at an average age of 45 years [1].Approximately 75 % are located in the right liver and are solitary.[1]

Case Report: A 48 year old female patient from North India came with chief complain of discharge along with some solid whitish membrane like thing coming out from right lower chest wall. Patient had no other complain. She kept dogs,sheeps,pigs at her farm. On examining the patient, grape like material was found to be discharging which was sent for histopathology and was diagnosed as hydatid daughter cysts. The patient was a newly detected Diabetic and started on antidiabetic medications. Patient was started on albendazole and further workup was done. HRCT of the patient was done which showed mixed density lesion with internal multiple small cysts and with cystocutaneous fistula suggestive of hydatid cyst. There was 86x43x71 mm sized well defined lesion with peripheral calcification rim in right pleural cavity with erosion of shafts of right 5th and 6th ribs on lateral aspect.the lesion extended to 4th intercostals space in right anterior chest wall and communicated with 43x12 mm sized collection in subcutaneous plane through 38 mm long fistula . Subcutaneous collection opened through cutaneous opening in right anterior chest wall. The patient was taken to the OT and scolicidal agent was injected in the fistula tract and cyst cavity. The cyst cavity was then opened and the inner germinal membrane scrapped and the fistula tract excised . The wound was than sutured . In post op period the wound had to be reopened due to seropurulent discharge and daily dressing was done and later secondary suturing done .Patient was discharged on albendazole and antibiotics and on follow up was completely symptom free with healthy stitch line.

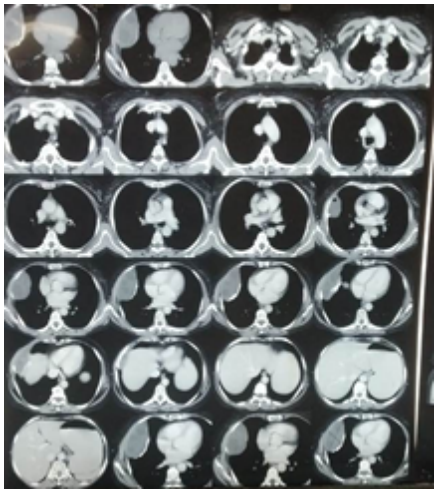

FIGURE 1: HRCT of the pulmonary hydatid cyst with cystocutaneous fistula

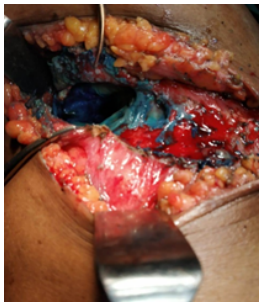

FIGURE 2: Intraoperative finding showing opened cyst cavity and fistula tract.



FIGURE 3 : Fistula tract and grape like daughter cysts .

DISCUSSION : It is endemic in Mediterranean countries, Middle East, Far East ,East Africa, South America ,Australia and New Zealand. [4]. The lungs are the second most common sites for hydatid cysts after the liver [2,3]. The majority of lung hydatid cysts are usually silent and either small or medium in size. Most asymptomatic hydatid cysts are usually discovered incidentally during routine chest X-rays for complaints other than chest diseases [5]. Large hydatid cysts and complicated cysts are usually symptomatic [6]. The common presentations are compression symptoms such as a dry cough ; a productive cough in cases associated with communication with the bronchial tree; and chest pain and dyspnoea in the case of rupture to the pleural cavity [6]. Anaphylactic shock is a rare presentation which occurs due to rupture in the pleural cavity. The patient is usually in good general health in cases of non-complicated cysts and chest X-ray will show a well-circumscribed dense homogenous opacity [7]. A water-lily radiological sign is a diagnostic feature for a cyst associated with communication with small bronchioles and with a detached laminated membrane [7]. Productive cough of grape skin-like material is diagnostic in ruptured hydatid cysts communicated with medium sized bronchioles [7] .In our case grape like material was seen coming out of the fistula tract and was the main complain of the patient. Hydatid cysts of the lung are usually treated medically with albendazole [4]. This medical treatment is effective for most small cysts where surgical intervention is not mandatory. Galanakis et al. [8] suggest that medical treatment alone can be sufficient for small pulmonary hydatid cysts. Larger cysts usually need surgical intervention in addition to albendazole (either pre-operative or pre- and post-operative). PAIR (Puncture,Aspiration,Injection and reaspiration)Intervention using scolicidal agent iis also successful in many cases. Complicated hydatid

cyst treatment consists of surgically and post-operatively administered albendazole only if daughter cysts are detected during the operation. This is in agreement with many other studies [4,5,8] recommending the administration of albendazole alone or in association with surgical treatment. The appropriate surgical intervention includes deroofing of the cyst followed by pericystectomy, marsupialization, leaving the cyst open ,drainage of the cyst.[1,9]

CONCLUSION : Hydatid cyst can present in a variety of ways and at various locations, so we should always treat it considering all common as well as rare possibilities like in our case discussed here .

REFERENCES

1. Sabiston Textbook of Surgery ,19th Edition 2012;pg-1447 .1448 1A : Dziri C, Haouet K, Fingerhut A, et al: Management of cystic echinococcosis complications and dissemination: Where is the evidence? World J Surg 33:1266–1273, 2009. 1B. Agayev RM, Agayev BA: Hepatic hydatid disease: Surgical experience over 15 years. Hepatogastroenterology 55:1373–1379, 2008
2. Kavukcu S, Kilic D, Tokat AO, Kutlay H, Cangir AK, Enon S, Okten I, Ozdemir N, Gungor A, Akal M, Akay H. Parenchyma-preserving surgery in the management of pulmonary hydatid cysts. J Invest Surg. 2006;19:61–68. doi: 10.1080/08941930500444586.
3. Safioleas M, Misiakos EP, Dosios T, Manti C, Lambrou P, Skalkeas G. Surgical treatment for lung hydatid disease. World J Surg. 1999;23:1181–1185. doi: 10.1007/s002689900643.
4. Ellaban A, Elzayat S, Elmuzaien M, Nasher A, Homesh N, Alabsi M. The effect of preoperative albendazole in the treatment of liver hydatid cysts. Egyptian Journal of Medical Laboratory Sciences. 1994;15:309–319.
5. Robert ES, Eugene JM, William FM, Sally HE, Stacey M. Case records of the Massachusetts General Hospital. Weekly clinicopathological exercises. Case 29-1999. A 34-year-old woman with one cystic lesion in each lung. N Engl J Med. 1999;341:974–982. doi: 10.1056/NEJM199909233411308
6. Saidi F. Treatment of Echinococcal cysts. In: Nyhus LM, Baker RJ, Fisher JE, editor. Mastery of Surgery. 3. Boston, New York, Toronto, London: Little, Brown & Co; 1997. pp. 1035–1052.
7. Beggs I. The radiology of hydatid disease. AJR Am J Roentgenol. 1985;145:639–648.
8. Halezeroglu S, Celik M, Uysal A, Senol C, Keles M, Arman B. Giant hydatid cysts of the lung. J Thoraco Cardiovasc. 1997;113:712–717. doi: 10.1016/S0022-5223(97)70228-9.
9. Ayles HM, Corbett EL, Taylor I, Cowie AGG, Bligh J, Walmsley K, Bryceson ADM. A combined medical and surgical approach to hydatid disease: 12 years' experience at the Hospital for Tropical Disease, London. Ann R Coll Surg Engl. 2002;84:100–105.