ORIGINAL RESEARCH PAPER

PRINT ISSN No 2277 - 8179

INTERNATIONAL JOURNAL OF SCIENTIFIC RESEARCH

RADIOLOGICAL EVALUATION OF CARPAL INSTABILITY ASSOCIATED WITH CONSERVATIVELY MANAGED FRACTURE OF DISTAL RADIUS.

Orthopaedics

Dr Pankaj Jain Prof., S M S Medical College,Jaipur

Dr Devendra Singh* Senior Resident, Dr S N Medical College, Jodhpur * Corresponding Author

Dr Nitin Goyal Junior Resident, Dr S N Medical College, Jodhpur

Dr Josal Patel Ex Resident, S M S Medical College,Jaipur

Dr Mahesh Bhati Senior Prof., Dr S N Medical College, Jodhpur

ABSTRACT

Distal radius fracture is one of the most common fractures of the forearm and accounts for approximately 16% of all skeletal fractures. Distal radial fractures are associated with injuries to the TFCC and carpal ligaments that may lead to carpal malalignment later. The purpose of this study was to assess the frequency of carpal instability on radiological basis following conservative management of distal radius fractures. Other objective was to identify other factors including carpal malalignment in an attempt to predict the final functional outcome.

In a prospective study, 100 distal radial fractures treated with conservative method were followed-up with serial radiographs for assessment of various radiological parameters. The alignment of each wrist was checked radiographically in pre reduction, immediate post-reduction and subsequently at 6-week follow-up radiographs. Serial measurements of radial length, dorsal tilt, radial inclination, scapho-lunate, radio-lunate, radioscaphoid, scapho-capitate angles and effective radiolunate flexion (ERLF) angle were made. Regression analysis showed high correlation among the severity of axial shortening, prereduction dorsal angulation and radio-carpal malalignment pattern with loss of reduction at 6 week. Two patterns of carpal malalignment were identified depending upon the effective radiolunate flexion (ERLF) measured on pre-reduction radiographs. The midcarpal malalignment was seen in 82% radial fractures with the lunate following the dorsiflexed fracture fragment and a measured ERLF of less than 250. The second pattern of radio-carpal malalignment showed the fracture fragment to dorsiflex without taking the lunate with a measured ERLF of more than 250. The scaphoid did not follow the fracture fragment in both the patterns of malalignment.

Our study highlights the importance of various radiological parameters on post-reduction radiographs as a predictor of carpal instability.

KEYWORDS

Carpal,ERLF,SLA.

INTRODUCTION

Carpal malalignment following the malunited distal radial fractures was described as "dorsal luxation of the capitate" in 1919 [9] and is the cause of the substantial morbidity even today [10, 11]. Carpal ligament instability results from injury to one or more ligamentous or bony constraints in the wrist. Distal radius fracture instability has been the focus of considerable interest for many years. A correlation between the severity of the primary displacement, carpal malalignment and an expected loss of reduction over a given time period has been reported in conservatively managed distal radius fractures [1, 2, 3]. The malalignment has been described to reflect an adaptation to realign the hand with the radial malunion at the midcarpal level [4], although another observation of compensatory angulation to realign hand to the forearm can also takes place at the radiocarpal level" has appeared[5]. Patients have also been reported to develop this adaptive carpal realignment during evolution of the malunion itself, or during and after the immobilization rather than after fracture healing[6]. Recently, an attempt has been made to classify carpal malalignments associatedwith displaced distal radial fractures in quantitative terms based on the effective radio-lunate flexion angle (ERLF) into two definite groups with possibly different aetiologies and prognosis[11]: midcarpal malalignment with ERLF <25° and radio-carpal malalignment with ERLF >25°. The midcarpal instability in which the proximal carpus tends to face dorsally in line with the dorsally angulated articular surface of the distal radius with a compensatory flexion of the capitate or midcarpus resulting in an unstable, zigzag collapse pattern of the wrist having ERLF<25° [7]. The second is dorsal subluxation of the carpus, which results in a global radio-carpal dorsal derangement with ERLF > 25°producing the dorsal subluxation of the radio-lunate joint [7,8]. The aim of this study was to radiologically assess the frequency of this carpal instability as a concomitant lesion to fractures of the distal radius, and evaluate further various factors including carpal malalignment based on ERLF [that are predictive of instability] in an attempt to predict the final radiological outcome more accurately. We measured various radial and wrist radiological parameters following distal radial fractures in pre-reduction, post-reduction and the follow-up films to measure accurately the displacement of the fracture and the associated carpal malalignments in quantitative terms with particular attention to proximal carpal row. Patients with malunited distal radial fractures were reported to develop gradual progression of the midcarpal malalignment after the healing of the fracture, which worsened with the continued loading of the wrist[5]. Carpal malalignment is not simply a complication but the inevitable response of the carpus to the altered mechanics caused by the malunion with dorsal radial tilt. However, it was our observation that the so described inevitable carpal realignment does not follow malunions of those fractures which are associated with dorsal subluxation of the radio-carpal joint. These fractures form nearly 11% of the total displaced distal radialfractures [4]. With such controversial reports regarding carpal malalignment following the distal radial fractures, we thought it worthwhile to study the incidence and the natural course of the various carpal malalignment patterns occurring secondary to the displaced distal radial fractures. The present study, therefore proposed to measure various radial and wrist radiological parameters following distal radial fractures in pre-reduction, post-reduction and the serial follow-up films with a view to quantify accurately the displacement of the fracture and the associated carpal malalignment.

The aim of this study was to radiologically assess the frequency of carpal instability as a concomitant lesion to fractures of the distal radius and evaluate further various factors including associated carpal malalignment based on ERLF that are predictive of instability in an attempt to predict the final radiological outcome more accurately. We measured various radial and wrist radiological parameters following distal radial fractures in pre-reduction, post-reduction and the serial follow-up films to measure accurately the displacement of the fracture and the associated carpal malalignments in quantitative terms with particular attention to proximal carpal row.

MATERIAL & METHODOLOGY

This prospective study comprised 100 patients with distal radial fractures presented in orthopedic outdoor and the accident emergency department at Medical college level in Rajasthan, India between April 2014 to December 2015. The mean age of the patients was 50.03 years (SD 16.33). There were 50 males and 50 females. Fractures were classified according to the AO-classification. The patients were grouped according to the type of the fracture. All patients underwent closed reduction and a below-elbow plaster cast applied up to the metacarpophalangeal joints with the wrist immobilised in neutral rotation, ulnar deviation, and slight flexion. Patients with open fractures, other musculoskeletal disorders, <18 years & who underwent a secondary manipulation at any stage or those patients who

underwent a secondary surgical intervention were excluded. The patients were radiographed before and soon after the reduction of the fracture and on follow-up at six-eight weeks after the injury. The detailed assessment made for the various radiographic parameters was as follows. Radial length in mm, Dorsal tilt in degrees, Scapholunate angle in degree, Radiolunate angle in degrees, Effective radio lunate flexion [ERLF] in degrees.

RADIOLOGICAL EXAMINATION[12] included :Posteroanterior (PA) and lateral view were obtained. The PA radiographs measured: Radial length: averages 9 mm with range of 8–14 mm.[13] The other parameters like scapho-lunate gap, ulnar variance, radial shift, articular incongruity and three Gilula's arcs etc. were not measured, as they were considered not relevant to the scope of the present study. The lateral radiographs measured: (a) Volar / Dorsal tilt: averages 11° with a range of 0–22° of volar tilt.[14] (b) Scapho-lunate angle (SLA): average 46° with a range of 30° – 60°.[15, 18] (c) Radio-lunate angle (RLA): averages 0° with a range of - 9° to +12°.[16](d)Effective radio-lunate flexion (ERLF): describes relative flexion of the lunate, appeared to have occurred secondary to the dorsal rotation of the distal radial articular surface.[17] It is calculated as: **Dorsal tilt + 11 (average volar tilt) - RLA.** Theoretically, a very precise calculation for ERLF would measure it as Dorsal tilt + (volar tilt measured on the un-injured wrist) - (difference between RLA of the un-injured wrist and RLA of the radiograph in question).

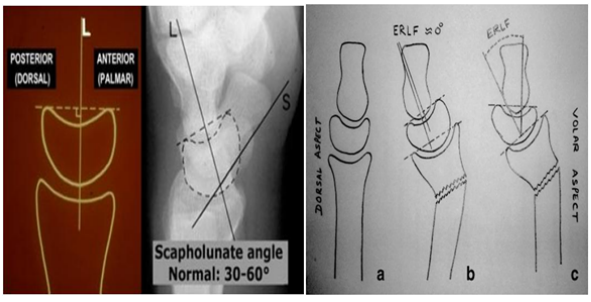

RESULTS

The measurement of ERLF made us identify two patterns of carpal malalignment: the first pattern was of the midcarpal malalignment with ERLF of less than 250, where the lunate also rotated dorsally along with the fracture fragment and maintaining nearly a collinear relationship with it. The second pattern was of the radiocarpal malalignment with ERLF of more than 250. It involved the fracture fragment rotating dorsally independent of the lunate. The lunate was seen placed precariously along a dorsally tilted distal radial articular surface, resulting in dorsal radio-carpal subluxation. The radio-scaphoid and the scapho-capitate angles did not show significant change among the pre, post-reduction or the follow-up films in both the patterns of fracture. There was a significant improvement in all the parameters measured ($p<0.05$) in pre- and post-reduction measurements with mean correction falling within acceptable limits. The mean improvement in various fracture characteristics described as (pre-reduction; post-reduction mean ± standard deviation, p value) was as follows: radial inclination (16.9± 5.9; 20.3±4.2, p=0.029); radial shortening (4.9±2.5; 0.89 ± 2.4, p=0.018); volar tilt (−15.7±12.3; −0.8±10.4, p=0.024).

Fractures were classified according to the Association for the Study of Internal Fixation (AO/ASIF) 19. The distribution of patients according to the type of the fracture and the pattern of malalignment is shown in Table 1.

Table 1: Distribution of the cases with type of fracture

	Midcarpal Instability		Radiocarpal Instability		Total
Type of #	No	%	No	%	No
A2	48	58.54	8	44.44	56
A3	8	9.756	2	11.11	10
C1	13	15.85	2	11.11	15
C2	9	10.98	2	11.11	11
C3	4	4.878	4	22.22	8
Total	82	100	18	100	100

Mean values of various radiographic parameters according to the type of carpal malalignments (Table 2, 3, 4)

Table 2: Mean values of various radiographic parameters according to the type of carpal mal alignments(Radial Height and Dorsal tilt)

Type of Instability		Radial Height			Dorsal tilt		
		Pre Reduction	Post Reduction	At 6 Wks	Pre Reduction	Post Reduction	At 6 Wks
Midcarpal Instability	**Mean**	4.67	9.33	6.09	22.93	4.76	14.89
	SD	2.155	2.859	2.363	15.16	9.03	11.12
Radiocarpal Instability	**Mean**	3.89	7.89	5.06	25.06	10.06	19.44
	SD	2.220	2.111	2.071	7.28	9.44	9.26
P Value		0.17ns	0.046S	0.09ns	.564ns	.028s	.109ns

No significant mean difference was observed in radial height according to the type of carpal mal alignments also in dosal tilt values except at post reduction period where mean value of dorsal tilt was significantly more in Radiocarpal Instability as compared to Midcarpal Instability.

Radial Height and Dorsal Tilt mean values were corrected in large numbers of the cases on post reduction but these values remain uncorrected in some extent at 6 wks follow up. Both values were remain uncorrected more in Radio carpal instability group.

Table 3: Mean values of various radiographic parameters according to the type of carpal mal alignments(SLA and ERLF) at different follow up period

Type of Instability		SLA			ERLF		
		Pre Red	Post Red	At 6 Wks	Pre reduction	Post Reduction	At 6 Wks
Midcarpal Instability	**Mean**	60.94	49.89	61.88	11.54	12.60	14.33
	SD	16.73	16.79	16.96	3.86	2.95	3.95
Radiocarpal Instability	**Mean**	53.44	49.83	51.39	32.67	18.50	27.28
	SD	8.09	8.07	8.91	4.24	4.64	4.44
P Value		.068	.989	0.013S	<0.001S	<0.001S	<0.001S

All the radiological parameters were independently analysed on the basis of midcarpal and radiocarpal patterns of malalignments based on ERLF. No significant mean difference was observed in SLA according to the type of carpal mal alignments except at 6 week period where mean value of SLA was significantly less in Radiocarpal Instability as compared to Midcarpal Instability. ERLF was significantly higher in all time in Radiocarpal Instability group as compared to Midcarpal Instability group.

Table No 4. Mean values of RLA at different follow up period

Type of Instability		RLA (-9 to12)		
		Pre Reduction	Post Reduction	At 6 Wks
Midcarpal Instability (n=82)	Mean	22.34	3.18	11.67
	Std. Deviation	13.592	7.621	8.490
Radiocarpal Instability (n=18)	N	18	18	18
	Mean	2.94	2.56	3.00
	Std. Deviation	4.465	5.512	5.499
P Value		<0.001S	0.74NS	<0.001S

No significant mean difference was observed in RLA according to the type of carpal mal alignments in pre reduction but at 6 week and post reduction period where mean value of RLA was significantly less in Radiocarpal Instability group as compared to Midcarpal Instability group.

Case 1: Pre reduction AP and LAT radiographs showing increased SLA with normal radial height and dorsal tilt.



Post reduction AP and LAT radiographs showing increase normal radial height and dorsal tilt.



AP and LATERAL radiographs at 6 weeks showing increased SLA with normal radial height and dorsal tilt.

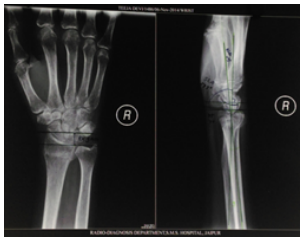

Case 2: Pre reduction AP and LATERAL radiographs showing increased dorsal tilt with distal radial fractured fragment and lunate is not in collinear fashion in lateral view showing radio-carpal instability with ERLF > 25 degree



Post reduction AP and LATERAL radiographs showing normal radiological parameters.



AP and LATERAL radiographs at 6 weeks showing distal radial fractured fragment and lunate is not in collinear fashion in lateral view showing radio-carpal instability with ERLF > 25 degree.



DISCUSSION

The average age of patients in our study was 50.03 years. Colles' fracture is classically described in osteoporotic bones and in old age but intra-articular fractures, which represents a fair percentage of distal radius fracture, occurs mainly in young individuals with good bone stock. This signifies the importance of differentiating intra-articular fractures from extra articular fractures. The male to female ratio in this study was 1:1. The younger age (<40 yrs) group 33 % of patients in this study can be explained by the fact that this group is more prone to high velocity trauma in comparison to older age (>40 yrs) group who lead a more domestic and sedentary life, especially in our subcontinent. Here the population group sustaining this injury is different from osteoporotic post-menopausal women sustaining Colles' fracture. In this study, relationship between final result and sex of patient is not significant. We have used AO classification[20] to classify these injuries as it is comprehensive and specific to such injuries. The dominant wrist was involved in 41% of cases in our study. The relationship between final results and injury to dominant or non dominant wrist does not appear to be significant.

Midcarpal and Radio-carpal instability was present in 82% and 18% of patients respectively. We also found that pre reduction radiological parameters were improved in immediate post reduction film but again malaligned on subsequent film at 6 weeks (table2, 3, 4) .The same instability pattern reappeared with the redisplacement of the fractures and occurred during the immobilization itself rather than as a later compensatory mechanism of the malunion. This is also supported by previous studies[21,22].

In our study, radial shortening was in 87% of cases initially which was restored and remain abnormal only in 27% of cases at immediate post reduction and finally radial shortening was present in 74% of cases at 6 weeks. Abnormal dorsal tilt,scapho-lunate angle and radio-lunate angle were restored from 55 %, 48%, 69% of cases respectively at pre reduction to 1%, 27%, 5% of cases respectively at post reduction and at 6 weeks final abnormal values of these radiological parameters were in 31 %, 49%, 46% of cases respectively .The mean values of the various radiological parameters on pre reduction, post reduction and at 6 weeks were also similar to previous studies.[21,22]

Carpal angles measure the alignment of the carpal bones in relation to the longitudinal axis of the radius, but are unable to serve the desired purpose due to the fixed and constant relationship between the longitudinal axis of the radius and its articular surface in an unbroken radius. That is why ERLF (effective radio lunate flexion) appears to be a more appropriate measurement in patients with fractured distal radius, as it takes into account the influence of dorsal tilt and RLA.[22] On the basis of effective radio lunate flexion (ERLF), carpal malalignments are classified into two groups, midcarpal and radio-carpal malalignment. , [1,2].Those fractures in which ERLF is $<25^0$ are considered to belong to midcarpal instability group. Here neither the radiocarpal capsule nor the carpal ligaments are disrupted; the malalignment merely reflects the adaptation to the malunion at the midcarpal level with the lunate moving with the fracture fragment like a composite radio-lunate complex. Fractures showing more than 25° of ERLF are described as having the radio-carpal malalignment pattern, which denotes an excursion definitely beyond the physiological range. Here the fracture also results in a global radio-carpal dorsal derangement producing the dorsal radiocarpal subluxation as the lunate contact area translates dorsally[7, 19]. It involves the fracture fragment rotating dorsally independent of the lunate. Gong et al. in an experimental study suggested an associated injury to the radio-carpal ligaments to explain the occurrence of such an injury pattern[23]. We agree with previous reports that fractures when redisplaced seem to develop a radiocarpal malalignment pattern both during and after immobilisation[1, 7, 24]. Batra et al. in their study included conservatively treated distal radius fractures and those managed with internal/external fixation and concluded that the functional results were poor in cases with a radiocarpal malalignment pattern[17,19,21].

The increased SLA found to occur with displaced distal radial fracture in pre-reduction radiographs has been proposed to be the result of the effective flexed position of the wrist joint due to the dorsal radial tilt and should not always be interpreted as injury to the scapho-lunate complex unless associated with a pathological gap of greater than 3 mm [18,25]. The wrist flexion involves the scaphoid moving more than the lunate by an average of 17°. This makes the proximal carpal row move in a columnar manner with the least excursion at the radio-lunate joint. The increased SLA and the midcarpal instability with an extended lunate could almost always be corrected with reduction of the fracture[26]. The increased SLA was present in midcarpal instability group in the pre-reduction radiograph of 44 (53.66%) of our patients with SLA exceeding 60°.

Our study reiterates the importance of focusing on initial fracture characteristics in distal radial fractures and also brings to notice the fact that radiocarpal instability pattern on post reduction radiographs is

an important predictor of instability. ERLF measurement is a valuable and sensitive adjunct for determining the severity and prevalence of intra carpal soft tissue lesions which are often overlooked on routine radiographs with fractured distal radius. Attention to these radiological parameters will not only help in predicting the radiological outcome but will also allow the surgeon to counsel the patients appropriately regarding the chances of success with closed treatment and other viable treatment options.

Our study had a few limitations too namely a small sample size and a wide range of patient's age. Apart from that since the criterias for an acceptable result are based on radiographic measurements and not on clinical results it also proved to be a limitation in this study as some of the patients radiographically might have an unacceptable level of displacement but still have an acceptable clinical outcome. However large multicentre trials are still needed to deduce the eventual influence of carpal malalignment in association with distal radius fractures on long term functional outcome.

CONCLUSIONS

Two patterns of carpal mal-alignments mid-carpal and radio-carpal are associated with conservatively managed fracture distal end radius. Radio-carpal malalignment pattern are difficult to reduce satisfactorily and have an increased incidence of displacement, thus suggesting an indication for other treatment methods. The same malalignment pattern reappeared with the redisplacement of the fractures and occurred during the immobilization period itself. Measurement of the carpal angles may be more informative if they are measured with the restored radial anatomy on post-reduction film. The abnormal carpal angles especially scapho-lunate angle seen in the patient with the fracture distal end of radius can be because of the altered fracture bio mechanism rather than an associated ligaments injury. Measurement of effective radio-lunate flexion (ERLF) can serve as a valuable and sensitive adjunct to determine the carpal malalignment pattern and anticipation of the final radiological outcome. An awareness of initial fracture characteristics in distal radial fractures in form of these radiological parameters will not only aid anticipation of the radiological outcome, but would allow the surgeon to inform the patient of chances of success with conservative treatment and alternative treatment options.

REFERENCES

1. Gupta A (1991) The treatment of Colles' fracture. J Bone Joint Surg [Br] 73:312–315
2. Owen RA, Melton LJ, Johnson KA, Ilstrup DM, Riggs BL (198 Incidence of Colles' fracture in a North American community. J Bone Joint Surg 72:605–607
3. Sarrafian SK, Melamed JL, Goshgarian GM (1977) Study of wrist motion in flexion and extension. Clin Orthop 126:153–159
4. Taleisnik J, Watson HK: Midcarpal instability caused by malunited fractures of the distal radius. J Hand Surg Am 1984, 9:350-357
5. Taleisnik J: The Wrist. New York, Churchill Livingstone 1985, 325
6. Bickerstaff DR, Bell MJ: Carpal malalignment in colles' fractures. J Hand Surg Br 1989, 14B(2):155-160
7. Altissimi M, Mancini G, Azzara A, Ciaffoloni E (1994) Early and late displacement of fractures of the distal radius: the prediction of instability. Int Orthop 18:61–65
8. Dias JJ, Wray CC, Jones JH (1987) The radiological deformity of Colles' fractures. Injury 18:304–308
9. Jeanne MM, Mouchet A: Less lesions traumatiques fermees du poignet. Presented at 28th. Congress Francais de Chirugie. Paris 1919.
10. Linscheid RL, Dobyns JH, Beabout JW, Brayan RS: Traumatic instability of the wrist. Diagnosis, classication and pathomechanks J Bone Joint Surg Am 1972, 54-A(8):1612-1632
11. Tang J: Carpal instability associated with fracture of the distal radius. Chinese Med J 1992, 105(9):758-765
12. Craigen MA, Stanley JK. Wrist kinematics. Row, column or both?. J Hand Surg [Br]. 1995 Apr. 20(2):165-70. [Medline].
13. Sarmiento A, Pratt GW, Berry NC, Sinclair WF: Colle's fracture. Functional bracing in Supination, J Bone Joint Surg Am 1975, 57(3):311-317.
14. Van der linden W, Ericson R: Colles' fracture. How should its displacement be measured and how should it be immobilized, J Bone Joint Surg Am 1981, 63(8):1285-1288.
15. Garcia-Elias M. Treatment of scapho-lunate instability. Ortop Traumatol Rehabil. 2006 Apr 28. 8(2):160-8
16. Sarrafian SK, Melamed JL, Goshgarian GM: Study of wrist motion in flexion and extension. Clin Orthop 1977, 126:153-159
17. Batra S, Gupta A: The effect of fracture – related factors on the functional outcome at one year in distal radius fractures. Injury 2002
18. Linscheid RL, Dobyns JH, Beabout JW, Bryan RS. Traumatic instability of the wrist. Diagnosis, classification, and pathomechanics. J Bone Joint Surg Am. 1972 Dec. 54(8):1612-32. [Medline]
19. . Gong XY, Rong GW, Geng XS (1994) Colles' fracture and instability of wrist joint. Chung Hua Wai Ko Tsa Chih 32(2):87– 89, 1984.
20. HANS J. KREDER, Consistency of AO fracture classification for the distal radius, J Bone Joint Surg [Br] 1996;78-B:726-3121. Sameer Batra et al. Can carpal malalignment predict early and late instability in non operatively managed distal radius fractures? Int Orthop. Oct 2008; 32(5): 685–691.
22. Ajay Gupta,Sumit Batra, Pankaj Jain, Sharma S. K. Carpal alignment in distal radial fractures, BMC Musculoskeletal Disorders 2002, 3:14
23. Brahin B, Allieu Y. Compensatory carpal malalignments. Ann Chir Main. 1984;3(4):357–363.
24. Hove L, Solhein E, Skjeie R, Sorensen F. Prediction of secondary displacement in Colles fractures. J Hand Surg [Br] 1994;19:731–736
25. Bednar JM, Osterman AL. Carpal Instability: Evaluation and Treatment. J Am Acad Orthop Surg. 1993 Oct. 1(1):10-17.
26. Jack A Porrino et al., Distal radial fracture imaging AJR 2014 ; 203:551- 559 Oct 2015.