ORIGINAL RESEARCH PAPER

Volume-7 | Issue-1 | January-2018 | PRINT ISSN No 2277 - 8179

INTERNATIONAL JOURNAL OF SCIENTIFIC RESEARCH

REAL TIME STRAIN ELASTOGRAPHY: APPLICATIONS IN HEAD AND NECK REGION: PICTORIAL ESSAY.

Radiodiagnosis

Dr. Suresh Phatak Professor And Head of Department, Dept. of Radio- Diagnosis, Jawaharlal Nehru Medical College, Sawangi (Meghe), Wardha, Maharashtra, India - 442001

Dr. Gaurav Mishra* Assistant Professor, Dept. of Radio- Diagnosis, Jawaharlal Nehru Medical College, Sawangi (Meghe), Wardha, Maharashtra, India - 442001. *Corresponding Author

Dr. Nipun Gupta Resident, Dept. of Radio- Diagnosis, Jawaharlal Nehru Medical College, Sawangi (Meghe), Wardha, Maharashtra, India - 442001.

Dr. Shishir Rawekar Resident, Dept. of Radio- Diagnosis, Jawaharlal Nehru Medical College, Sawangi (Meghe), Wardha, Maharashtra, India - 442001.

Dr. Sakshi Daga Resident, Dept. of Radio- Diagnosis, Jawaharlal Nehru Medical College, Sawangi (Meghe), Wardha, Maharashtra, India - 442001.

Ms. Pallavi Phatak Final Year MBBS Student, Jawaharlal Nehru Medical College, Sawangi (Meghe), Wardha, Maharashtra, India - 442001.

ABSTRACT

Elastography is an ultrasound based recent technique currently used for evaluation of breast and liver pathology. It is also being evaluated in other areas. We are presenting a pictorial essay of our initial experience of its evaluation in head and neck region in various cases seen in our hospital.

KEYWORDS

Strain elastography, Sonoelastography, Real-Time Tissue Elastography, Elasticity Imaging

Introduction: - Elastography is based on the principle of tissue deformity due to application of pressure. Different tissues behave in different ways depending on its molecular makeup as external pressure is applied on it. Soft tissues are deformed more when external pressure is applied and hard tissues will deform much less. This information is registered on the monitor in the form of spectrum of colours. Dark Blue colour represents hard areas, red soft areas and green firm areas which have intermediate consistency. The tissue contrast seen on elastography is caused by differential tissue stiffness.[1] Elastography is a recent imaging modality used for the evaluation of tissue stiffness of superficial organs. It is a sensitive imaging modality for the detection of thyroid nodules, cervical lymph nodes, salivary masses, assessing stiffness of the masseter muscle, and other superficial neck masses.

Tsukuba scoring system: - Itoh et al described a scoring system in 2006.A score of 1 indicated even strain for the entire hypoechoic lesion (i.e., the entire lesion was evenly shaded in green). A score of 2 means strain in most of the hypoechoic lesion, with some areas of no strain (i.e., the hypoechoic lesion had a mosaic pattern of green and blue), A score of 3 implies that strain at the periphery of the hypoechoic lesion, with sparing of the center of the lesion (i.e., the peripheral part of lesion was green, and the central part was blue). A score of 4 shows no strain in the entire hypoechoic lesion (i.e., the entire lesion was blue, but its surrounding area was not included. A score of 5 indicated no strain in the entire hypoechoic lesion or in the surrounding area (i.e., both the entire hypoechoic lesion and its surrounding area were blue). BGR represents typical artifactual three layered aspect (blue-green-red) encountered with cystic lesions. In strain patterns, score 1, 2 and 3 emphasized benign features whereas masses with scores of 4 and 5 were considered as malignant. [2]

Strain Ratio Measurement

A semi quantitative method of lesion assessment, termed as strain ratio (SR) measurement, has also been developed. Calculation of the SR value is based on determining the average strain measured in a lesion and comparing it to the average strain of a similar area of adjacent tissue. Using proprietary software, the average strain of the lesion is determined by selecting a region of interest (ROI) encompassing the lesion; the value of strain ratio increases as a function of the relative stiffness of the target lesion. [3]

Applications:-

THYROID:-

Ultrasound elastography is a new promising technique used in differential diagnosis of thyroid cancer. The use of ultrasound elastography can help to reduce thyroid biopsies because the high elasticity is usually strongly associated with a benign pathology.[4] The scores of 1 and 2 with Itoh criteria are significantly seen in benign nodules, whereas, scores of 3 and 4 seen in malignant nodules.The mean SR for the benign nodules and malignant ones was significantly different (2.92 ± 0.96 vs. 4.53 ± 0.82, $p<0.001$). With ROC analysis, the best cut-off strain ratio point was 3.5 for differentiating benign and malignant nodules with area under the curve (AUC) = 0.87 (0.8–0.95). Both the elastographic score and strain ratio are higher in malignant nodules than those in benign ones. Ultrasound elastography can provide quantitative information on thyroid nodule helping in differentiating benign and malignant ones. [5]

SALIVARY GLANDS:-

Salivary gland neoplasms account for < 3 % of all tumors. Most of them are benign and parotid gland is the commonest site.As a general rule ,the smaller the involved salivary gland the higher is the possibility of the tumor being malignant.The role of imaging in assessment of salivary gland tumor is to define intraglandular VS Extraglandular location,detect malignant features,aseess local extension and invasion,detect nodal metastasis and systemic involvement.[6] In both the major and minor salivary glands, the commonest type of benign tumour is pleomorphic adenoma. For malignant salivary tumour, the commonest type overall is muco epidermoid carcinoma[7] Most pleomorphic adenomas are predominantly elastic but complete stiffness or mixed pattern with predominant stiffness is also seen.[8]There was a significant difference between elasticity scores of benign and malignant masses but no clear cut cut-off value could be identified.[9]

LYMPH NODES:-

The accuracy of sonoelastography is higher than usual B mode and power Doppler ultrasound parameters in differentiation between benign and malignant nodes.The integration of lymph node sonoelastography in the follow up of patients with known head and neck cancer may reduce the number of biopsies[10] Alam et al classified Elastographic appearance of lymphnodes in five patterns based upon on the distribution and percentage of the lymph node area with high elasticity (hard) .Pattern 1, an absent or a very small hard (i.e., blue) area; pattern 2, hard area < 45% of the lymph node; pattern 3, hard area ≥ 45%; pattern 4, peripheral hard and central soft areas; pattern 5, hard area occupying entire lymph node with or without a soft rim. Pattern 1 & 2 were reactive lymphnodes and 3, 4, 5 were

malignant.[11]

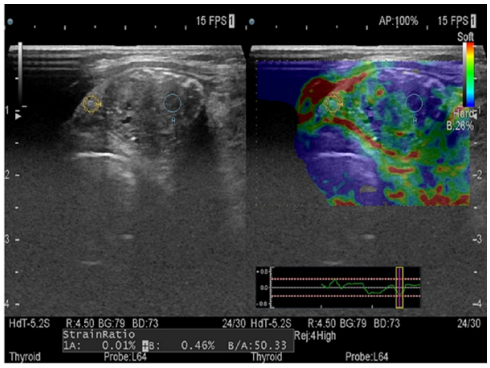

FIG1] A hypoechoic nodule in left lobe of thyroid containing tiny calcifications on elastography showing stiff tissue within (dark blue colour). Strain ratio was 50.33, biopsy report was papillary carcinoma of thyroid.

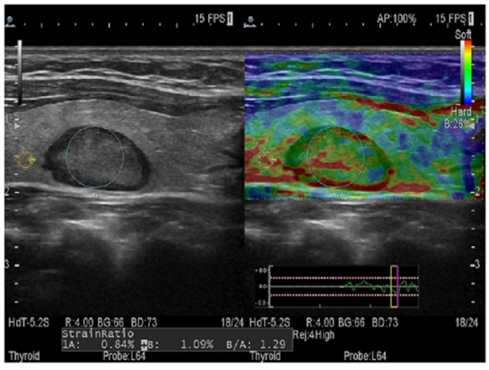

FIG2] A hyperechoic nodule in right lobe of thyroid with a hypoechoic peripheral rim .Nodule show predominantly soft colours (green and red) and strain ratio of 1.29.FNAC report was follicular adenoma.

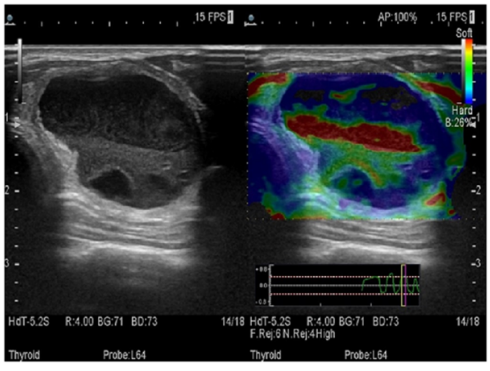

FIG3] A large cystic lesion in left lobe of thyroid showing fluid levels and debris within .On elastography typical BGR appearance (Blue-Green-Red) of cyst confirmed pathologically.

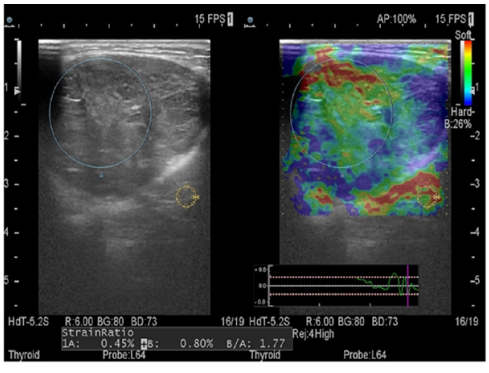

FIG4] A well defined solid lobulated parotid mass showing posterior acoustic enhancement. On elastography showing mostly soft colours and strain ratio of 1.77 indicating benign nature of lesion later on confirmed as pleomorphic adenoma on biopsy.

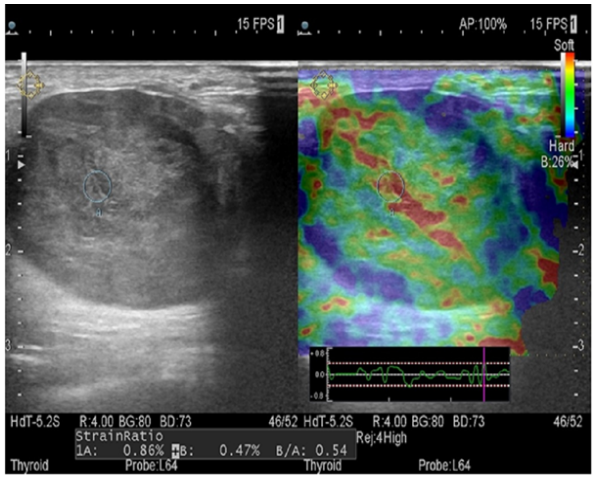

FIG5] A well defined solid parotid mass showing few small cystic areas on USG.Doppler showed hypervascularity. On elastography Soft colours were seen in lesion with strain ratio of .54 indicating benign nature of neoplasm. On biopsy found to be Warthins tumor.

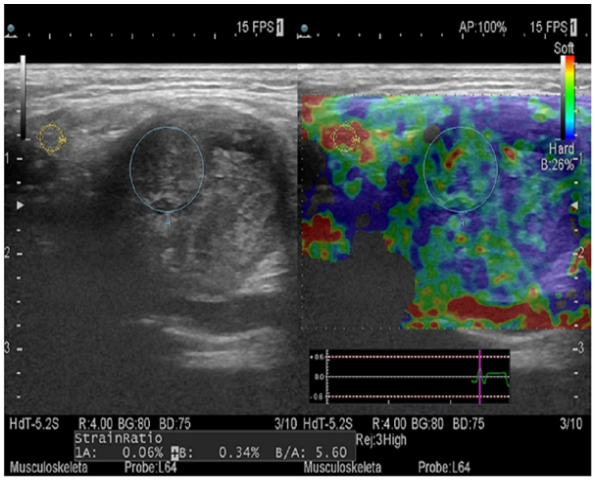

FIG6] Large hypoechoic parotid mass with indistinct margins. On elastography showing predominantly dark blue colour and strain ratio of 5.6.Biopsy report was adenocarcinoma.

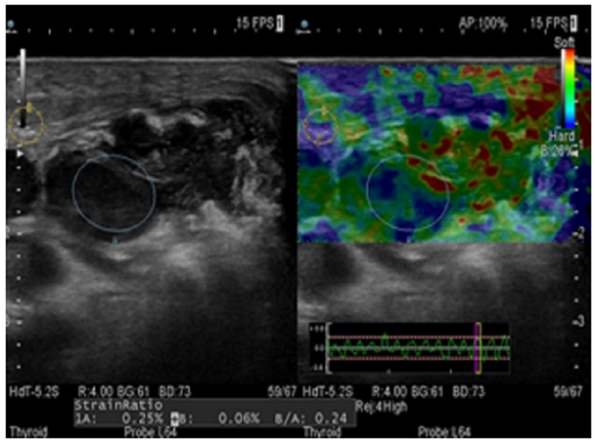

FIG7] Patient presenting with fever and pain in left Submandibular region. On USG a hypoechoic lesion with internal debris was seen.On Doppler hypervascularity was noted. Elastography shows predominantly soft colours in lesion and strain ratio of 0.24 indicating benign lesion confirmed as abscess on pathological examination.

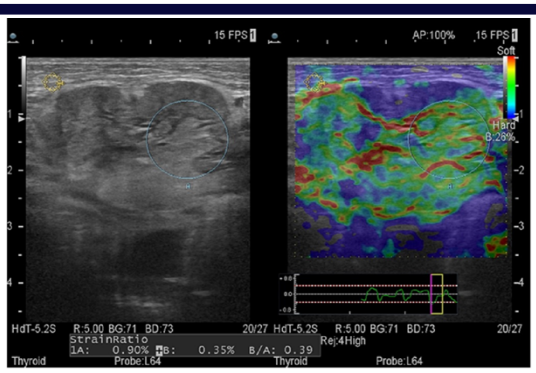

FIG8] A ten year old child presented with fever and pain in left Submandibular region. On USH a large hypoechoic Submandibular gland was seen showing marked hypervascularity on Doppler. Multiple reactive lymphnodes were seen adjacent to gland.Elastography revealed mostly soft colours in gland and strain ratio of .39 indicating benign pathology confirmed later on as acute sialadenitis.

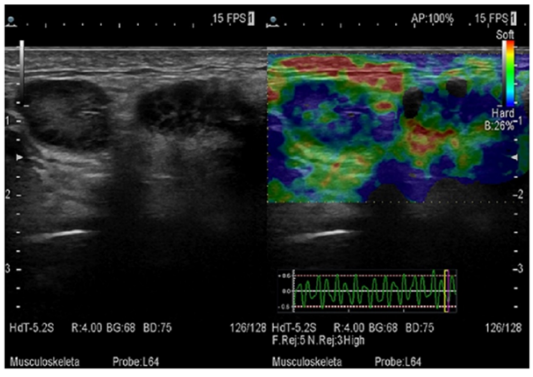

FIG9] Malignant neck lymphnodes on elastography --- Pattern 3(hard area >45% area of lymph node).

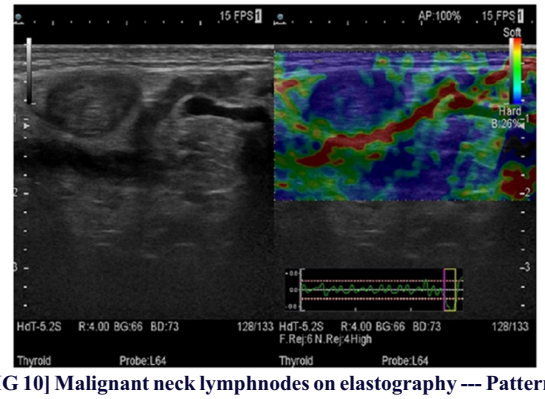

FIG 10] Malignant neck lymphnodes on elastography --- Pattern 5 where almost whole lymph node is stiff (Blue).

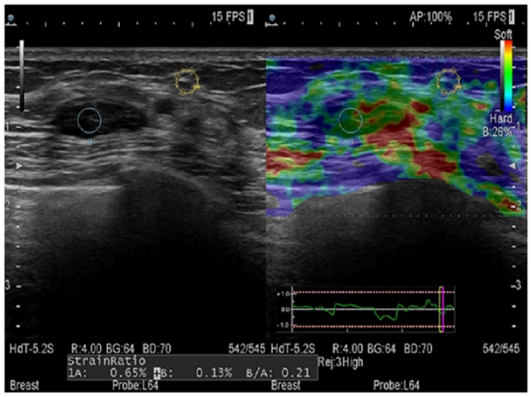

FIG11] Benign neck lymph node --- Pattern 1 very small or absent hard (blue) area.

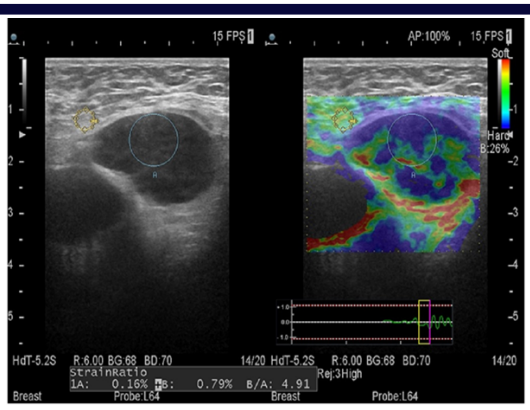

FIG12] Biopsy proven Non Hodgkins lymphoma. Neck node shows Pattern 3 on elastography and strain ration of 4.91 indicating malignancy.

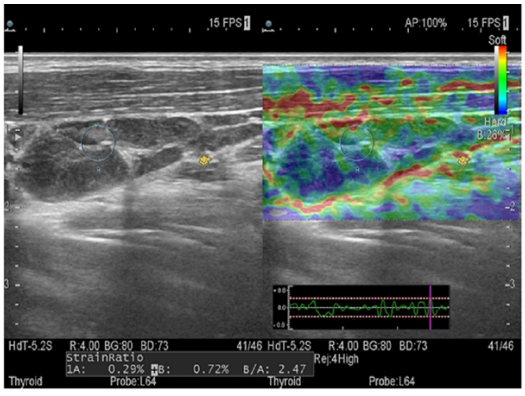

FIG13] USG showing multiple matted posterior neck nodes (Group5) with few small cystic areas. Elastography reveals predominantly soft colours (red and green) indicating benign nature proven as tuberculous lymphnode on biopsy.

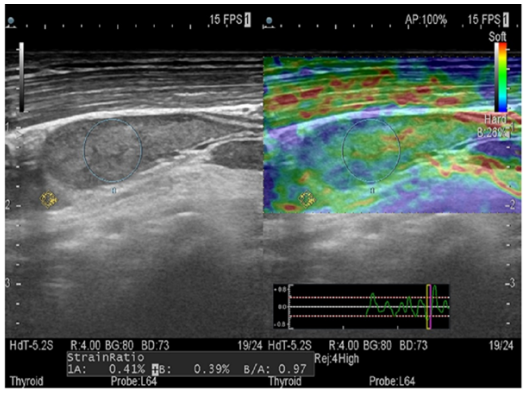

FIG14] Young boy of 20yrs presented with multiple cervical lymphadenopathy. On Elastography all lymphnodes show soft colours .Strain ratio in one of the nodes was 2.7 indicating a benign generalized process.On biopsy Kimura's disease was diagnosed.

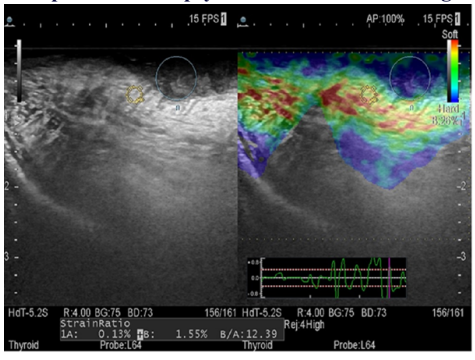

FIG15] Ulcerative growth on left lateral margin of tongue.USG

shows a hypoechoic vascular lesion on left lateral margin.On elastography Dark blue colour was seen with strain ratio of 12.39 indicating malignancy.Biopsy report confirmed carcinoma.

REFERENCES:-

1. Palle Lalitha, Balaji Reddy, K.Jagannath Reddy. Musculoskeletal applications of elastography pictorial essay of our initial experience. Korean J Radiol 2011; 12:365-75.
2. Itoh A, Ueno E, Tohno E, Kamma H, Takahashi H, Shiina T, et al. Breast disease: Clinical application of US elastography for diagnosis. Radiology. 2006; 239:341-50.
3. Zhi H, Xiao XY, Yang HY, et al. Semi-quantitating stiffness of breast Solid lesions in ultrasonic elastography. Acad Radiol. 2008; 15(11):1347-1353.
4. Hamad Elniel H. Eltyib, Ibrahim A. Awad, Naglaa M. Elsayed, Saddig D. Jasta. Real Time Ultrasound Elastography for the Differentiation of Benign and Malignant Thyroid Nodules. Open Journal of Medical Imaging, 2014; 4:38-47.
5. Mona A. EL-Hariri , Tamer F. Taha Ali , Mohamed A. Tawab , Asmaa M.A. Magid , Abdel-Fattah EL-Shiekh The clinical value of ultrasound elastography in predicting malignant thyroid nodulesThe Egyptian Journal of Radiology and Nuclear Medicine (2014) 45, 353–359.
6. Lee YY ,Wong KT, King AD, Ahuja AT Imaging of salivary gland tumors Eur J Radiol 2008;66(3):419-36.
7. Victor Shing Howe To, Jimmy YuWai Chan, Raymond K. Y. Tsang, and William I.Wei Review of Salivary Gland Neoplasms International Scholarly Research Network ISRN Otolaryngology Volume 2012, Article ID 872982, 6 pages doi:10.5402/2012/872982
8. Dana Dumitriu, Sorin M.Dudea, Carolina Botar-Jid, Grigor Baciut. Ultrasonographic and sonoelastographic features of pleomorphic adenomas of salivary glands. Medical ultrasonography 2010; 12:175-83.
9. Dana Dumitriu, Sorin Dudea, Carolina Botar-Jid, Mihaela Baciut, Grigore Baciut. Real time sonoelastography of major salivary gland tumors. AJR 2011; 197:W924-30.
10. Mohamed Mohamed Hefeda, Manal Ezat BadawyCan ultrasound elastography distinguish metastatic from reactive lymph nodes in patients with primary head and neck cancers? The Egyptian Journal of Radiology and Nuclear Medicine (2014) 45, 715–722.
11. Farzana Alam ,Kumiko Naito, Jun Horiguchi, Hiroshi Fukuda, Toshihiro Tachikake Katsuhide Ito. Accuracy of Sonographic Elastography in the Differential Diagnosis of Enlarged Cervical Lymph Nodes: Comparison with Conventional B-Mode Sonography. AJR 2008; 191:604–10