ORIGINAL RESEARCH PAPER

Volume-7 | Issue-9 | September-2018 | PRINT ISSN No 2277 - 8179

INTERNATIONAL JOURNAL OF SCIENTIFIC RESEARCH

RECON FEMORAL NAIL IS THE IDEAL TREATENT OF CHOICE FOR FAILURE DYNAIC HIP SCREW WITH BONE GRAFT.

Orthopaedics

Dr. Mohammed. Iftekar. Ali M.S. Orthopaedics Associate Professor Prathima Institute Of Medical Sciences. Karimnagar Telangana.

Dr. Naresh Anaalla* MD.Anaesthesia *Corresponding Author

Dr. Anudeep MS. Orthopaedics

ABSTRACT

Thirty-two patients (11 male, 21 female) with a mean age of 64 years were prospectively studied after undergoing Recon femoral nail after failed treatment of intertrochanteric fractures with dynamic hip screw. One patient had bilateral surgery. The mean time from primary surgery to the secondary surgery was 15 months(range, 4 to 32 months). The mean follow-up period was 57 months (range, 30 to108 months).Three patients had deep venous thrombosis, two had gastrointestinal bleeding and one had a non fatal pulmonary embolism.At the last follow-up, we were able to review 26 patients .the majority had good pain relief and marked functional improvement. Twenty-two patients had either no or mild pain and 24 patients were able to walk freely with or without support .Almost 78% of patients had either excellent or good clinical results based on Harris hip score. Heterotopic ossification was noted in 8 hips. Recon femoral nail was found in this study to be an effective salvage procedure after failed treatment of inter trochanteric fracture in elderly patients

KEYWORDS

Inter Trochanteric Fracture ; Dynamic Hip Screw ; Recon Femoral Nail,bone Graft.

INTRODUCTION

Most intertrochanteric hip fractures can be treated successfully with internal fixation . Union rates as high as 100% have been reported with well reduced, stable fractures treated with optimal implant placement .[1,2,3]. Failure rates up to 56% have been reported, related with certain problematic fracture patterns, comminution, poor bone quality and suboptimal fixation .Failed treatment of intertrochanteric fractures typically leads to profound functional disability and pain. Recon femoral nail is considered as a salvage procedure for older patients, patients with poor bone stock, [12].

PATIENTS AND METHODS

Between 2014 and 2018, 32 patients underwent recon femoral nail fixation for salvage of failed treatment of intertrochanteric fractures ; one case was bilateral.There were 21 women and 11 men with a mean age of64 years (range, 46 to 85 years). All patients had their fractures originally fixed with a Dynamic Hip Screw(DHS). The mean time from primary fixation to the Recon femoral nail was 15 months (range, 4 to32 months).First broken implant was removed, reaming done and then recon femoral nail was inserted and proximal and distal locking done. Harris hip score (HHS) was used for clinical evaluation preoperatively, postoperatively and at last follow-up. Radiological evaluation of the integrity of the fixation was done at every follow- up visit.

Iliac crest bone graft was used.Pre and postoperative x-ray are shown in figure1 &2.

RESULTS

The mean operative time was 90 minutes(range, 60 to 120 minutes) with a mean estimated external blood loss of 150 ml . The mean follow-up period was57 months (range, 30 to 108 months).Six patients had a total of seven postoperative complications. deep venous thrombosis was noted in four patients, non fatal pulmonary embolism in one and upper gastrointestinalbleeding in two, one of which had upper gastro intestinal endoscopy and blood transfusion. We had no early postoperative mortality. Union occurred in all cases.

The mean preoperative Harris hip score was 26 ints and improved to a mean of 84 points at the latest follow-up. At the end of follow-up, we had 21hips (77.7%) with good or excellent results, four hips (14.8%) with fair results and two hips with poor results.

DISCUSSION

Biomechanically, compared to a dynamic hip screw, an intramedullary device decreases the bending force of the hip joint on implant by 25-30%.[4,5]. This has advantages especially in elderly patients, in whom the primary treatment goal is immediate full-weight bearing mobilization.Traditionally it was the posteromedial comminution which was considered the most importantfactor in determining the severity of fracture. The importance of the integrity of the lateral femoral wall has been documented recently [9,10,12]. The lateral wall is the proximal extension of the femoral shaft. This lateral wall is extremely thin in unstable 31-A2 type fracture .[6,7,8,9,10].

The lateral wall in patients treated with dynamic hip screw provides a lateral buttress for the controlled fracture impaction and preventing collapse. Palm et al found that there was eight times higher risk of reoperation due to technical failure with the gold standard technique of dynamic hip screw in patients with fracture of the lateral femoral wall [9] This has been attributed to the fact that when the lateral femoral wall is fractured, the fracture line is parallel to the sliding vector of the sliding hip screw, which, as in the reverse oblique intertrochanteric fracture, allows the trochanteric and femoral head and neck fragments to slide laterally and the shaft to slide medially. The fracture complex subsequently disintegrates, with a high risk of failure including cutout of the screw into the hip joint.

In fractures with compromised lateral wall, either a locking plate (proximal femoral locking compression plate or reverse distal femoral locking compression plate) or DHS with trochanteric stabilization plate which acts as lateral buttress and limits excessive collapse. The other option is an intramedullary nail which acts by bypassing the lateral wall and acts as a prosthetic lateral cortex medial to the broken lateral wall. Most of the recent studies suggest Recon femoral nail as gold standard implant in these type of fractures .Less Blood loss during Surgery/ Less operative time/ Smaller incision.

Conclusion

Advantages of proximal femoral nail are less surgical trauma, less screening time,less blood loss and earlier rehabilitation, the ease of implantation and the possibility of early weight-bearing even after very complex fractures. Surgical expertise is necessary to avoid the complications associated with Recon femoral nail.

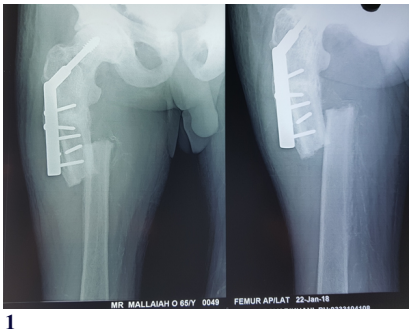

FIGURE: 1

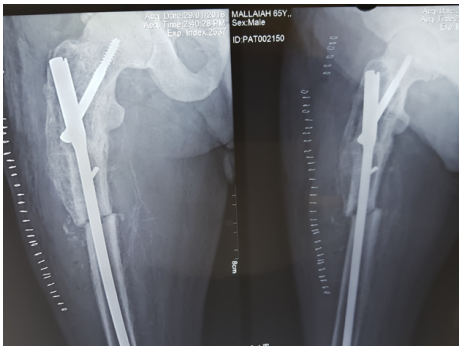

FIGURE: 2

REFERENCES

1. Anglen JO, Weinstein JN. Nail or plate fixation of intertrochanteric hip fractures: changing pattern of practice. A review of the American Board of Orthopaedic Surgery Database. J Bone JointSurgAm.2008;90:700–7.
2. Parker MJ, Handoll HH. Gamma and other cephalocondylic intramedullary nails versus extramedullary implants for extracapsular hip fractures in adults. Cochrane database Syst Rev [Internet].2010Jan[cited2015Mar8];(9):CD000093.
3. Parker MJ, Handoll HHG. Gamma and other cephalocondylic intramedullary nails versus extramedullary implants for extracapsular hip fractures in adults. Cochrane database Syst Rev [Internet].2008Jan[cited2015Mar8];(3):CD000093.
4. Parker MJ, Handoll HHG. Gamma and other cephalocondylic intramedullary nails versus extramedullary implants for extracapsular hip fractures. Cochrane database Syst Rev [Internet]. 2004Jan[cited2015Mar8];(1):CD000093.
5. Jiang S-D, Jiang L-S, Zhao C-Q, Dai L-Y. No advantages of Gamma nail over sliding hip screw in the management of peritrochanteric hip fractures: a meta-analysis of randomized controlledtrials.DisabilRehabil.2008;30:493–7.
6. Radford PJ, Needoff M, Webb JK. A prospective randomised comparison of the dynamic hip screw and the gamma locking nail. J Bone Jt Surgery, Br Vol [Internet]. 1993;75-B:789–93.
7. O'Brien PJ, Meek RN, Blachut PA, Broekhuyse HM, Sabharwal S. Fixation of intertrochanteric hip fractures: Gamma nail versus dynamic hip screw.
8. Palm H, Jacobsen S, Sonne-Holm S, Gebuhr P. Integrity of the lateral femoral wall in intertrochanteric hip fractures: an important predictor of a reoperation. J Bone Joint Surg Am. 2007;89:470–5.
9. Gotfried Y. The lateral trochanteric wall: a key element in the reconstruction of unstable pertrochanteric hip fractures. Clin Orthop Relat Res. 2004;82–6.
10. Haidukewych GJ, Israel TA, Berry DJ. Reverse obliquity fractures of the intertrochanteric region of the femur. J Bone Joint Surg Am. 2001;83-A:643–50.
11. Im G-I, Shin Y-W, Song Y-J. Potentially unstable intertrochanteric fractures. J Orthop Trauma.2005;19:5–9.
12. Pu JS, Liu L, Wang GL, Fang Y, Yang TF. Results of the proximal femoral nail anti-rotation (PFNA) in elderly Chinese patients. Int Orthop. 2009;33:1441–4.