VOLUME-6 | ISSUE-4 | APRIL - 2017 • ISSN No 2277 - 8179 | IF : 4.176 | IC Value : 78.46

RESULTS OF CONSERVATIVE TREATMENT OF CONDYLAR FRACTURES

Dental Science

KEYWORDS: Condylar fractures; Intermaxillary fixation; Mandibular condyle; Effective treatment; Subcondylar

S.Gokkulakrishnan	Professor & Head, Department of OMFS, Adhi Parasakthi Dental College & Hospital, Melmaruvathur. Tamilnadu Dr. MGR Medical University
Abhishek Balaji	Assisstant Professor, Department of OMFS, Adhi Parasakthi Dental College & Hospital, Melmaruvathur. Tamilnadu Dr. MGR Medical University
Suresh Kumar	Reader, Department of OMFS, Adhi Parasakthi Dental College & Hospital, Melmaruvathur. Tamilnadu Dr. MGR Medical University
Srinivasulu Pabbaraju	Assisstant Professor, Department of OMFS, Adhi Parasakthi Dental College & Hospital, Melmaruvathur. Tamilnadu Dr. MGR Medical University
Nithin Jude	Assisstant Professor, Department of OMFS, Indira Gandhi Institute of Dental Science, Pondicherry.
Mohammed Rafeeq	Reader, Department of OMFS, Educare Institute of ental Science.

ABSTRACT

AIMS & OBJECTIVES To evaluate the patients for functional results after conservative treatment of mandibular condylar fracture with intermaxillary fixation. **MATERIALS & METHODS** This study included 36 patients, with condylar fractures including head, neck or subcondylar fractures with or without associated injuries, treated with intermaxillary fixation. In a follow up period of 3 months, pain in the TMJ, lateral and protrusive movements and pain in muscles of mastication were evaluated. **RESULTS** A very highly significant improvement ($p<.001$) in all the parameters selected, were observed with marked improvement in the occlusion. **CONCLUSION** The conservative treatment of mandibular condyle fractures is an effective treatment modality in terms of functional outcome. However assessment of factors pertaining to individual cases must be made to determine the mode of therapy, most likely to produce a favorable outcome.

Introduction

Fractures of the mandibular condylar process are common injuries that account for 29% to 40% of fractures of the facial bones and represent 20% to 62% of mandibular fractures. Direct blow to the chin or to the lateral side of the jaw caused by traffic collisions, violence, accidental falls, and sports injuries were found to be the common causes for mandibular condyle fracture.

Management of fractures of the mandibular condyle is a debatable issue amongst oral and maxillofacial surgeons that has sparked considerable controversy, especially regarding surgical and non surgical treatment[2,3,4]. This controversy is reflected in the wide variety of options and proposed treatment modalities offered in the literature.

The commonly accepted agreed goal of treatment is the reestablishment of the preoperative function of the masticatory system. This restoration typically involves reestablishment of the preoperative relationship of the fracture segments, the occlusion and the maxillofacial symmetry. Unlike fracture of other bones, however the exact re approximation of the fracture condylar segment may not be absolutely essential[5].

There is no doubt that after conservative management of fracture of the condylar process there occurs a complex series of adaptations that attempt to restore the articulation to facilitate masticatory function. These adaptations begin immediately after injury, but differ somewhat in their timing and importance. There are 3 main types of adaptations that occur: 1) neuromuscular adaptations; 2) skeletal adaptations; and 3) dental adaptations[3].

The decision about the choice of the type of treatment must always take into consideration some of the factors, such as the patient's general health status, type of fracture, diagnostic precision, and mainly the capability, experience and skill of the surgeons in treating mandibular condyle fractures.

The aim of this present study is to evaluate the post operative results following treatment of unilateral and bilateral condylar fractures treated with IMF.

Materials and Method

This study consisted of 36 cases of condylar fractures above 12 years of age that reported between June 2008 to December 2010, with or without associated fractures elsewhere in the maxillofacial region and sufficient dentition to allow maxillomandibular fixation that reported to our centre.

For all patients a detailed case history was taken to rule out significant systemic conditions that could have a bearing on patient's treatment protocol. Detailed clinical examination was carried out as per the protocol. The face and mandible was examined for any abnormal contours. Mandibular movements were checked for any abnormalities along with recording of maximum interincisial opening. The occlusion was checked for any discrepancies. Any Intraoral or Extraoral lacerations were thoroughly examined and debrided prior to treatment. Any evidence of buccal or sublingual ecchymosis was noted.

Radiographic examination included the ortho-pantomogram. Additional radiographic projections were obtained when needed. The radiographs were assessed for the degree of displacement of the fractured fragments.

Non-surgical or conservative therapy included elastic traction followed by maxillomandibular fixation established using Erich's arch bar and 24 or 26 gauze smooth, stainless steel wires. The intermaxillary fixation was maintained for about three to six weeks depending upon the individual cases and also fractures. A soft semisolid and liquid diet was advocated during this period.

Post treatment the patients were followed up at a regular interval of 1, 2 and 3 months for checking mouth opening (interincisal distance), occlusion, condylar movements, pain in the TMJ and masticatory

muscles.

Patients were only considered to have complications when the symptoms were related to the fracture or its treatment and were recognized as a problem for patient, and when complication could be verified objectively. Malocclusion consisted of hyperocclusion posteriorly on the fractured side, contralateral open bite or crossbite. Pain located in the joints or to the masticatory muscles was verified by reaction on palpation of these structures.

Results

Details related to age, gender, cause of fracture, type of fracture, treatment used, mouth opening, any associated injury, pain score in TMJ and masticatory muscle, lateral and protrusive movements were recorded. The subjects were followed up for 3 months at monthly time intervals to assess the change in mouth opening, TMJ pain scores, Masticatory muscle pain score, lateral movement and protrusive movement. At the end of 3 months follow up change in occlusion was noted. The results obtained have been shown as under:

Maximum number of subjects were in the age group 21-30 years (44.4%) followed by $\leq$20 years and 31-40 years (22.2% each). In age group >40 years there were only 2 (11.1%) subjects aged 50 and 70 years respectively. Most of subjects in present study were males (83.3%). Only 16.7% were females with male to female ratio 5:1.

Road traffic accidents (RTA) were the most common cause of mandibular condylar followed by fall, interpersonal violence and electric shock. Most of the fractures were subcondylar (55.6%), involvement of head was seen in 6 (16.7%), neck in 10 (27.8%) and both head and neck in 1 (2.7%) subject. In most of the cases (94.5%) IMF was performed using arch bars, whereas in just 2 cases (5.5%) IMF was performed using eyelet wiring.

In majority of subjects the pre-operative mouth opening was in the range of 21-25 mm. In 2 cases it was >25 mm (28 mm) while in 14 cases (38.9%) the mouth opening was in the range of 16-20 mm (Table 1). In exactly half of the cases, no associated injury was observed while in other half there were associated injuries too.

At baseline the mean pain score at fractured side was 3.89±1.20 while the same was recorded as 0.53±1.26 at non fractured side, thereby showing a statistically significant difference ($p<0.001$). Contrary to pain scores for TMJ (Table 2), for masticatory muscle (Table 3) no significant difference in mean pain scores of fractured and non fractured sides were seen.

At all the time intervals, the lateral movement was higher at fractured side (Graph 1) as compared to non fractured side. In 50% cases protrusive movement was possible pre-operatively while in remaining 50% it was not possible.

At baseline the mean mouth opening was 21.72±2.97 mm which increased to 24.06±6.31 mm at 1 month, 30.28±4.80 mm at 2 months and 37.11±2.11 mm at 3 months. As compared to baseline, mean mouth opening at 2 months and 3 months was found to be significantly higher ($p<0.001$). A significant reduction in pain score as seen in both sides starting from 1 month post-operatively. The reduction was found to be maximum at 3 months in both the sides. A significant reduction in pain score as seen in both sides starting from 1 month post-operatively. The reduction was found to be maximum at 3 months in both the sides.

A significant increment in lateral movement was seen in both sides starting from 1 month post-operatively. The increase was found to be maximum at 3 months in both the sides. A significant increment in protrusive movement was seen in starting from 1 month post-operatively (Graph 2). The increase was found to be maximum at 3 months. A statistically significant change in occlusion (Table 4) was seen postoperatively.

Discussion

Fractures at condylar region occur when the concentration of tensile strain exceeds the limit of tolerance of the bone. The precise location of tensile strain depends on site, direction and magnitude of impact and anatomical considerations related to the architectural configuration of the mandible. The condylar neck is inherently a weak region so it fractures easily. Moreover there is a change of axis from condylar neck to head. This twisting of neck at a different axis makes it more vulnerable to fracture

The main causes of condyle fractures worldwide are traffic accidents, assaults, falls and sports-related injuries. Because of social, cultural, and environmental factors, both the incidence and etiology of maxillofacial fractures vary from one country to another.

Functional therapy is adopted most frequently, since it permits early mobilization and adequate functional stimulation of condylar growth (in growing subjects) and bone remodeling (in all subjects). It is indicated in almost all condylar fractures that occur in childhood, and in intracapsular and extracapsular fractures that do not include serious condylar dislocation in adults.

The majority of surgeons seem to favour nonsurgical treatment of condylar fractures. This preference is largely the result of 3 main factors. First, nonsurgical treatment gives "satisfactory" results in the majority of cases. Second, there are no large series of patients reported in the literature who have been followed after surgical treatment because management of condylar fractures has historically been with nonsurgical means. Third, surgery of condylar fractures is difficult because of the inherent anatomical hazards (ie, VII nerve).

Since the introduction of osteosynthesis materials for rigid internal fixation after anatomical reduction there has been ongoing discussion about the treatment of condylar fractures of the mandible. There are two major therapeutic approaches to these fractures: functional/conservative (non surgical) and surgical.

Closed/Non surgical treatment of mandibular fractures with maxillomandibular fixation (MMF) has a long and successful history, but it is not without significant morbidity. The best results have been achieved in skeletally immature children, where condylar remodeling often can restore condylar anatomy to near normal, even in the face of little or no fracture reduction. Despite almost miraculous condylar remodeling in children, the outcomes in adults have not been uniform, and a significant percentage suffers long-term aesthetic and functional problems[11]. The majority of surgeons seem to favour nonsurgical treatment of condylar fractures. This preference is largely the result of 3 main factors. First, nonsurgical treatment gives "satisfactory" results in the majority of cases. Second, there are no large series of patients reported in the literature who have been followed after surgical treatment because management of condylar fractures has historically been with nonsurgical means. Third, surgery of condylar fractures is difficult because of the inherent anatomical hazards (i.e., VII nerve)[3].

In recent years, open treatment of condylar fractures has gained popularity, probably because of the introduction of plate and screw fixation devices that allow stable fixation of these fractures. Many surgical treatment modalities have been advocated for the treatment of mandibular condyle fractures which includes intraosseous or transosseous wire fixation, intramedullary pins, long screw placement, miniaturized dynamic compression plates designed for zygoma fractures, free graft with wire fixation after extracorporeal avulsion, disk repair with silicone rubber implantation, axial anchor screws, rigid plates and screws, bioresorbable plates, screws and condylectomy etc[12]

The future trend is towards the use of the endoscope to treat condylar injuries which is a natural extension of minimally invasive techniques for managing craniomaxillofacial trauma. Most surgeons

VOLUME-6 | ISSUE-4 | APRIL - 2017 • ISSN No 2277 - 8179 | IF : 4.176 | IC Value : 78.46

accept, on an intellectual level, that fracture reduction and rigid fixation with restoration of anatomy are laudable goals if it can be achieved without undue morbidity. Endoscopic assistance allows the surgeon to produce anatomic fracture alignment, and to avoid the negative sequelae of condylar malunion. The endoscopic approach has the potential to reduce morbidity by limiting scars, reducing the risk to the facial nerve, and eliminating the need for MMF, and yet having the advantages of anatomic reduction and rigid fixation. The decrease in morbidity associated with the endoscopic approach may expand the indications for reduction and rigid fixation in the future.[11]

As a general rule any treatment should aim to reconstruct traumatized structures to provide the optimal basis for function. The restoration of the physiological function of the temporomandibular system is of primary importance in the treatment of the condylar fracture.

For individuals with bilateral condylar fractures, where there is anterior open bite and occlusal disharmony, neuromuscular adaptations comes into play to position the mandible early after injury. At this time, there is no articulation with the temporal bone to provide vertical skeletal support for the posterior ramus. Thus, the only mechanism whereby the mandible can be positioned into a normal occlusal relationship early after injury is by complex neuromuscular adaptations in the muscles of mastication.

A slowly developing adaptation that occurs within the masticatory system after condylar process fracture is the development of a new temporomandibular articulation. This adaptation begins immediately after injury and continues for many months afterward. A new articulation between the temporal bone and the mandible provides a "fulcrum" so that the mandible can again function as a class III lever system during some functional activities, which increases its efficiency[3].

With closed treatment of condylar process fractures, extrusion of the incisors and intrusion of the molars has been demonstrated. This is especially common in patients with bilateral fractures of the mandibular condylar processes treated with closed method. When elastics are applied to the anterior teeth during treatment, the incisors extrude and the molars intrude. Therefore, given the skeletal adaptations that are occurring, dental adaptations are necessary for maintenance of the normal occlusal relationship.

Summary & Conclusion

The aim of this study was to analyze mandibular function and pain after closed treatment of fractures of the mandibular condyle by means of a prospective study. Keeping in mind the potential surgical morbidity, increased hospitalization time and cost and the concern for damage to the facial nerve associated with the surgical treatment, conservative treatment for mandibular condylar fractures was advocated.

There was a significant improvement in the parameters selected for the study, like occlusion, pain in the TMJ and muscles of mastication during various movements; we conclude, functional results after conservative treatment of the mandibular condyle fracture is acceptable. The factor that determines the outcome is occlusion achieved at the time of treatment and the physiotherapy employed after release of MMF. However assessment of factors pertaining to individual cases must be made to determine the mode of therapy, most likely to produce a favorable outcome.

Legend for illustration
Figure 1: Pre op Mouth opening
Figure 2 : Pre op OPG
Figure 3: Pre op Occlusion
Figure 4 : IMF
Figure 5 : Post op mouth opening
Graph 1 : Change in Lateral Movement at different time intervals
Graph 2 : Change in Protrusive Movement at different time intervals
Table 1 : Change in Mouth opening at different time intervals
Table 2 : Change in TMJ Pain Scores at different time intervals
Table 3 : Change in Masticatory Muscle Pain Scores at different time intervals
Table 4 : Change in Occlusion

Table 1 : Change in Mouth Opening at different time intervals

	Mean	SD	Change from baseline	Significance	
				"t - statistic"	"p - value"
Baseline	21.72	2.97	–	–	–
1 month	24.06	6.31	2.33±4.79	2.067	0.054
2 months	30.28	4.80	8.56±4.51	8.041	<0.001
3 months	37.11	2.11	15.39±3.57	18.305	<0.001

Table 2 : Change in TMJ Pain Scores at different time intervals

	Mean	**SD**	**Change from baseline**	**Significance**	
				"t statistic"	**"p value"**
Right side					
Baseline	2.22	2.13	–	–	–
1 month	0.94	1.00	-1.28±1.32	4.108	0.001
2 months	0.50	0.51	-1.72±1.74	4.194	0.001
3 months	0.06	0.24	-2.16±2.09	4.391	<0.001
Left side					
Baseline	2.11	2.22	–	–	–
1 month	1.00	1.09	-1.11±1.23	3.828	0.001
2 months	0.61	0.70	-1.50±1.65	3.848	0.001
3 months	0.17	0.38	-1.94±2.10	3.929	0.001

Table 3 : Change in Masticatory Muscle Pain Scores at different time intervals

	Mean	**SD**	**Change from baseline**	**Significance**	
				"t statistic"	**"p value"**
Right side					
Baseline	2.72	1.74	–	–	–
1 month	1.17	0.86	-1.56±1.04	6.336	<0.001
2 months	0.61	0.78	–2.11±1.45	6.174	<0.001
3 months	0.11	0.32	–2.61±1.65	6.714	<0.001
Left side					
Baseline	2.33	1.61	–	–	–
1 month	1.00	0.84	–1.33±1.14	4.973	<0.001
2 months	0.50	0.62	–1.83±1.25	6.230	<0.001
3 months	0.06	0.24	–2.28±1.53	6.331	<0.001

Table 4 : Change in Occlusion

S.No.	**Occlusion**	**Pre Operative**	**Post Operative**
1.	Deranged	26	0
2.	Normal	10	36

X^2=20.348; p<0.001



Figure 1

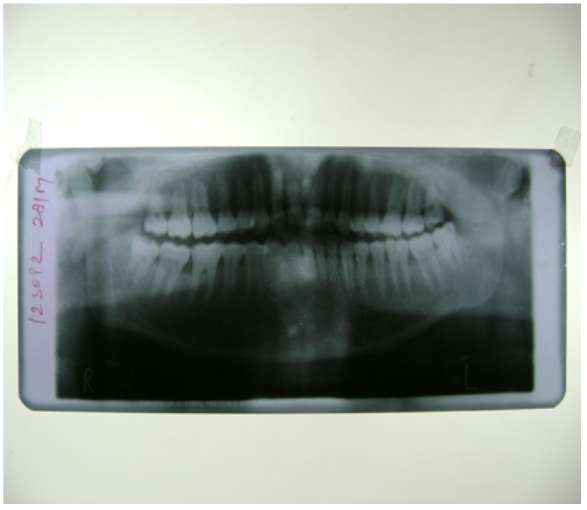

Figure 2



Figure 3



Figure 4



Figure 5

Graph 1 : Change in Lateral Movement at different time intervals

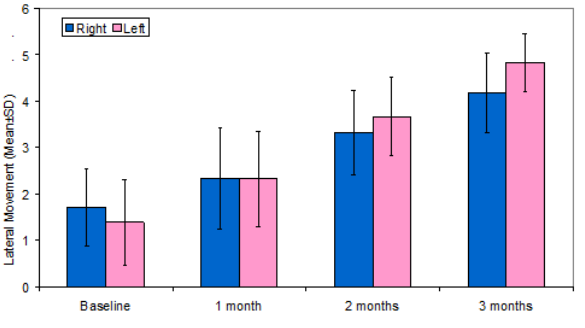

Graph 2 : Change in Protrusive Movement at different time intervals

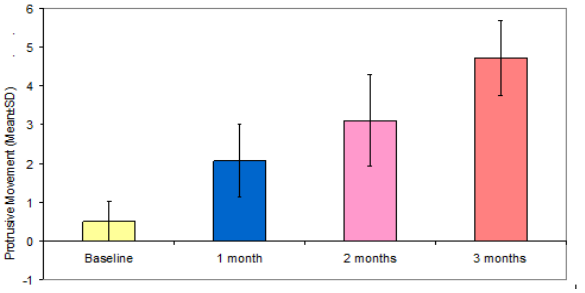

VOLUME-6 | ISSUE-4 | APRIL - 2017 • ISSN No 2277 - 8179 | IF : 4.176 | IC Value : 78.46

References

1. Talwar RM, Ellis III E, Throckmorton GS. Adaptations of the masticatory system after bilateral fractures of the mandibular condylar process. Journal of Oral & Maxillofacial Surgery 1998; 56:430-9.
2. Ellis III E, Throckmorton GS. Treatment of mandibular condylar process fractures: Biological considerations. Journal of Oral & Maxillofacial Surgery 2005; 63: 115-34.
3. Long X, Goss AN. A sheep model of intracapsular condylar fracture. Journal of Oral & Maxillofacial Surgery 2007; 65: 1102-8.
4. Long X, Cheng Y, Li X, Li H, Hu S. Arteriovenous fistula after mandibular condylar fracture. Journal of Oral & Maxillofacial Surgery 2004; 62: 1557-8.
5. Reid V. Mueller, Marcin Czerwinski, Chen Cee, Robert M. Kellman. Condylar Fracture Repair: Use of the Endoscope to Advance Traditional Treatment Philosophy. Facial Plastic Surgery Clinics of North America. 14(2006) 1-9
6. M. Todd Brandt & Richard H. Haug: Open versus closed reduction of adult mandibular condyle fractures: A review of the literature regarding the evolution of current thoughts of management. Journal of Oral & Maxillofacial Surgery; 61: pg 1324-1332, 2003
7. D. A. Mitchell, A multicentric audit of unilateral fractures of mandibular condyle, British Journal of Oral & Maxillofacial Surgery:35, 230 – 236, 1997
8. P. U. Dijkstra, PhD, B. Stegenga, L. G. M. de Bont, and R. R. M. Bos, Function Impairment and Pain After Closed Treatment of Fractures of the Mandibular Condyle. Journal of Trauma. 2005; 59:422– 428
9. Santler G, Kärcher H, Ruda C, Köle E. Fractures of the condylar process: surgical versus nonsurgical treatment. Journal of Oral & Maxillofacial Surgery 1999; 57: 392-7
10. Marker P, Nielsen A, Lehmann Bastian H. Fractures of the mandibular condyle. Part 2: results of treatment of 348 patients. British Journal of Oral and Maxillofacial Surgery 2000; 38: 422-6.
11. Zide M. F., Kent I.N.: Indication for open reduction of mandibular condyle fractures. Journal of Oral & Maxillofacial Surgery 41:89, 1983
12. Takenoshita and Ishibashi: Comparison of functional recovery after non surgical and surgical treatment of condylar fractures. Journal of Oral & Maxillofacial Surgery; 48: 1191-1195, 1990.
13. Celso Palmeieri, Edward Ellis III, Gaylord S. Throckmorton: Mandibular motion after closed and open treatment of unilateral mandibular condylar process fracture. Journal of Oral & Maxillofacial Surgery; 57, 764-775, 1999.
14. J.P.H.J. Rutges, E.H.W. Kruizinga, A. Rosenberg, R. Koole. Functional results after conservative treatment of fractures of the mandibular condyle. British Journal of Oral and Maxillofacial Surgery 45 (2007) 30–34
15. Kazuhiro Murakami, Kazuhiko Tamamoto, Tsutomu Suqiura, Yasu Tsugu Yamanaka, Tadaaki Kirita. Changes in mandibular movements and occlusal condition after conservative treatment for condylar fractures. Journal of oral & Maxillofacial Surgery; 67: 83 – 91, 2009