VOLUME-6 | ISSUE-1 | JANUARY-2017 • ISSN No 2277 - 8179 | IF : 3.508 | IC Value : 78.46

Original Research Paper

"RESULTS OF SUPRACONDYLAR INTERCONDYLAR HUMERUS FRACTURES TREATED WITH BIPILLAR PLATING: A STUDY OF 30 CASES"

Orthopaedic

KEYWORDS: Humerus, Supra condylar intercondylar Humerus fractures, Bipillar plating

Dr. Shailesh D. Ramavat	Associate Professor, Department of Orthopedics, P.D.U. Medical College Rajkot.
Dr. Surendra Choudhary	3rd Year Resident, Department of Orthopedics, P.D.U. Medical College Rajkot.
Dr. Dixit N. Savajiyani*	2nd Year Resident, Department of Orthopedics, P.D.U. Medical College Rajkot.*Corresponding Author
Dr. Manthan Soni	3rd Year Resident, Department of Orthopedics P.D.U. Medical College Rajkot.

ABSTRACT

Objectives: To evaluate anatomical and functional outcome of patients having the supracondylar inter-condylar humerus fracture treated with bipillar plating.

Introduction: Distal humerus fractures are uncommon injuries that account for fewer than 2% of all adult fractures, the complex shape of the elbow joint, the adjacent neurovascular structures, sparse soft tissue envelope, and association with significant displacement, comminution and osteopenia combine to make these fractures difficult to treat. But modern techniques of open reduction and internal fixation provide stable construct to allow early postoperative motion without compromising bone healing.

The principle of anatomic restoration of articular surface, stable fixation and early motion are the optimal treatment goals. With advance in current orthopedics management of this type of fracture is shifted to operative side with stable fixation and early mobilization of elbow in postoperative period.

Material and Methods: A prospective study of 30 cases of comminuted supracondylar inter condylar fracture of lower end humerus that were operated for that studied and followed up and results were obtained.

Results: A total 30 cases [15(50%) males and 15(50%) females] with supracondylar inter-condylar humerus fracture treated by bipillar plating and results were assessed in present series carried out from Oct 2014 to Oct 2016. Most common age group was ranging from 20-40 years [67%], right side more commonly affected [53%] and most common mode of trauma was vehicular accident [53%].Among the all 91% fractures were of closed variety. According to Riseborough and radin classification Type 3[37%] and type 4[50%] fractures are more common. 77% fractures were operated by triceps lifting approach and 23% were operated by posterior trans-olecranon approach. At 6 months follow-up range of motion was good in 64%, fair in 23% and poor in 13%. 54% of the operated patients resumed pre-injury level of work within 6 months, 43% patients resumed after 6 months and 3% patients had to change their profession. Among the all stiffness in postoperative period was most common complication seen in 46% of patients.

Conclusion: Out of 30 operated cases of intercondylar fractures fixation is best accomplished by dual plate fixation and postoperative physiotherapy is most vital part with more than 60% of excellent to fair results if aligned with minimum soft tissue damage.

INTRODUCTION

Distal humerus fractures are uncommon injuries that account for fewer than 2% of all adult fractures, the complex shape of the elbow joint, the adjacent neurovascular structures, sparse soft tissue envelope, and association with significant displacement, comminution and osteopenia combine to make these fractures difficult to treat. But modern techniques of open reduction and internal fixation provide stable construct to allow early postoperative motion without compromising bone healing.

Treatment, both surgical and nonsurgical has been associated with a high rate of complications and poor outcomes, when compared with other injuries.

The functions of elbow joint are essential for performing day to day activities, which requires the hands to reach the midline of the body such as in dressing, eating and combing hairs. This exact and demanding precision is frequently disturbed by inter condylar fracture which always results in loss of a few degree motion of the elbow regardless of any modalities of treatment.

The principle of anatomic restoration of articular surface, stable fixation and early motion are the optimal treatment goals. Recent treatment support, these goals and early postoperative active mobilization. By adhering to this protocol the literature supports this as the most reliable view for a good result.

The fabrication of new implants, however, has increased the reliability of operative stabilization, while placing additional demands upon the surgeon's expertise. The management of inter condylar fractures of humerus has progressed from conservative approach in form of cuff and collar sling, olecranon pin traction, closed reduction and pinning, closed reduction and plaster immobilization to the modern era of operative management in form of open reduction and rigid fixation, and further advancement in form of total elbow arthroplasty.

In this study we have reviewed the functional results obtained in a series of supracondylar intra articular fracture of the distal end of humerus treated by open reduction and internal fixation.

AIMS AND OBJECTIVES OF THE STUDY

To evaluate anatomical and functional outcome, impact of fixation related complication, post-operative complications like nonunion, malunion and infection of supracondylar intercondylar fractures. And also to evaluate the effect of this type of fracture on functional recovery and work capability in post-operative period.

MATERIALS AND METHODS

A prospective study of 30 cases of comminuted supracondylar inter condylar fracture of lower end humerus that were operated for that studied and followed up and results were obtained.

INCLUSION CRITERIA: **1**) Age between 18-70 years. 2) Men and Women both included in study. 3) Patients who have completed minimum of 6 months after surgery are included. 4)All types of fracture at distal humerus are included except open grade 3B. 5)Different mode of injuries are included by RTA, assaulted, fall from height, direct impact / shock.

VOLUME-6 | ISSUE-1 | JANUARY-2017 • ISSN No 2277 - 8179 | IF : 3.508 | IC Value : 78.46

EXCLUSION CRITERIA: **1)**Vascular injury. 2) Brachial plexus injury 3) Age less than 18 years 4) Age more than 70 year 5) Patient is not fit for surgery due to medical comorbidies.

After finding the suitability as per inclusion and exclusion criteria, patients were selected for the study and briefed about the nature of the study. The Intervention if any to be carried out and written, informed consent was Obtained .The consented patients were included in the present study. History was obtained through verbal communication, clinical examination both local and systemic was done along with assessment of distal neuro vascular status. For evaluation of results Riseborough and Radin criterias were used. Patient were followed up every week for 1st three months and then every 3 months interval until full range of motion is regained.

After diagnosing patient with anteroposterior and lateral roentgenogram of the elbow and evaluating the neurovascular examination proper implants were selected. After completing pre-anesthetic work up surgeries performed in either general or regional anesthesia by using either triceps lift or olecranon osteotomy or triceps split approach after posing patient in lateral position by posterior elbow approach. Depending on the type of fracture assessed with the help of radiograph usually 5-10 holed plate were kept for surgery along with cortical and locking screws with the help of the k wires and cancellous screws.

RESULTS AND DISCUSSION:

In this study maximum incidence was recorded in third and fourth decade of life. The youngest patient was 18 years and the oldest patient was 70 years old and incidence are equal in both male and female. among all 91% of fracture were closed and 9%were open and among open fractures most were compound Grade II injuries according to gustilo classification in our series.one patient having compound grade 2 fracture of distal humeres had infection in post-operative period that subside by debridement of wound and antibiotics. In this study maximum number of patients were of Type III, Type IV A are rare injuries and they are due to high velocity trauma grading of Riseborough and Radin system.

Among the all patients 57% of patients had complications following surgery, among them one patient developed infection of wound for which they required daily dressing and antibiotics. One patient had ulnar nerve palsy due to improper placement of implant and one patient had malunion leading to cubits varus deformity, one patient having myositis ossificans and none patients had implant failure.

Main complication is stiffness may be due to inadequate anatomical reduction of articular component, noncompliance of for physiotherapy

Among all 43% of patients could go back to their pre injury work in duration of 6 months. 54% could go to work after 6 month and 3% were not able to do work due to decrease in pronation, extension movement and post op ulnar nerve paresis.

According Riseborough and radin classification 64% patient had good, 23% had fair and 13% had poor results.

In this study postoperative mobilization of the elbow was started within 1-3 weeks in 77% cases, within 3-6 week in 23% in our series. Good range of motion achieved in 19 patients (64%) , fair amount of range of motion achieved in seven patients (23%) and poor range of motion achieved in four patient. With the help of physiotherapy, the range of movement achieved adequately even after immobilizing for more than 3 weeks. Poor result among type 4 due to inadequate anatomical restoration of articular surface even after best possible effort and noncompliance of patient towards physiotherapy because of post op pain and lack of awareness.

In type IV fracture, fair and poor results were because of articular and supracondylar comminution causing poor fixation, more soft tissue injury, require more immobilization, lack of active mobilization exercise and infection. Good results are more in triceps lifting (100%) compared to trans olecranon approach (57.28%).

In this study at last follow-up radiological signs of union seen in all cases while 3 patients had delayed union, because of old age, type 4 injury & prolonged period of immobilization and 3 patient had mal union.

In Jupiter series that was studied in 1985 Total no of patients were 34, average age of patient was 57.This suggest that inter condylar fractures are more common in middle and old aged patients. This is because of osteoporosis of bone, weakened metaphyseal bone and poor bone stock. So inter condylar fracture are easily caused by minor trauma like fall on elbow in middle and old age. Most common mode of trauma was fall on elbow in this series. In this study 79.4% were having good result, Poor results were in 8.8% cases.

In Henley Bradford series that was studied in 1987 total no of patients were 33, average age of patient was 30, and most common mode of trauma was vehicular accident. In this study 70% were having good result, Poor results were in 5.8% cases.

In current study total no of patients were 30, average age of patient was 35, this shift is due to increased incidence of road traffic accidents. Most common mode of trauma was road traffic accident. In this study 64% were having good result, Poor results were in 13% cases. This poor results is due to associated injuries prevents active mobilization of elbow causing severe restriction of elbow movement on long follow up, noncompliance of patient for physiotherapy.

SUMMARY AND CONCLUSION:

In this study 30 patients who were having supracondylar intercondyler fracture of distal humerus were studied and followed up.

- Most of the supracondylar intercondyler humerus fracture are caused by fall on elbow but recently they are more due to vehicular accidents.
- In supracondylar intercondyler humerus fracture Riseborough and Radin type III and IV are more common than Type I and II.
- Although Trans olecranon approach used less commonly, but it should be used in type IV fracture than Campbell's triceps tongue approach.
- Rigid internal fixation is best accomplished by dual plate fixation and for optimum biomechanical stability both plates should be placed at a right angle to each other.
- Post-operative physiotherapy is most vital part in management of supracondylar intercondyler humerus fracture and preferably physiotherapy should be started within 7 days of operation
- The ulnar nerve paresis can be prevented by proper placement of implants and size of implants and gentleness during surgery and inserting the screw from medially for intercondylar fracture.
- More than 90% of excellent to fair results can be obtained by open reduction internal fixation.
- The best results are obtained if the Supracondylar fracture of humerus fracture are reasonably aligned with minimum soft tissue damage.



Figure 1showing preoperative and post-operative roentgenograms and range of motion of elbow joint at 1 year follow-up of 50 year male patient having supra condylar intercondyler fracture of distal humers.

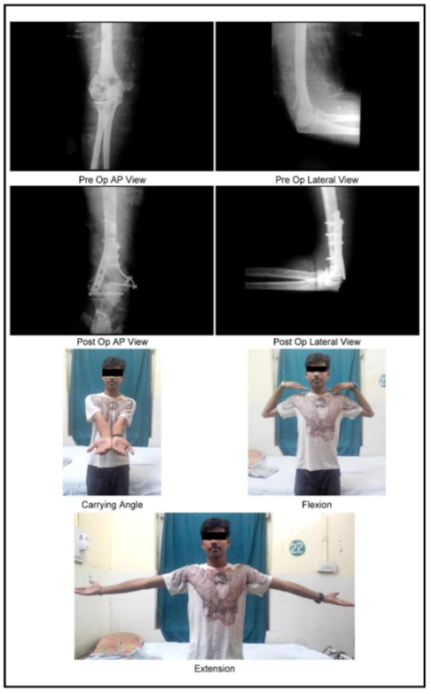

Figure 2 1showing preoperative and post-operative roentgenograms and range of motion of elbow joint at 9 months follow-up of 25year male patient having supra condylar intercondyler fracture of distal humers duo to direct fall on elbow..

References:

1. Wallace E. Miller: Comminuted fractures of the distal end of Humerus in adult. Journal of bone and joint surgery 46-A, 466-656, 1964.
2. Bryan T. Keon Cohen: Fractures at elbow. Journal of bone and joint surgery 48-A, 1627-1630, 1966.
3. Riseborough and Radin. Intercondylar "T" & "Y" fractures of lower end Humerus in adult. Journal of bone and joint surgery 51-A, 130-151, 1969.
4. R.F. Brown: Intercondylar T fractures of humerus treated conservatively. Journal of Bone and Joint Surgery 53-B, 425-428, 1971.
5. Bernard F. Morrey Passive motion of elbow; Journal of Bone and Joint Surgery. 58-A, 501-508, June 1976.
6. Jesse B. Jupiter Intercondylar Fractures of Humerus an operative approach 67-A, 226-239, and 1985.
7. Brain J. Hold worth. Fracture of adult distal humerus. Journal of Bone and Joint Surgery. 72-B, 362-365, 1990.
8. Hubert John. Operative treatment in distal humeral fractures in the elderly. 76-B, 993-996, 1994.
9. Tyson K. Cobb and Beonard F. Morrty Total elbow arthroplasty as primary treatment in distal humeral fractures in elderly patients. Vol. 79-A, 826-831, JBJS, 1997.
10. Richard S. Brayan. Extensive posterior exposure of elbow. Clinical Orthopedic and Related Research. 188-192, 1982, No. 166.
11. Joseph Zagorgki Comminuted I/A fractures of distal humerus surgical V/s non-surgical treatment. Clinical Orthopedic and Related Research, 197-204, 1986, No. 202.
12. Clinical Orthopedic and Related Research INO 359, 1993, Page 203-208.
13. Gerard T. Gabel. Intraarticular fractures of distal humerus in adult. Clinical Orthopedic and Related Research. 100-108, 1987, No. 216.
14. R. Leisch Intra-articular fractures of distal humerus surgical treatment and results. Clinical Orthopedic and Related Research 238-244, 1989, No. 214.
15. David Helfet Bicondylar intraarticular fracture of distal humerus in adults. Clinical Orthopedic and Related Research 26-36, 1993, No. 292.
16. Richard S. Bryan: Fractures about the elbow in adults. AAOS Instructional Course Vol. 30, 1981.
17. Bernard F. Morrey: Applied Anatomy and Biomechanics of the elbow joint. AAOS Instructional Course Vol. 30, 1981.
18. Bradford Henley: Intraarticular distal humeral fractures in adults. Orthopedics Clinics of North America. Vol. 18, No.1, 11-23, 1987.
19. Jerker Sodergard. Mechanical failure of internal fixation in T and Y fractures of distal humerus. Journal of Trauma Vol. 33, No.5, 1992.
20. Muller M.E. All Gover M, Schhelder R. and Willengegger H: Manual of internal fixation technique recommended by the A.O. Group. Edition. 2.
21. Watson Jones Reginald : Fractures and joint surgery Edition, 4, Volume 2
22. Campbell's Operative Orthopedics 9th & 10th Edition. Principles of fracture management. Vol.3, Chapter 54, Page 2539.
23. T.P. Ruedi and W.M. Murphy AO 10th Principles of fracture management.
24. Thomas G. Wadsworth: The Elbow (Churchill Livingston Company) Biomechanics of Elbow Forearm Complex Page 1-31, I/A Fracture L/E Humerus 210-216.
25. Cassebaum W.H. (1952). Operative treatment of T & Y fracture of L/E humerus (American Journal of Surgery Page 83-265).
26. Henry A.K. (1957). Baltimore Extensive Exposure (The Wilkins and Wilkins Company).
27. Bickel W & R Perry Journal of American Medical Association, 184-553.
28. R. Macrae and Edward Care Practical Exposure of Elbow. International student Edition, 64-66, 325-329.
29. Bryan R.S. and Bickel L.H.T. Condylar L/E S/H Journal of Trauma (1971), 11, 830.
30. Rockwood and Greens fracture in adult of Vol. I. Lawrence X Wel. 953-971. (Lippincott and William and Wilkins Company)
31. David A. Kuntz (1999 - January) Elbow Trauma and Reconstruction (37-45) Ortho. Clinics of North America, Vol. 301.
32. Wickstrom, T. and Meyer P.R. (1967). Fracture distal humerus in adults. 43-50.
33. Dr. Vijay Sharma, Dr. PP Kotwal, Orthopedics Today Journal, July-September 2004, Vol. VI, No. 3. pg. 155-163.
34. Kasser JR, Richards K, Millis M. The triceps-dividing approach to open reduction of complex distal humeral fractures in adolescents: A Cybex evaluation of triceps function and motion. J Pediatr Orthop. 1990;10:93–6.
34. Bass RL, Stern PJ. Elbow and forearm anatomy and surgical approaches. Hand Clin. 1994;10:343–56.
36. Macko D, Szabo RM. Complications of tension band wiring of olecranon fractures. J Bone Joint Surg Am. 1985;67:1396–401.
37. Horne JG, Tanzer TL. Olecranon fractures: A review of 100 cases. J Trauma. 1981; 21:469–72.
38. Ring D, Gulotta L, Chin K, Jupiter JB. Olecranon osteotomy for exposure of fractures and nonunion of the distal humerus. J Orthop Trauma. 2004; 18:446–9.
39. Gainor BJ, Moussa F, Schott T. Healing rate of transverse osteotomies of the olecranon used in reconstruction of distal humerus fractures. J South Orthop Assoc. 1995; 4:263–8.
40. Wilkinson JM, Stanley D. Posterior surgical approaches to the elbow: A comparative anatomic study. J Shoulder Elbow Surg. 2001; 10:380–2.
41. Askew LJ, An KN, Morrey BF, Chao EY. Isometric elbow strength in normal individuals. Clin Orthop Relat Res. 1987; 222:261–6.
42. Ozer H, Solak S, Turanli S, Baltaci G, Colakoglu T, Bolukbasi S. Intercondylar fractures of the distal humerus treated with the triceps-reflecting anconeus pedicle approach. Arch Orthop Trauma Surg. 2005; 125:469–74.