Original Research Paper

VOLUME-6 | ISSUE-4 | APRIL - 2017 • ISSN No 2277 - 8179 | IF : 4.176 | IC Value : 78.46

Retinal and choroidal changes in a case of incomplete central retinal artery occlusion associated with short posterior ciliary artery occlusion

Ophthalmology

KEYWORDS: central retinal artery occlusion, short posterior ciliary artery, optical coherence tomography, retinal thickness, choroidal thickness

Shinji Makino

Department of Ophthalmology, Jichi Medical University, Shimotsuke, Tochigi, Japan

ABSTRACT

We evaluated retinal and choroidal changes in a case of incomplete central retinal artery occlusion (CRAO) associated with short posterior ciliary artery (SPCA) occlusion. Fundus examination showed multiple soft exudates around the optic disc and retinal edema in his right eye. Fluorescein angiography revealed delayed dye inflow into the nasal choroidal hemisphere that is supplied by the SPCA. At the initial visit, optical coherence tomography (OCT) image of affected eye showed increased reflectivity and thickness of the inner retina, as compared with the contralateral eye. In addition, choroidal thickness of affected eye was thicker than that of contralateral eye. During follow-up period, OCT image of affected eye showed decreased reflectivity and thickness of the inner retina. Choroidal thickness of affected eye was also gradually reduced, as compared with the initial visit. In conclusion, the present study identified morphologic changes of the retina and choroid in eyes with incomplete CRAO.

INTRODUCTION

A central retinal artery occlusion (CRAO) is one of the most serious vascular obstructive disorders of the eye.[1-5] Ophthalmoscopic changes in CRAO include retinal edema with a cherry red spot in the acute phase, and narrowing of retinal vessels, decrease in the depth of the foveal pit, and optic disc atrophy in the chronic phase.[1-5]

Few reports have described the use of optical coherence tomography (OCT) to examine cases of CRAO.[1-5] Previous studies have focused predominantly on changes to the inner retina and have shown inner retinal edema in eyes with acute CRAO and inner retinal thinning at subsequent phases.[2-5] Ahn et al.[1] investigated the retinal and choroidal changes using spectral-domain OCT and to identify factors associated with visual outcome in eyes with CRAO.

Here, we investigate the retinal and choroidal thickness in a case of incomplete CRAO associated with short posterior ciliary artery (SPCA) occlusion.

CASE PRESENTATION

A 66-year-old man complaining of sudden blindness in his right eye was referred to our hospital. His visual acuity (VA) was 0.05 in the right eye and 1.2 in the left eye. Fundus examination showed several soft exudates around the optic disc and retinal edema in the macula of his right eye; however, typical cherry red spot was not detected (Figure 1A).

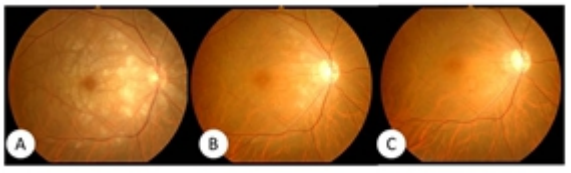

Fig. 1 Right fundus photographs at the initial visit and after the visit.

A; initial visit, B; 2 months later, C; 4 months later
Note soft exudates gradually reduced.

Fluorescein angiography revealed a delay of arm-to-retina time and a marked filling delay of the nasal choroidal hemisphere that is supplied by nasal SPCA. In addition, the choriocapillaris corresponding to the nasal choroidal area filled slowly and patchily. From these findings, the patient was diagnosed with incomplete CRAO associated with SPCA occlusion. Systemic administration of a vasodilator and an anti-platelet agent were started after the initial examination. During observation, soft exudates gradually decreased (Figure 1B), and finally disappeared (Figure 1C). His VA improved to 0.5 in the right eye.

At the initial visit, OCT image of affected eye showed increased reflectivity and thickness of the inner retina (Figure 2A, B arrows), as compared with the contralateral eye (Figure 2C, D). In addition, choroidal thickness of affected eye (Figure 2A, B framed arrows) was thicker than that of contralateral eye (Figure 2C, D framed arrows).

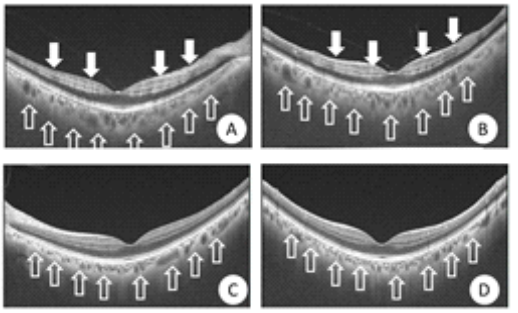

Fig. 2 OCT images of the right (A and B) and left (C and D) eyes at initial visit

(A, C: horizontal scan, B, D: vertical scan)
Note increased reflectivity and thickness of the inner retina in the right eye (A, B arrows). In the right eye, choroidal thickness (framed arrows) was thicker than that in the left eye.

During follow-up period, OCT image of affected eye showed decreased reflectivity and thickness of the inner retina (Figure 3 A-F). Choroidal thickness of affected eye was also gradually reduced (Figure 3 C-F), as compared with the initial visit (Figure 3A, B).

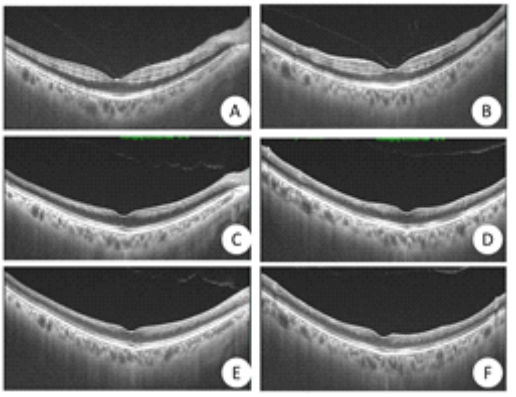

Fig. 3 Right OCT images at the initial visit and after the visit
(A, C, E: horizontal scan, B, D, F: vertical scan)
A, B; initial visit, C, D; 2 months later, E, F; 4 months later
Note retinal and choroidal thickness gradually reduced.

DISCUSSION

Schmidt et al.[6] categorized CRAO as incomplete, subtotal, or total

CRAO on the basis of the degree of vision loss, extent of retinal edema, and delay in arterial blood flow. Incomplete CRAO is characterized by diminished visual acuity with slight retinal edema and a cherry-red spot. Subtotal CRAO presents as a severe reduction in VA and distinct retinal edema and a cherry-red spot. Total CRAO is distinguished from the other 2 stages by the presence of massive edema and occluded perimacular arterioles. The fundus changes in stage I described in their literature were very similar to those in our case. However, to our knowledge, incomplete CRAO associated with SPCA occlusion is extremely rare.[7,8]

Previous case studies that have reported OCT findings in eyes with CRAO have demonstrated (1) an increased reflectivity and thickness of the inner retina in the acute phases and (2) a decrease in the reflectivity and thickness of the inner retinal layers and a corresponding increase in reflectivity of the outer retina and retinal pigment epithelium and choriocapillaris layer in follow-up evaluations.[2-5] The hyperreflectivity and inner retinal edema are considered to be associated with opacification and edema of the retinal nerve fiber and ganglion cell layer resulting from cessation of axoplasmic transport after ischemic damage. In 2015, Ahn et al.[1] investigated the retinal and choroidal thickness in each stage of CRAO. Their imaging study identified distinctive features of CRAO at each stage, including minimal loss of the organized layered structure of the inner retina and inner retinal hyperreflectivity without distinct macular edema in cases of incomplete CRAO, distinct macular edema and loss of the organized layered structure of the retina in subtotal CRAO, and marked macular edema and subfoveal choroidal thinning in total CRAO. Morphologic features and parameters of thickness of the retina and choroid obtained by OCT therefore may facilitate staging of CRAO and the evaluation of retinal ischemia.[1] According to their report, outer retinal thinning and photoreceptor defects occur most predominantly in eyes with subtotal and total CRAO. These changes may be associated with choroidal ischemia, because the choroidal vessels supply the outer retinal layers, including the photoreceptors. Choroidal thickness is considered to represent choroidal blood flow, where an increase in choroidal blood flow is associated with an increase in choroidal thickness. Choroidal thinning in eyes with CRAO therefore may represent acute choroidal ischemia, subsequently leading to outer retinal damage and atrophy. In contrast, choroidal thickening was detected in acute phase in this present case. We speculated that choroidal ischemia might be mild because of incomplete CRAO with nasal SPCA occlusion.

CONCLUSIONS

In conclusion, the present study identified morphologic changes of the retina and choroid in eyes with incomplete CRAO. Accumulation of reports may be needed.

REFERENCES:

[1] Ahn, S.J., Woo, S.J., Park, K.H., Jung, C., Hong, J.H., and Han, M.K. (2015) "Retinal and choroidal changes and visual outcome in central retinal artery occlusion: an optical coherence tomography study." American Journal of Ophthalmology, 159, 667-676.
[2] Dotan, G., Goldenberg, D., Kesler, A., Naftaliev, E., Loewenstein, A., and Goldstein, M. (2014) "'The use of spectral-domain optical coherence tomography for differentiating long-standing central retinal artery occlusion and nonarteritic anterior ischemic optic neuropathy." Ophthalmic Surgery, Lasers & Imaging Retina, 45: 38-44.
[3] Chen, S.N., Hwang, J.F., and Chen, Y.T. (2011) "Macular thickness measurements in central retinal artery occlusion by optical coherence tomography." Retina, 31, 730-737.
[4] Falkenberry, S.M., Ip, M.S., Blodi, B.A., and Gunther, J.B. (2006) "Optical coherence tomography findings in central retinal artery occlusion." Ophthalmic Surgery, Lasers & Imaging, 37, 502-505.
[5] Ozdemir, H., Karacorlu, S., and Karacorlu, M. (2006) "Optical coherence tomography findings in central retinal artery occlusion." Retina, 26, 110-112.
[6] Schmidt, D.P., Schulte-Monting, J., and Schumacher, M. (2002) "Prognosis of central retinal artery occlusion: local intraarterial fibrinolysis versus conservative treatment." American Journal of Neuroradiology, 23, 1301-1307.
[7] Kanbara, Y., Oku, H., Kida, T., and Ikeda, T. (2004) "A case of incomplete central retinal artery occlusion associated with ischemic optic neuropathy." Japanese Review of Clinical Ophthalmology, 98, 574-577.
[8] Makino, S., Takezawa, M., and Sato, Y. (2013) "A case of incomplete central retinal artery occlusion associated with short posterior ciliary artery occlusion." Case Report of Ophthalmological Medicine, Article ID 105653.