ORIGINAL RESEARCH PAPER

Volume-8 | Issue-7 | July - 2019 | PRINT ISSN No. 2277 - 8179

INTERNATIONAL JOURNAL OF SCIENTIFIC RESEARCH

ROLE OF 3T MAGNETIC RESONANCE CHOLANGIOPANCREATOGRAPHY (MRCP) IN BILIARY STRICTURES IN ADULT POPULATION OF WESTERN INDIA

Radiodiagnosis

Dr. Suvinay Saxena* — Consultant Radiologist, Bansal Hospital, Bhopal. *Corresponding Author

Dr. Dinesh Prajapati — Author, Consultant Radiologist, Gujarat MRI Centre Pvt Ltd., Samved Hospital, Commerce College Road, Navrangpura, Ahmedabad, India.

Dr. Mrugesh Doctor — Senior Consultant radiologist, Gujarat MRI Centre Pvt Ltd., Samved Hospital, Commerce College Road, Navrangpura, Ahmedabad, India.

Dr. Hemant Patel — Senior consultant radiologist, Gujarat MRI Centre Pvt Ltd., Samved Hospital, Commerce College Road, Navrangpura, Ahmedabad, India.

ABSTRACT

The aim of the study was to evaluate role of Magnetic Resonance Cholangiopancreatography in differentiating benign from malignant causes of biliary strictures in adults using surgical, ERCP or histo-pathological findings as gold standard.

The objectives of the study were to confirm the diagnosis of the biliary strictures , to localize the level of obstruction, to characterize the morphological features of stricture to differentiate benign from malignant cause on MRCP imaging and correlate with the surgical/ ERCP / histo-pathological findings whenever its applicable.

Study was conducted in Gujarat Imaging centre Post graduate institute of Radiology and Imaging (GIC-PGIR), Samved hospital, Ahmedabad .Patients with clinical and laboratory finding suggestive of biliary obstruction were imaged . A prospective study was performed evaluating 80 patients for a duration of 1 year with clinical and laboratory finding suggestive of biliary obstruction referred to the hospital for Magnetic resonance Cholangiopancreatography.

MRI (3- Tesla, Philips achieva with 16 array channel coil) with high resolution specific serial sections. Diagnostic effectivity was calculated for MRCP which included sensitivity, specificity and accuracy by comparing with surgical, histopathological or ERCP findings. Statistical analysis was done by using chi-square test and p-value was calculated.

We observed high sensitivity and specificity of MRCP in differentiating benign from malignat biliary strictures. In this study, 20 cases of benign stricture were correctly diagnosed on MRCP based on patient's clinical history and MR characteristic findings. Two cases which were coined as benign strictures of distal CBD on MRCP, turned out malignant on post interventional cytology result. 31 cases of malignant stricture were correctly diagnosed on MRCP.Overall diagnostic accuracy of MRCP in differentiating benign from malignant biliary strictures in correlation with ERCP, surgical and histo-pathological outcome was 94.44 % , sensitivity 93.94% , specificity was 95.24%. PPV 96.87 % and NPV 90.91%.

KEYWORDS

MRCP, stricture, benign, malignant.

Biliary stricture is a fixed narrowing of a focal segment of the bile duct that results in proximal biliary dilatation and clinical features of obstructive jaundice. A wide spectrum of hepatobiliary and pancreatic diseases, both benign and malignant, can result in the development of biliary strictures. It is important to differentiate malignant from benign strictures, since their treatment and prognosis vary accordingly .(1)

Noninvasive imaging techniques such as ultrasonography (US), computed tomography (CT), and magnetic resonance (MR) imaging play an important role in the evaluation of patients with suspected biliary stricture. Among these techniques, MR imaging with MRCP offers the most comprehensive evaluation. Although ERCP with tissue biopsy or surgery is needed for the definitive diagnosis of biliary strictures.

MR imaging in a patient with suspected biliary obstruction can determine the presence of obstruction, level of obstruction (intra- or extra hepatic ducts), approximate length of the biliary stricture, and status of the proximal bile ducts. MR cholangiopancreatographic images generates a "road map" for ERCP or percutaneous transhepatic cholangiography (PTC) for clinicians.(2,3)

Eliciting the number, location, and length of the strictures helps in selecting the appropriate stent for treatment(4).

Benign obstruction is most commonly caused by choledocholithias. Malignant obstruction is most commonly caused by cholangiocarcinoma.

Recent advances of MR imaging, namingly fast imaging sequences, phased-array coils, parallel imaging techniques & 3.0-T magnets allow acquisition of good quality diagnostic images in less time.(5-7) .MR cholangiopancreatographic techniques involve the use of heavily T2-weighted sequences to accentuate the high signal from relatively static fluid in the biliary tract while suppressing the signal from background tissues.(8)

NORMAL ANATOMY

The individual biliary drainage system is parallel to the portal venous supply system. The right hepatic duct drains the segments of the right liver lobe (V-VIII). The right hepatic duct has two major branches: The right posterior duct draining the posterior segments, VI and VII, and the right anterior duct draining the anterior segments, V and VIII. The left hepatic duct is formed by segmental tributaries draining segments II-IV. Segment I drains via a separate bile duct usually into the origin of the left or right hepatic duct. **(Fig 1)**Only central intra-hepatic bile ducts are normally seen on MRCP , usually measuring up to 3 mm in diameter and extra-hepatic bile ducts should not exceed 7 mm. In patients with a previous cholecystectomy, mild biliary dilatation occurs, with the CBD measuring up to 10 mm in diameter.(9-10)

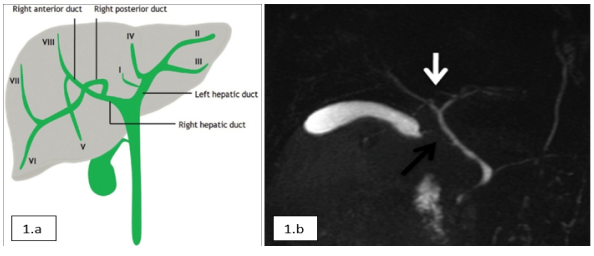

Figure 1 (a & b) Pictorial diagram showing normal Biliary anatomy and Projection 3D coronal MRCP image s howing fusion of the right anterior and right posterior ducts to form the right hepatic duct. Primary confluence (white arrow) is formed by fusion of the right and left hepatic ducts. Cystic duct (black arrow) joins the common hepatic duct in its lateral part to form the common bile duct.

BENIGN BILE DUCT STRICTURES

In western countries, iatrogenic stricture is the most common benign biliary stricture and accounts for up to 80% of all benign strictures(12).

In India, Cholecystectomy is the most common iatrogenic causes of benign biliary stricture. A spectrum of diseases such as chronic pancreatitis, autoimmune cholangitis associated with autoimmune pancreatitis, recurrent cholangitis, HIV cholangiopathy, primary sclerosing cholangitis and Mirizzi syndrome can also result in biliary stricture.(13)

Benign strictures of the biliary tract are associated with a broad spectrum of signs and symptoms; from subclinical disease with mild elevation of liver enzyme to elevated bilirubin and complete obstruction with jaundice, pruritus and cholangitis progressing ultimately to biliary cirrhosis. (14) Most strictures post laparoscopy procedure are short and occur more commonly in the common hepatic duct, distal to the confluence of the right and left hepatic ducts. After open cholecystectomy, strictures are more common in the CBD. (15)

Certain characteristics on MR imaging might help differentiating benign from malignant types of biliary stricture and these are summarized in **[Table 1].** Despite considerable overlap, there are some imaging features that may indicate malignant or benign features.

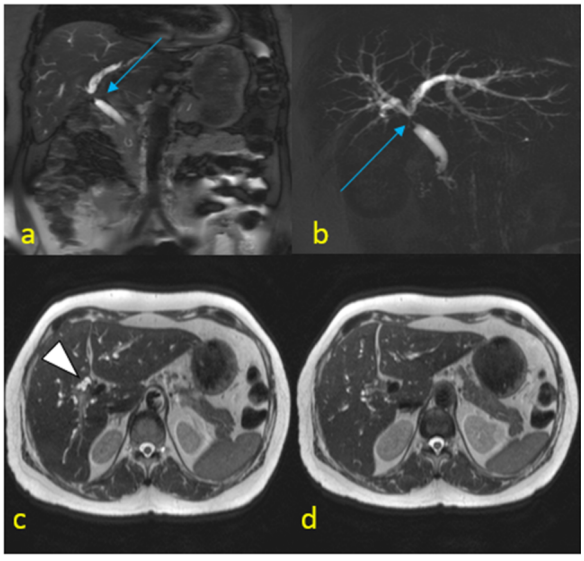

Case 1 Male 45 years with previous h/o cholecystectomy, presented with features of obstructive jaundice. **Figure 1a & 1b** Coronal T2W and projection 3D images show short segmental tight stricture (arrows) with abrupt cut off at the level of CHD with resultant marked upstream dilatation of biliary tree. Mildly dilated common bile duct is seen with small calculus at its lower end

Figure 1c &1d Consecutive axial MR images at the level of stricture shows a small subtle (arrow) along the wall of common hepatic duct. Arrow head in image 1c shows dilated primary confluence proximal to the stricture.

Possibility of post operative benign stricture was given on MRCP. Post interventional cytology confirmed the benign nature of the stricture.

Table 1. Characteristics of strictures (16-18 & 21-23)

BENIGN STRICTURE	MALIGNANT STRICTURE
Solitary or Multiple	Solitary
Short or long segment involvement	Long or short segment
Smooth margins	Irregular margins
Smooth transition/ smooth tapering	Abrupt transition
No shouldering	Shouldering of edges
Absence of obvious discrete mass	Asymmetric dilatation of IHBR

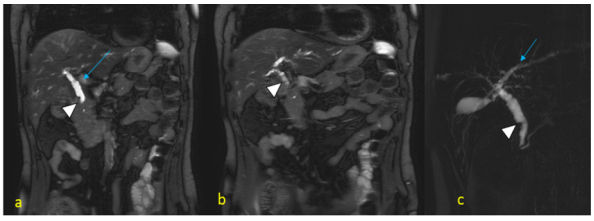

Case 2 55 years old male with a history of ulcerative colitis presented with abdominal pain, jaundice and pruritus. Figure 2a & 2b : MR T2W coronal and projection 3D images shows diffuse involvement of biliary tree with mild wall-thickening & irregularity involving CBD (arrow head) , left hepatic duct (arrow) and biliary radicles of left lobe with mild dilatation of the lumen. **Figure 2c :** Projection MRCP 3D image shows diffuse involvement of CBD (arrow heads) and left hepatic duct (arrow) with biliary dilatation.

In view of known history of inflammatory bowel disease , diagnosis of primary sclerosing cholangitis (PSC) was made. Subsequent liver biopsy suggested stage II changes of the PSC. ERCP with cytology did not reveal malignant changes

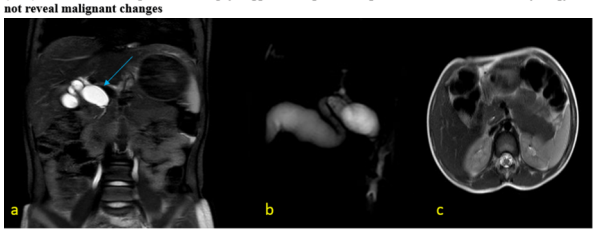

Case 3 Female 28 years with chronic abdominal pain and mild elevation of serum bilirubin. **Figure 3a & 3b :** MR T2W coronal and projection 3D images show of focal fusiform dilatation of mid part of common bile duct(arrow). The proximal and distal common bile duct appear normal (arrow heads). The gall bladder appears distended with prominent cystic duct(arrow in figure 2a)

Figure 3c: Selected MR T2W axial image at the level of distal to the dilatation of mid CBD shows normal appearance of distal CBD. No obvious calculus or discrete mass was identified. - **Choledochal cyst type IVb involving the mid CBD.**

MALIGNANT BILIARY STRICTURES

Malignant obstruction is more common in older age group and most commonly caused by cholangiocarcinoma. Other causes are carcinoma gall bladder, carcinoma head of pancreas, ampullary and periampullary mass, lymph nodes and metastasis.

Cholangiocarcinoma :

Cholangiocarcinoma is a malignant neoplasm of the biliary tree. There are 3 types of cholangiocarcinomas depending on the morphologic appearance: mass forming, periductal infiltrating, and intraductal growing. The most common site of involvement is the confluence of the right and left hepatic ducts called a Klatskin or hilar cholangiocarcinoma (50%-60%) . The next common site is the extra hepatic duct (30%-35%) with intra hepatic being the least common site (10%). (18)

Imaging features of malignant strictures

Long segment narrowing is more commonly found in malignant strictures and short segment strictures are more commonly benign in nature. Malignant strictures are usually long as they have an infiltrative growth pattern, spreading intra-murally beneath the epithelial lining. They usually show abrupt cut off with irregular margins**.** Presence of mass is highly suggestive of malignant nature of obstruction. Asymmetrical dilatation is also one of the important findings encountered in malignant strictures.(18-21)

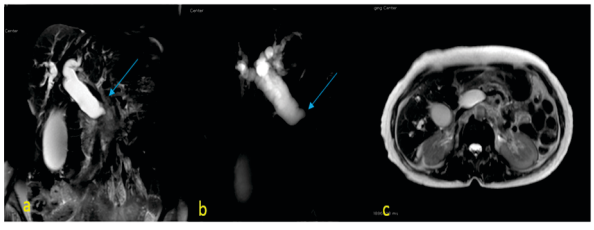

CASE 4 :A 56 years old female with c/o jaundice and abdominal pain and weight loss. Her S.bilirubin level was 5.6 mg/dL.**Figure 4a & 4b** MR T2W coronal and projection 3D MIP images show markedly dilated intrahepatic biliary radicles, right & left hepatic ducts, common hepatic duct and common bile duct with abrupt cut-off of distal end of common bile (arrow in image 1a).

Figure 4c Selected MR T2W axial image at the level of distal CBD doesn't reveal obvious discrete mass at the level of stricture. However in view of abrupt cut off and marked dilatation of biliary tree and mild subtle irregularities of stricture margins possibility of malignant stricture was given.

ERCP and histo-pathological findings favoured the malignant aetiology – **cholangiocarcinoma**.

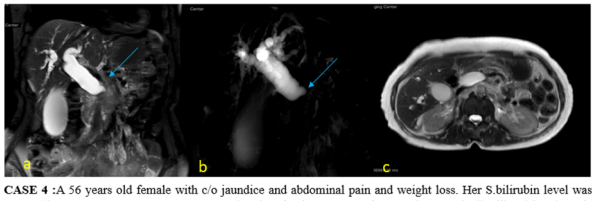

CASE 4 :A 56 years old female with c/o jaundice and abdominal pain and weight loss. Her S.bilirubin level was 5.6 mg/dL.**Figure 4a & 4b** MR T2W coronal and projection 3D MIP images show markedly dilated intrahepatic biliary radicles, right & left hepatic ducts, common hepatic duct and common bile duct with abrupt cut-off of distal end of common bile (arrow in image 1a).

Figure 4c Selected MR T2W axial image at the level of distal CBD doesn't reveal obvious discrete mass at the level of stricture. However in view of abrupt cut off and marked dilatation of biliary tree and mild subtle irregularities of stricture margins possibility of malignant stricture was given.

ERCP and histo-pathological findings favoured the malignant aetiology – **cholangiocarcinoma**.

MR cholangiopancreatography is performed initially with 7-cm-thick coronal and axial sections (ie, thick slabs) of the upper abdomen to establish the location of the extrahepatic bile ducts. Cholangiopancreatographic images are then acquired in the coronal oblique plane along the longitudinal axis of the ducts with a thin-slab multi section technique (24-25)

Table 3: Limitations of MRCP

Partial volume loss –due to MIP reconstruction
Respiratory motion artifact
Static images and Low spatial resolution
Metallic foreign body rarely cause susceptibility artifact
Central low signal flow void may mimic stent or worm

DISCUSSION

In our study, 48 (60 %) cases were benign and 32 (40 %) were malignant in nature. Malignant obstructions were more common in older patients as compared with benign lesions. The most common presenting complaints of the subjects with benign obstruction were abdominal pain and jaundice while in malignant obstruction the chief complaints were abdominal pain, jaundice and weight loss.

Of total 48 benign cases, the most common cause of obstruction was choledocholithias (12 cases). The second common cause was inflammatory strictures which were seen in total 10 patients. Most common cause of inflammatory stricture was found to be pancreatitis in 7 cases. The second most common cause of benign stricture was iatrogenic post cholecystectomy strictures (37%). The most common cause of malignant obstruction in our study was cholangiocarcinoma (37%) . The other most common causes of malignant obstruction was found to be periampullary (25%) and gall bladder carcinoma (22%).

In benign causes the most common location of obstruction was found at the level of distal intrapancreatic CBD (54%) followed by CHD and primary confluence (33%).

We found that smooth margins with short segmental narrowing and symmetrical dilatation of IHBR were more commonly found in benign strictures. Irregular margins ($p<0.0001$), asymmetric and long segment narrowing was more commonly found in malignant stricture. Presence of mass ($p< 0.0001$) was highly specific for malignant strictures but absence of mass did not rule out possibility of malignancy. Abrupt or gradual tapering did not show any specific distribution and was not helpful in differentiating benign from malignant stricture. **Park *et al***.[12] found stricture length with irregular margin and asymmetric narrowing of bile ducts to suggest a malignant aetiology. **Bain *et al***.[35] found long stricture and the presence of intra hepatic duct dilatation to suggest a malignant aetiology.

Two cases which were coined as benign strictures of distal CBD on MRCP, turned out malignant on post interventional cytology result. Thus sensitivity of MRCP for detection of benign strictures was 95.65%, specificity 93.94 % and diagnostic accuracy was 94.79 %

In our study, overall diagnostic accuracy of MRCP in differentiating benign from malignant biliary strictures in correlation with ERCP, surgical and histo-pathological outcome was 94.44 % , sensitivity 93.94% , specificity was 95.24%. PPV 96.87 % and NPV 90.91%.

In 2015 **Suthar et al.** [17] in their statistical analysis found that sensitivity, specificity and diagnostic accuracy of MRCP for differentiation of benign from malignant causes of biliary obstruction was 85.7%, 96.3%, and 93.3% respectively. **Saluja et al**.[14], found sensitivity, specificity and diagnostic accuracy of MRCP for biliary obstructive diseases in their study to be 87.5%, 85.3% and 82.7% respectively. **Park et al.**[12], found that the sensitivity, specificity, and accuracy of MRCP for differentiation of malignant from benign causes of biliary stricture were 81%, 70%, and 76% respectively. In a study by **Obaidi et al**,[23] the sensitivity, specificity, negative predictive value, positive predictive value, and diagnostic accuracy for benign strictures were 100%, 98.5%.

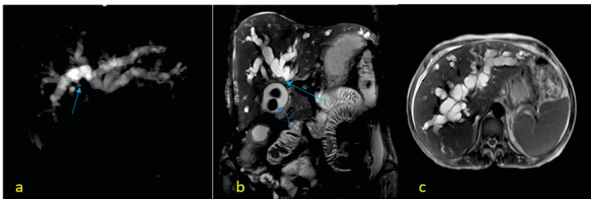

Case 5 Female 74 years with abdominal pain and jaundice and significant weight loss ins over a period of 4 months . S,bilirubin - 8.9 mg/dL . **Figure 5a :** projection 3D image shows abrupt cut off (arrow)at the level of CHD with irregular margins and marked dilatation of the IHBR. **Figure 5b &5c**:T2W axial and coronal images show marked dilated IHBR with subtle irregular soft tissue at the level of stricture (arrow in b) . Distended gall bladder with intra cystic calculi are present.(curved arrow) **MRCP diagnosis of hilar cholangiocarcinoma (Klatskin) was made . Post surgical histo-pathology confirmed the malignancy.**

CONCLUSION

MRCP is an accurate, non invasive means of evaluation of wide spectrum of causes for biliary strictures in adult patients, including both benign and malignant conditions. By this study we could show the accuracy and limitation of MRCP for detection of presence, level and cause of biliary obstruction. Benign or malignant nature of biliary obstruction can be assured by MRCP by observation of stricture margin, dilatation, and length and accordingly proceed to next step in management. Furthermore MRCP may be considered as an alternative to diagnostic ERCP for investigating biliary obstruction where ductal system can nicely be demonstrated proximal to the obstruction on MRCP.

Abbreviations

MRCP: Magnetic resonance cholangiopancreatography
ERCP: Endoscopic retrograde cholangiopancreatography
MRI: Magnetic resonance imaging
T1W: T1 weighted
T2W: T2 weighted
MIP: Maximum intensity projection
RHD: Right hepatic duct
LHD: Left hepatic duct
CHD: Common hepatic duct
IHBR : Intrahepatic biliary radicles
PSC : Primary sclerosing cholangitis

REFERENCES

1. Lee MG, Lee HJ, Kim MH, Kang EM, Kim YH, Lee SG, et al. Extrahepatic biliary diseases: 3D MR Cholangiopancreatography compared with endoscopic retrograde cholangiopancreatography. Radiology. 1997;202(3):663–69.
2. Hintze RE, Adler A, Veltzke W, Abou-Rebyeh H, Hammerstingl R, Vogl T, et al. Clinical significance of magnetic resonance cholangiopancreatography (MRCP) compared to endoscopic retrograde cholangiopancreatography (ERCP) Endoscopy. 1997;29(3):182–87.
3. Fulcher AS, Turner MA, Capps GW, Zfass AM, Baker KM. Half-Fourier RARE MR Cholangiopancreatography: experience in 300 subjects. Radiology. 1998;207:21–32.
4. Adamek HE, Albert J, Weitz M, Breer H, Schilling D, Riemann JF. A prospective evaluation of magnetic resonance cholangiography in patients with suspected bile duct obstruction. Gut. 1998;43:680–83.
5. Schwartz LW, Coakley FV, Sun Y, Blumgart LH, Fong Y, Panicek DM. Neoplastic Pancreaticobiliary Duct Obstruction: Evaluation with Breath- Hold MR Cholangiopancreatography. AJR. 1998;170:1491–95.
6. Varghese JC, Liddell RP, Farrell MA, Murray FE, Osborne DH, Lee MJ. Diagnostic accuracy of magnetic resonance cholangiopancreatography and ultrasound compared with direct cholangiography in the detection of Choledocholithiasis. Clin Radiol. 2000;55(1):25–35.
7. Shanbhogue AKP, Tirumani SH, Prasad SR, Fasih N, McInnes M. Biliary Strictures: A Current Comprehensive Clinical and Imaging Review. AJR. 2011;197:W295–306
8. Kim MJ, Mitchell DG, Ito K, Outwater EK. Biliary dilatation: differentiation of benign from malignant causes-value of adding conventional MR imaging to MR Cholangiopancreatography. Radiology. 2000;214:173–81.
9. Yu XR, Huang WY, Zhang BY, Li HQ, Geng DY. Differentiation of infiltrative cholangiocarcinoma from benign common bile duct stricture using three-dimensional dynamic contrast-enhanced MRI with MRCP. Clinical Radiology. 2014;69:567–73.
10. Zidi SH, Prat F, Guen OL, Rondeau Y, Pelletier G. Performance characteristics of magnetic resonance cholangiography in staging of malignant hilar strictures. Gut. 2000;46:103–06
11. Lopera JE, Soto JA, Múnera F. Malignant Hila and perihilar Biliary Obstruction: Use of MR cholangiography to define the extent of Biliary Ductal involvement and plan percutaneous interventions. Radiology. 2001;220(1):90–96.
12. Park MS, Kim TK, Kim KW, Won K, Park SW, Lee JK, et al. Differentiation of extrahepatic bile duct cholangiocarcinoma from benign stricture: finding at MRCP versus ERCP. Radiology. 2004;233:234–40.
13. Kim JY, Lee JM, Han JK, Kim SH, Lee JY, Choi JY, et al. Contrast-enhanced MRI combined with MR Cholangiopancreatography for the evaluation of patients with biliary strictures: differentiation of malignant from benign bile duct strictures. J Magn Reson Imaging. 2007;26(2):304–12.
14. Saluja SS, Sharma R, Pal S, Sahni P, Chattopadhyay TK. Differentiation between benign and malignant hilar obstructions using laboratory and radiological investigations: A prospective study. HPB. 2007;9:373–82.
15. Patel H, Shah A, Khandelwal S, Patel H, Patel M. MR Cholangiopancreatography at 3.0 T. RadioGraphics. 2009;29(6):1689-1706.
16. Katabathina V, Dasyam A, Dasyam N, Hosseinzadeh K. Adult Bile Duct Strictures: Role of MR Imaging and MR Cholangiopancreatography in Characterization. RadioGraphics. 2014;34(3):565-586.
17. Suthar M. Role of MRCP in Differentiation of Benign and Malignant Causes of Biliary Obstruction. JOURNAL OF CLINICAL AND DIAGNOSTIC RESEARCH. 2015.
18. Choi JW, Kim TK, Kim KW, Kim AY, Kim PN, Ha HK, et al. Anatomic variation in intrahepatic bile ducts: An analysis of intraoperative cholangiograms in 300 consecutive donors for living donor liver transplantation. Korean J Radiol 2003;4:85 90
19. Dadhwal U, Kumar V. Benign bile duct strictures. Medical Journal Armed Forces India. 2012;68(3):299-303.
20. Sonavane S, Menias C. Imaging Biliary Strictures—A Pictorial Review. Current Problems in Diagnostic Radiology. 2014;43(1):14-34
21. Galhotra R, Attri A, Ahluwalia A, Saggar K. Obstructive jaundice: Its etiological spectrum and radiological evaluation by magnetic resonance cholangiopancreatography. Medical Journal of Dr DY Patil University. 2016;9(4):443.

22. Upadhyaya V, Upadhyaya DN, Ansari MA, Shukla VK. Comparative assessment of imaging modalities in biliary obstruction. Indian J Radiol Imaging 2006;16:577-82.
23. Obaidi S, Al-Hilli MR, Fadhel AA. The role of ultrasound and magnetic resonance imaging in the diagnosis of obstructive jaundice. Iraqi Postgrad Med J 2007;6:5-17
24. Chaudhary A, Negi SS, Puri SK, Narang P. Comparison of magnetic resonance cholangiography and percutaneous transhepatic cholangiography in the evaluation of bile duct strictures after cholecystectomy. Br J Surg 2002;89(4):433–436.
25. Behar J, Corazziari E, Guelrud M, Hogan W, Sherman S, Toouli J. Functional gallbladder and sphincter of oddi disorders. Gastroenterology 2006;130(5): 1498–1509
26. Shanmugam V, Beattie GC, Yule SR, Reid W, Loudon MA. Is magnetic resonance cholangiopancreatography the new gold standard in biliary imaging? Br J Radiol 2005;78(934):888–893
27. Zidi SH, Prat F, Guen OL, Rondeau Y, Pelletier G. Performance characteristics of magnetic resonance cholangiography in staging of malignant hilar strictures. Gut. 2000;46:103–06
28. Kim MJ, Mitchell DG, Ito K, Outwater EK. Biliary dilatation: differentiation of benign from malignant causes-value of adding conventional MR imaging to MR Cholangiopancreatography. Radiology. 2000;214:173–81
29. Menias CO, Surabhi VR, Prasad SR, Wang HL, Narra VR, Chintapalli KN. Mimics of cholangiocarcinoma: spectrum of disease. RadioGraphics 2008; 28(4):1115–1129.
30. Maccioni F, Martinelli M, Al Ansari N, Kagarmanova A, De Marco V, Zippi M, et al. Magnetic resonance cholangiography: Past, present and future: A review. Eur Rev Med Pharmacol Sci 2010;14:721-5.
31. Regan F, Smith D, Khazan R, Bohlman M, Schultze-Haakh H, Campion J, et al. MR cholangiography in biliary obstruction using half-Fourier acquisition. J Comput Assist Tomogr 1996;20:627-32
32. Magnuson TH, Bender JS, Duncan MD, Ahrendt SA, Harmon JW, Regan F. Utility of magnetic resonance cholangiography in the evaluation of biliary obstruction. J Am Coll Surg 1999;189: 63-71
33. Georgopoulos SK, Schwartz LH, Jarnagin WR, Gerdes H, Breite I, Fong Y, et al. Comparison of magnetic resonance and endoscopic retrograde cholangiopancreatography in malignant pancreaticobiliary obstruction. Arch Surg 1999;134:1002-7.
34. Adamek HE, Albert J, Breer H, Weitz M, Schilling D, Riemann JF. Pancreatic cancer detection with magnetic resonance cholangiopancreatography and endoscopic retrograde cholangiopancreatography: A prospective controlled study. Lancet 2000;356:190-3
35. Bain VG, Abraham N, Jhangri GS, Alexander TW, Henning RC, Hoskinson ME, et al. Prospective study of biliary strictures to determine the predictors of malignancy. Can J Gastroenterol 2000;14:397-402