ORIGINAL RESEARCH PAPER

Volume-8 | Issue-1 | January-2019 | PRINT ISSN No 2277 - 8179

INTERNATIONAL JOURNAL OF SCIENTIFIC RESEARCH

ROLE OF COMPUTED TOMOGRAPHY IN PATIENTS WITH CRANIOCEREBRAL TRAUMA

Radiodiagnosis

Dr. S. Venkateswara Rao Professor & HOD, Department of Radio diagnosis, Alluri Sitarama Raju Academy of Medical Sciences, Eluru, Andhra Pradesh 534005.

Dr.Venutharla Samson* Postgraduate, Department of Radio diagnosis, Alluri Sitarama Raju Academy of Medical Sciences, Eluru, Andhra Pradesh 534005. *Corresponding Author

Dr. B. Venkateswarlu Professor, Department of Radio diagnosis, Alluri Sitarama Raju Academy of Medical Sciences, Eluru, Andhra Pradesh 534005.

ABSTRACT

Trauma is the commonest cause of death in the middle-age group in the present era1. In both urban and rural areas, craniocerebral trauma (CCT) is common and is associated with high morbidity and mortality rates. Traumatic Brain Injury (TBI) is a major public health problem in India. TBI results in deaths, injuries, and disabilities in all age groups but more in young and productive persons and higher in males than females.2

AIMS AND OBJECTIVES

- To evaluate and assess the role of computed tomography in patients with Craniocerebral trauma.
- To study various radiological patterns of head injury.
- To delineate various spectrums of hemorrhages that occur in craniocerebral trauma with aid to CT.
- Age and sex distribution of craniocerebral injuries.
- To localize the injury to the particular intra-cranial compartment.

MATERIALS AND METHODS

Place: This study was carried out from the cases collected from the Department Of Radiodiagnosis, Alluri Sitaram Raju Academy of Medical Sciences, Eluru.

Duration: 18 months between October 2016 and March 2018

Study Design: Prospective study.

Source Of Data: All patients with symptoms and signs suggestive of craniocerebral trauma referred for noncontrast plain CT scan of the head.

Study Population: 200 cases

Technique: Serial CT Sections of the brain were obtained from orbitomeatel line at 5 mm interval in posterior fossa and 10 mm interval thereafter. Thin cuts were taken wherever necessary. Scan time is reduced to up to 1 second in uncooperative patients.

Protocol:

A) Standard Brain (Transverse Scan)

- Patients' position: Supine.
- Gantry angulation: -50 to orbito metal line.
- Start position: External auditory meatus.
- End position: Top of the head.
- Slice thickness: 10mm.

B) Standard Posterior Fossa (Transverse Scan)

- Patient Position: Supine
- Gantry Angulation: Parallel to orbito metal line.
- Start Position: Foramen magnum
- End Position: One slice above petrous bone.
- Slice thickness: 5mm

KEYWORDS

Trauma, Craniocerebral, CT, RTA, SDH

INTRODUCTION

The most common cause of TBI normally reported in our country is road traffic accidents (RTA) accounting for 60%, followed by falls and assaults contributing to 25% and 10% of traumatic brain injuries respectively.[3] In the evaluation of CCT, NECT plays a major role while MRI (including MRS and functional imaging) serves primarily as a problem-solving tool in cases when there is a discordance between clinical state of patient and NECT scan and also in chronic cases with traumatic sequelae in cases with high suspicion of diffuse axonal injury where NECT is equivocal or inconclusive.

PATHOPHYSIOLOGY AND CT FEATURES

The understanding of traumatic brain damage that is being gained from recent research is broadening the perspectives from the traditional focus on mechanical, vascular and metabolic effects to encompass wider, neurobiological issues, drawn from the fields of neurodevelopment, neuroplasticity, neurodegeneration, and neurogenetics. Neurotrauma is a fascinating area of neuroscience research, with promise for the translation of knowledge to improved clinical management and outcome.[4]

SCALP INJURY

When interpreting CT scans for head trauma it is useful to begin by examining the extracranial structures for evidence of scalp injury or radio-opaque foreign bodies. Scalp soft tissue swelling is often the only reliable evidence of the site of impact.[5]

EPIDURAL HEMATOMA

An epidural hematoma is the second most common extra-axial lesion in acute head trauma.[6] These occur in the potential space between the inner table of the skull and the dura mater (Fig No. 2). These two structures are normally tightly adherent at suture lines. The source of bleeding is arterial in the majority of cases. Such bleeding often results in rapid neurological deterioration that requires emergency treatment.

CT Features

Bi-convex localized hyperdense collection. An associated skull fracture can be seen over the region of injury. However depressed fractures are rarely associated with epidural hematomas, which most commonly occur in the temporoparietal region. There may be the presence of air pockets within an epidural hematoma probably due to fracture but may be related to gas exchange across membranes. Mass effect may be seen in case of a large amount of bleed causing brain herniation.

SUBDURAL HEMATOMA

A subdural hematoma is one of the commonest extra-axial lesion seen

in patients with acute craniocerebral trauma.[7] These arise within the subdural space, a potential space between the dura and arachnoid membranes (Fig. No.3). This space continues over the convexity of the brain and extends into the interhemispheric fissure on the ipsilateral side of falx, on both sides of the tentorium and over the cerebellar hemisphere convexity. It is very rarely seen in posterior fossa.[8]

CT findings

In the acute phase, it is crescentic in shape. If the blood clot undergoes liquefaction, the changes in composition are accompanied by changes in its attenuation value on CT. By the end of the first week after the injury, the density of the clot becomes approximately that of the underlying brain (isodense) and more likely represents the subacute stage and it may take 1 to 6 weeks to become isodense. Its diminishing density begins peripherally and progresses towards the center.[8]

INTRACEREBRAL HEMATOMA

These are hemorrhagic collections in the deep brain parenchyma. Sometimes, they are not present immediately after traumas but appear over a period of 24-72 hours following injury. They usually appear in previously hypodense or ischemic areas possibly reflecting reperfusion injury.

The clinical presentation of an intracerebral hematoma depends on the severity of the impact, the size, and rate of increase of hematoma and its site.

CT Findings

Characteristic appearance is of a round or ovoid hyperdense collection of uniform density with surrounding hypodense area suggestive of edema. Depending on its size, in 1-2 weeks the content of the hematoma becomes isodense and eventually, a low-density lesion remains at the site or may result in porencephaly.

CEREBRAL EDEMA

Diffuse cerebral swelling is a common manifestation of head trauma. It may occur either because of an increase in cerebral blood volume or an increase in tissue fluid content. Diffuse cerebral swelling occurs secondary to tissue hypoxia. The pathogenesis is poorly understood but appeared to be due to loss of normal cerebral autoregulation.[9] The cerebellum and the brain stem are usually spared and may appear hyperdense relative to the cerebral hemispheres. Often the falx and cerebral vessels appear dense mimicking acute subarachnoid hemorrhage.

CT Findings

- A generalized mass effect with effacement of sulci, suprasellar and quadrigeminal plate cisterns and compression of the ventricular system.
- Decrease attenuation of the brain parenchyma with loss of grey-white differentiation.
- Effacement of the brain stem cisterns indicates severe mass effect and may herald impending transtentorial herniation.

RESULTS

A total of two hundred in patients, who were clinically diagnosed as head injury were sent for CT scan and were included in the present study.

In the present study, the male population predominates, 160 patients (80.00%), the female population is 40 patients (20.00%) The Male: Female ratio is 4:1.

In the present study, RTA was a prime etiological factor and it showed peak incidence in the 21-30 age group accounting for 48 cases. Fall was the leading etiological factor in the age group of 41-50 (18 Patients) and above 61 (14 patients) age group. The bulk of the patients (120) came with RTA followed by 72 falls and least being (08 patient) assault as the etiology.

In the present study, contusions were noted in 94 patients (51.08%). These contusions were commonly seen in the temporal region 56 (59.57%).

Number of Patients Showing Various Lesions on CT scan

LESIONS	CASES	PERCENTAGE
Contusions	94	51.08
Cerebral Edema	72	39.13
Mass Effect	48	26.08
Subdural Hematoma	50	27.17
Extradural Hematoma	48	26.08
Intracerebral Hematoma	44	23.91
Subarachnoid Hemorrhage	20	10.86
Intraventricular Hemorrhage	16	10.80
Pneumocephalus	12	08.69
Fractures	120	65.21

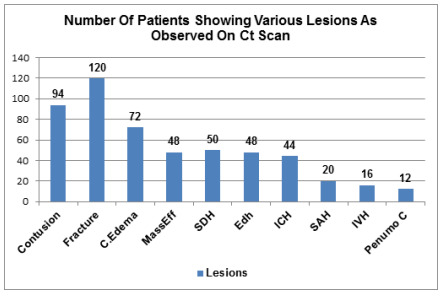

REPRESENTATIVE CASE

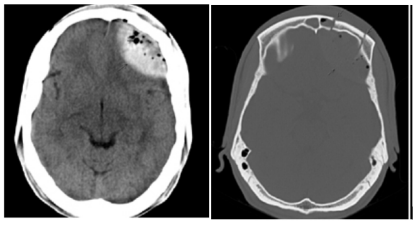

Axial NECT scan image shows EDH in the left frontal region with associated pneumocephalus and comminuted fracture of the left frontal bone

DISCUSSION

Various clinical parameters are used for planning management and predicting the prognosis of a patient with craniocerebral trauma. This is based on neurological dysfunction which is due to structural damage to the brain and this structural damage can be detected by CT scan. It is worthwhile to utilize this modality as the primary modality of choice in acute craniocerebral trauma.

It is universally noted that the craniocerebral trauma is more frequent in the males. Male predominance varies from 81% reported by Kerr et al in England, to as low as 59% in the United States as reported by Kalsbeek and associates.[7] Male predominance was also seen in the present study where Male: Female ratio was 4:1 (Table No. 1).

The study conducted by Zimmerman R. A.(1978) showed 79.00% male incidence as the males were exposed to more of outdoor work and led a more active life.[10]

Head injuries are more frequent in the younger age groups in the United States. The incidence of head injury in 0-20 age groups was 30%, 20-40 years was 60% and above 40 years was 10%.[7] In the present study also the incidence of craniocerebral trauma in the age group of 20-40 was 55%.

According to Igun G O[11] in his study reported vehicular accidents as the major mode of head injury with an incidence of 72% and Masih Saboori et al[12] reported an incidence of 88.2%. Lindell (1994), the incidence of RTA was 20-50%.[13] But in the present study, it was found that the incidence of RTA was 60%. This can be attributed to the reason that with rapid urbanization, there is an increase in the number of vehicles and population with more movement of people.

Contusions are one of the commonly seen lesions after craniocerebral trauma. Dublin reported an incidence of 40%.[14] In the present study, the incidence of contusions was 51%. This high incidence is due to the selection of only moderate to severe injury patients for CT scan, few mild injury patients being under observation by neurologist and neurosurgeons.

In the present study operative interventions like craniotomy or burr hole and evacuation was done in 18 patients (10%).

Subdural hematoma was found to the commonest type of hemorrhage noted accounting for 27.17% in the present study. Incidence reported in other studies were Masih Saboori et al75 (34.7%), Igun GO (60%)[11], Ogunseyinde AO et al77 (28.7%).

Klen and Fettich (1984) in a review of the largest series of acute subdural hematomas called it one of the unsolved problems of neurosurgery.[15]

Zimmerman R (1997) concluded that significant predictors of outcome on CT scan are intracerebral hemorrhage, extradural hematoma, intraventricular hemorrhage, subdural hematoma and presence of subarachnoid hemorrhage. The site of intracerebral hemorrhage, the volume of extradural hematoma, subdural hematoma, midline shift of more than 3 mm, compressed or absent perimesencephalic cisterns.[74] Factors influencing poor outcome are patient age, number, and size of lesions, the rapid rate of subdural hematoma accumulation and delayed surgical evacuation, symptoms of raised intracranial pressure and integrity of brain stem.

CONCLUSION

1. The incidence of craniocerebral trauma was more in the male population.
2. The peak incidence of craniocerebral trauma was found in the age group of 21-30 years.
3. Road traffic accidents were found to be the commonest mode of injury.
4. Linear fractures were found to be the common type of skull fractures.
5. Cases graded as a mild head injury by the Glasgow Coma Scale comprised the bulk of the study.
6. Computed Tomography was found to be more sensitive in detecting basal skull fracture which was not detected on routine plain X-ray skull.
7. Contusions were the most common lesions resulting from craniocerebral trauma.
8. Cerebral edema was the next common intracranial lesion observed.
9. The incidence of subdural hematoma was more as compared to other hemorrhages.
10. Subdural hematoma was the commonest cause of morbidity and mortality in craniocerebral trauma.
11. With the availability of spiral/helical, Multi-Detector CT scanning time has been cut down drastically.

REFERENCES

1. Sosin DM, Sniezek JE, Waxweiler RJ. Trends in death associated with traumatic brain injury, 1979 through 1992. Success and failure. JAMA 1995; 273: 1778–80. doi: 10.1001/jama.1995.03520460060036
2. Pruthi N, Ashok M, Kumar VS, Jhavar K, Sampath S, Devi BI. The magnitude of pedestrian head injuries and fatalities in Bangalore, south India: A retrospective study from an apex neurotrauma center. Indian J Med Res. 2012; 136:1039–43.
3. Gururaj G, Kolluri SV, Chandramouli BA, Subbakrishna DK, Kraus JF. Traumatic Brain Injury. Bangalore: National Institute of Mental Health and Neurosciences; 2005.
4. Gean AD (1994) Imaging of Head Trauma. New York: Lippincott Williamsimage Wilkins.
5. Gurdjian ES, Webster JE, Lissner HR. The mechanisms of a skull fracture. J. Neuro. Surg. 1950; 7: 106-14.
6. Baykaner K, Alp H, Ceviker N, Keskil S, Seckin Z. Observation of 95 patients with extradural hematoma and review of the literature. Surg. Neurol. 1988; 30: 339-41.
7. Kalsbeek WD, McLaurin RL, Harris BSH, Miller JD. The national head and spinal cord injury survey: Major findings. J. of Neuro. Surg. 1980; 53: 519-31.
8. Adams JH, Pathology of nonmissile head injury. Neuro Imaging Clinics N. Am. 1991; 1: 397-410.
9. Czosnyka M, Balesteri M, Steiner L, Smielewski P, Hutchison PJ, Matta B et al. Age intra-cranial pressure, autoregulation and outcome after brain trauma. J. Neuro. Surg. 2005; 102: 450-4.
10. Zimmerman RA, Bilaniuk LT, Genneralli T, Bruce D, Dolinskas C, Uzzell B. Cranial C.T. in the diagnosis and management of acute head trauma. A. J. R. 1978; 131: 27-34.
11. Igun GO. Predictive indices in traumatic intracranial hematomas. East African Medical Journal. 2000 Jan; 77(1): 9-12.
12. Masih Saboori, Jalal Ahmadi, Zahra Farajzadegan. Indications for brain CT scan in patients with minor head injury. Clinical Neurology and Neurosurgery. Volume 109, Issue 5, June 2007, Pages 399-40.
13. Zuccarello M, Pardatscher K, Andrioli GC. Epidural hematomas of the posterior cranial fossa. Neurosurgery. 1981; 8: 434-7.
14. French AN, Limitations and pitfalls of computed tomography in the evaluation of the craniocerebral injury. Surg. Neurol. 1978; 10: 395-401.
15. Klen B, Fetlich M. Factors influencing the outcome in an acute subdural hematoma. Acta. Neurochirugica. 1984; 71: 171-8.