Original Research Paper

Volume : 5 | Issue : 10 | October 2016 • ISSN No 2277 - 8179 | IF : 3.508 | IC Value : 69.48

Role of Computerised Tomography in the Evaluation of Solitary Solid Renal Masses

MEDICAL SCIENCE

KEYWORDS : RCC, Wilms tumour, Angiomyolipoma, CT enhancement of tumours

Sujata Patnaik MD	Additional Professor, Dept. of Radiology, Nizam's Institute of Medical Sciences, Hyderabad-Telangana, * CORRESPONDING AUTHOR
Sarode Ashish Govardhan	DNB, Fellow in Vascular and Interv.Radiology, GS Seth Medical College, Mumbai
Harshavardhan DNB	Nizam's Institute of Medical Sciences, Hyderabad-Telangana
Ramireddy MS	Nizam's Institute of Medical Sciences, Hyderabad-Telangana

ABSTRACT

When a solitary sold renal mass comes for evaluation the first issue is to decide if it is a malignant or a benign lesion. Ultrasonography and the CT scan are the most frequently used modalities for the initial diagnosis. CT imaging, especially with the use of contrast helps in diagnosis with greater accuracy and also helps in staging. In our study of 46 cases most of the masses were malignant with Renal cell carcinoma (RCC) being the most common mass. Contrast attenuation difference of >20HU in plain scan and corticomedullary phase indicated malignancy. CT scan has sensitivity of 75%, specificity of 77.8 % and accuracy of 76.7 % in diagnosis of solid renal masses and can over/ under-stage the local invasion in 6% cases.

INTRODUCTION

Solitary solid renal masses (labelled so, when they contain little or no fluid component and have predominant enhancing soft tissue) can be due to neoplasms, infection, infarction or trauma. RCC is the most common malignant tumor of kidney, accounting for 85 to 90% of adult renal malignancies and 1-2% of all malignancies and frequently presents as a solid solitary renal mass [1]. With increased use of ultrasonography and MDCT, renal masses are being detected more frequently as incidental findings. Differentiation of malignant from benign renal lesions is extremely important, especially when these masses are small. CT is the most widely used imaging modality for evaluation including tumour staging of renal masses. Solid and complex renal masses are mainly neoplastic origin but some inflammatory lesions may have equivocal imaging findings [2].

AIM AND OBJECTIVES

This prospective analysis of all renal solid masses that presented to our department for imaging studies was taken up to define the role of CT in their evaluation including preoperative staging.

MATERIAL AND METHODS

This study was done in Department of Radiology and Imageology of Nizam's Institute of Medical Sciences, Hyderabad. Study period was 2012 to 2013. Total 46 cases were included. Informed consent was obtained before the study. When masses were 2 or more or when present with predominant cystic component or if CT was not done due to any contraindication those cases were excluded from the analysis.

CT scans were performed with 16 slice-MDCT-PHILLIPS BRILLIANCE. Thin section axial images were obtained with and without IV contrast. Contrast enhanced images were obtained in cortico-medullary (40 sec delay) and nephrographic phase (90 sec delay). CT images were analysed in terms of site, size, attenuation, calcification, enhancement of masses in non-contrast phase (NECT), in cortico-medullary (CMP) and nephrographic phases(NP), local extent, lymph node involvement and any distant metastases. Finally, HPE correlation was done wherever it was warranted.

RESULTS

Our study included 46 cases of solid solitary renal masses out of which 40 were malignant lesions and 6 cases were benign (Table-1). The age of presentation varied from 2 years to 86 years. Maximum number were in the age group of 60-80 years. Wilms tumour and rhabdoid tumours were below 10 years. Male and female ratio of 1.7:1.

Table-1: Analysis of the 46 cases included in this study

	Type of tumour	Number
Malignant (N=40)	RCC	30
	WILMS TUMOURS	4
	LYMPHOMAS	2
	METASTASIS	2
	TCC	1
	RHABDOID TUMOUR	1
Benign (n=6)	ANGIOMYOLIPOMA	4
	NEPHRONIA	2

The most common malignant tumour was RCC followed by Wilms tumours. Angiomyolipomas (AML) were the most common benign lesions. Mean attenuation values of malignant mass in NECT, CMP, NP were 37.22 ± 5.3 HU, 96.54 ± 19.7HU and 76.42 ± 18.8 HU respectively (Graph-1). Malignant lesions showed maximum enhancement in CMP phase. AML showed negative attenuation value with minimal enhancement, nephronia had soft tissue density with significant enhancement.

GRAPH-1: CT enhancement of malignant solid masses in various phases

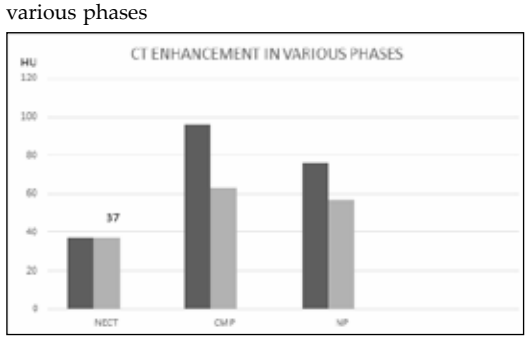

The CT enhancement is in HU in the Y axis

RCC: Of the 30 tumours included in this study, only 5 were <5cms, 8 were between 5-7cms, and rest 17 were >7cms.

Calcification was seen in 10(21%) of RCC. Histopathologically 3 sub-types were diagnosed -Clear Cell type (n=25), Chromophobe cell type (n=4) and papillary cell type (n=1). Mean attenuation of pathologically proven Clear cell carcinoma, papillary cell carcinoma and Chromophobe cell ca in corticomedullary phase were 111.9 ± 25.4 , 84.25 ±13.6 and 78 HU repectively.

TABLE-2: Comparision of CT imaging with pathological diagnosis in detection of local spread

MODALITY	LIMITED TO CAPSULE	PERINEPHRIC SPREAD	ADRENAL	PSOAS	LIVER	RENAL VEIN	IVC
CT IMAGING	20	10	3	1	1	5	3
PATHOLOGY	22	8	3	1	1	5	3

TABLE-3: Comparision of CT imaging with pathological diagnosis with respect to N staging

N STAGE	Path-negative	Path- positive	TOTAL
CT diagnosis negative	14	3	17
CT diagnosis positive	01	12	13

As shown in table-2, spread to distant locations was correlating well with CT or by histopathology. Limitation to capsule was misdiagnosed in 2 cases by CT scan and perinephric spread was over diagnosed in 2 cases. For nodal staging (see table-3) ,of 13 cases that were positive on CT and pathologically it was normal in one case. Of 15 that were positive in HPE, 3 appeared normal on CT. Thus CT correctly detected lymph node status in 76%, overstaged in 13.3% and underdiagnosed in 10%.

DISCUSSION

Any mass is considered to be solid when it contains little or no fluid component and shows predominantly enhancing soft tissue. Renal cell carcinoma (RCC) is the most common solid mass of the kidneys and account for 2% all malignancies and 90 % of primary renal tumours. Other malignant masses are transitional carcinoma (TCC), lymphoma, metastases, Wilms tumour, rhabdoid tumours, benign masses include oncocytoma, angiomyolipoma, inflammatory masses like granuloma, abscess etc. [2].

In our study of 46 cases, the malignant masses constituted the majority(86%). A study of 84 cases by Choi et al in 2012 found 80% of their series were malignant and 20% benign. RCC was the most common malignant lesion and Oncocytoma and AML are benign lesions [3]. This is similar to our observation. Maximum percent of patients in our study were age group of 60 years and above with a male :female ratio of 1.7:1. The incidence of of RCC was maximum in age group of 60-80 yrs with female predominance in a study by Verhoest et al [4]. We had 4 cases of Wilms tumor below 10 yrs similar to study by Lorengan et al [5]. Rhabdoid tumor is extremely rare (0.0091%) and common age of presentation is 3 weeks to 7months [6] as seen in our cases.

Malignant masses (n=40) had attenuation of 37+_5.3 HU on precontrast scan and 96.54 ±19.7HU, 76.42 ± 18.8 in corticomedullary and nephrographic phases respectively . Benign lesions showed values of 36.7HU, 63 HU and 57 HU respectivly in NECT and the 2 phases on contrast CT. The mean attenuation difference between corticomedullary and nephrographic phase was 20.12 for malignant lesion and 6 HU for benign lesion. Keeping a cut off value of 20 HU as significant enhancement to distinguish between malignant neoplasms and benign lesions we achieved a sensitivity of 100%, specificity of 66% and accuracy of 95.6% compared to Zagoria et al who achieved sensitivity of 96.2%, specificity of 100% and accuracy of 97.2% [7].

Most of RCC tumors were more than 7 cms(n=17). It is comparable to the observations done by Turkavatan [8]. Calcifications was observed centrally in 33.33% of the 30 cases (figure-1). Similar findings were reported by by Kim[9]. All cases of RCC were diagnosed preoperatively. Subsequent to HPE, mean attenuation of clear cell, chromophobe ,papillary cell carcinoma were found to be 36 to 38HU in NECT, 111.9 ± 25.4 HU, 84.25 ±13.6HU, 78 HU in corticomedullary phase and 89.5 ±16HU, 63.25 ± 20HU and 53HU in nephrographic phase respectively. Clear cell carcinomas showed more enhancement as compared to other subtypes and it was is most appreciated in corticomedullary phase (Figure-2).

Figure-1: Chromophobe RCC: NECT showing central calcifications and moderate enhancement on contrast scan

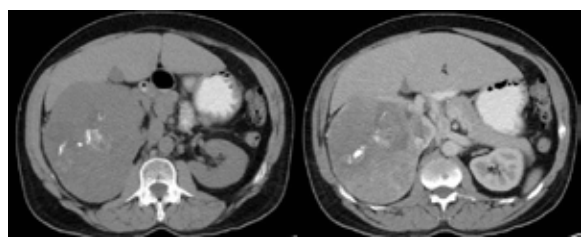

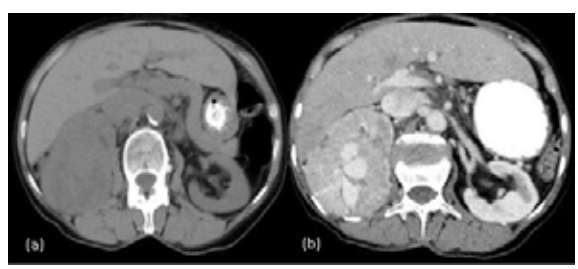

Figure-2: Clear cell variety of RCC of right kidney, NECT, post contrast CMP showing moderate enhancement

CT scan plays a pivotal role in the pre-operative staging of renal tumours. TNM staging is the most accepted staging that is widely practised world over. In local staging, CT overstaged 2 cases accounting for 6% and in the rest it correctly depicted the local advancement(figure-3).Turkvatan et al in their study of 57 RCC ,5 tumors (8.7%) were either over or understaged. Spread of tumour into perinephric fat can be a challenging task. A stranding can be found due to oedema, vascular engorgement or previous inflammation [10]. However, an enhancing nodule in that area is a specific finding suggesting invasion[11].

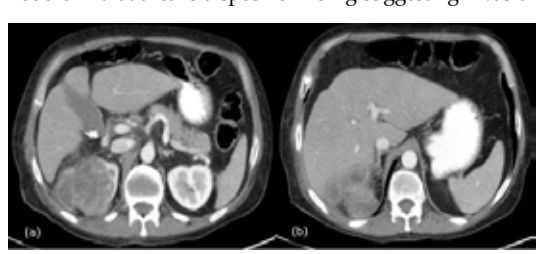

Figure-3: A case OF RCC depicting the extension to perinephric space, to para renal space and into liver

The criteria that > 1cm nodal involvement is diagnosed as significant on spiral CT is widely practised. This criterion has a false- negative rate of 10%[11]. Similarly in our

Volume : 5 | Issue : 10 | October 2016 • ISSN No 2277 - 8179 | IF : 3.508 | IC Value : 69.48

study, for nodal staging ,4 cases were positive on CT and pathologically it was normal .3 were positive in HPE and was appearing normal on CT. Thus CT correctly detected lymph node status in 76%, overstaged in 13.3% and underdiagnosed in 10%. We achieved sensitivity of 75%,specificity of 77.8%,and accuracy of 76.7% which is similar to Turkavatan et al who observed that only 74% of their cases were correctly staged, 19% were over-staged and 7% were understaged . Over staging can be due to presence of reactive nodes larger than 1 cm [8]. Retroperitoneal nodes more than 1 cm are shown below in one of our cases(figure-4).

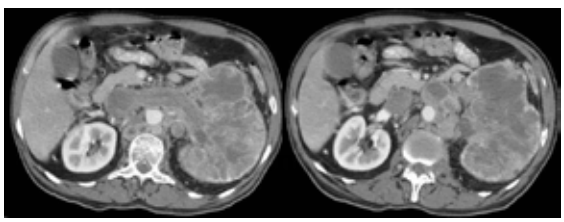

Figure-4: Diffuse heterogenous enhancement of RCC in left kidney with extension to renal vein and IVC. Multiple enlarged nodes in retroperitoneum

Lung ,liver bone,adrenal,brain are the common sites for metastasis. Mediastinal nodes may be involved in 6.3% [12] and epidural sites in 14% [13]. Out of 30 RCC in our study, 5 cases had distant metastases in liver ,lung ,bone,contralateral adrenal, mediastinal nodes and epidural space.

TCC is the most common urothelial tumor and 2nd most common malignant lesion after RCC . Renal pelvis is the most common site and enhancement is slightly less than RCC . The lesion is inseparable from medulla in CMP and NP phases . The tumour is better seen in excretary phase as in our case. Wilms tumor are the most common primary tumors in children of 3 to 4 years of age. We had 4 cases of wilms tumor showing classical features(figure-5). Lymphnode metastases in 2, hepatic in 1 as described in literature. One case had perinephric fluid collection which is unusual. Agrono et al have shown that more than 71% cases of rhabdoid tumors had perinephric fluid collection and this feature may also be seen in children with Wilms, Clear cell sarcoma, mesoblastic nephroma, RCC and undifferentiated sarcoma[14]. Rhabdoid tumors are highly aggressive malignancy of childhood and comprises of 2% of pediatric renal malignancies [15] . It presents as large centrally located heterogenous soft tissue mass involing the renal hilum with indistinct margins closely resembling Wilms tumor as in our only case (figure-6). NHL is more common renal lymphoma than Hodgkins'disease. Lymphoma present as one of the 4 patterns-multiple solid focal masses, single focal mass , perinephric mass or with diffuse infiltrative pattern . We had 2 cases of lymphoma(figure-7).

Figure-5: Wilms tumor of right kidney showing heterogenous enhancement

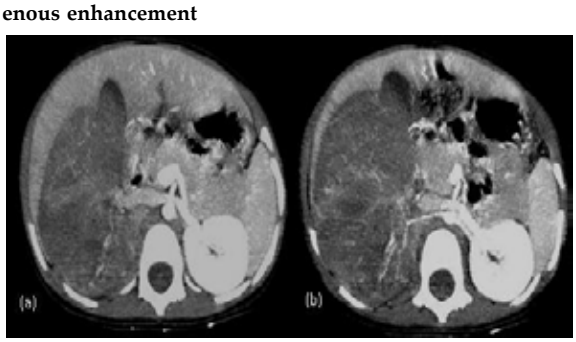

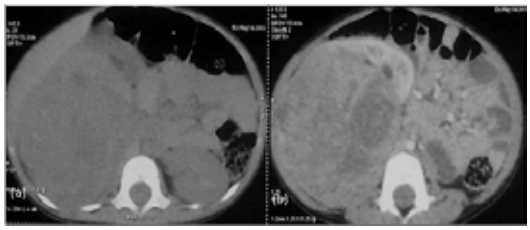

Figure-6: Rhabdoid tumor of right kidney having heterogenous enhancement

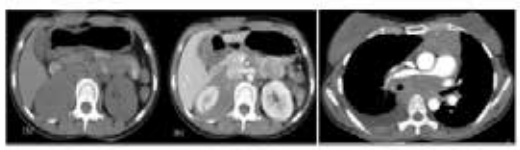

Figure-7: Perinephric minimally enhancing mass with mediastinal adenopathy in a case of lymphoma (NHL)

There were 2 cases of metastases from colonic and testicular primaries (Figures 8 & 9). Metastases accounts for 50-85% of solitary renal masses. Common primaries are bronchogenic ca,ca breast, gastrointestinal tract[16]. The sensitivity for detection of IVC thrombi varies from 64- 95% by CT scan and is as high as 100% by MRI [17].

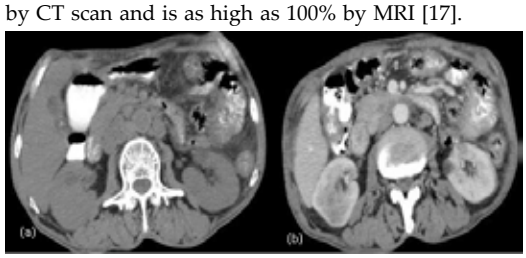

Figure-8: Solid heterogeneously enhancing metastasis to right kidney from colonic carcinoma

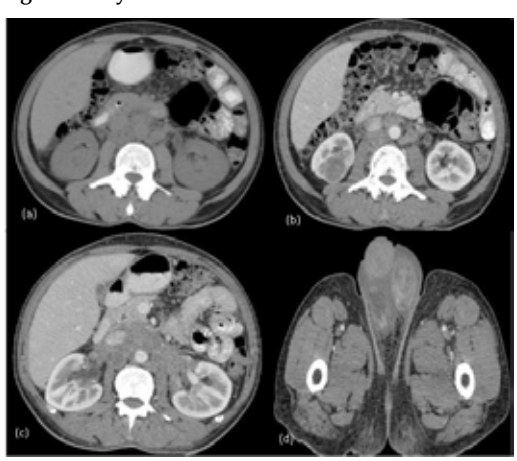

Figure-9: Germ cell tumor of testis with solitary solid enhancing metastasis to kidney and retroperitoneal lymphadenopath

AML are the most common benign mesenchymal tumors composed of variable proportion of angiomatous,lipomatous component. They account for 1% of surgically removed renal tumors . AML are frequent seen in association with Tuberus sclerosis. Classic triphasic renal angiomyolipoma appear as hetrogenous mass with varying propotion of macroscopic fat,intralesional aneurysm,hypervascular soft tissue . All our 4 cases were showing classical angiomyolipoma features (figure-10). The other 2 benign lesions were nephronia(figure 11).Lee at al studied nephronia in 13 cases which appear as focal mass without definite wall ,pathy / inhomogenous enhancement as our cases [18].

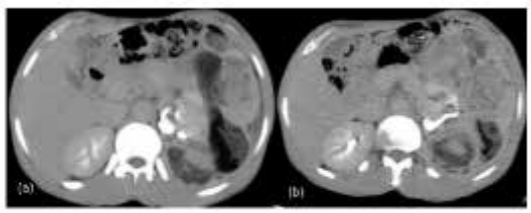

Figure-10: Large AML in right kidney having haemorrhage, fat density and enhancing soft tissue component

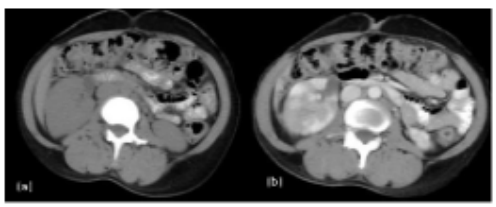

Figure-11: Ill-defined focal solid heterogeneously enhancing mass representing nephronia of right kidney

CONCLUSION:

RCC is the most common solitary solid malignant mass with male predominance and most common age of presentation is more than 60 years. Clear cell sub type is more common than chromophobe or papillary variety. Clear cell cell type shows more enhancement than other sub types . Contrast attenuation difference of >20HU corticomedullary and nephrographic phases indicates malignancy. CT scan has sensitivity of 75%, specificity of 77.8% and accuracy of 76.7% in local staging and can over/under-stage the local invasion in 6% cases.

REFERENCES:

1. Jemal, A., Murray, T., Ward, E., Samuels, A., Tiwari, R.C., Ghafoor, A., Feuer, E.J., Thun, M.J. (2005). Cancer statistics,2005. CA Cancer J Clin 55,10-30
2. Eble, J.N., Togashi, K, Pisani, P. Renal Cell Carcinoma (page 12-14). In Eble, J.N., Sauter, G., Epstein, J.I., Sesterhenn, I.A.(Eds), World Health Organization classification of tumours- Pathology and genetics of Tumours of the Urinary System and Male Genital Organs. (2004) IARC Press Lyon.
3. Choi, S-K., Jeon, S.H., Chang, S-G. (2012). Characterization of Small Renal Masses Less than 4 cm with Quadriphasic Multidetector Helical Computed Tomography: Differentiation of Benign and Malignant Lesions. Korean J Urol 53, 159–64.
4. Verhoest, G., Veillard, D., Guillé, F., Taille, A.D., La Salomon, L., Abbou, C.C., et al (2007). Relationship between age at diagnosis and clinicopathologic features of renal cell carcinoma. Eur Urol 51(5),1298–305.
5. Lonergan, G.J., Martinez-Leon, M.I., Agrons, G.A., Montemarano, H., Suarez. E.S. (1998). Nephrogenic rests, nephroblastomatosis, and associated lesions of the kidney. Radiographics 18, 947–68.
6. Lowe, R.E., Cohen, M.D., (1984). Computed tomographic evaluation of Wilms tumor and neuroblastoma. Radiographics 4(6),915–28.
7. Zagoria, R.J., Gasser, T., Leyendecker, J.R., Bechtold, R.E., Dyer, R.B., (2007). Differentiation of renal neoplasms from high-density cysts: use of attenuation changes between the corticomedullary and nephrographic phases of computed tomography. J Comp Ass Tomogr 31(1),37–41.
8. Türkvatan, A., Akdur, P.O., Altinel, M., Olçer, T., Turhan, N., Cumhur, T., et al (2009). Preoperative staging of renal cell carcinoma with multidetector CT. Diagn Interv Radiol 15(1),22–30
9. Kim, J.K., Kim, T.K., Ahn, H.J., Kim, C.S., Kim, K.R., Cho, K.S., (2002). Differentiation of subtypes of renal cell carcinoma on helical CT scans. Am J Roentgenol 178(6),1499–506
10. Zagoria, R.J., Bechtold, R.E.,Dyer, R.B., (1995). Staging of renal adenocarcinoma: role of various imaging procedures. AJR Am J Roentgenol 164, 363-370]
11. Johnson, C.D.,Dunnick, N.R., Cohan, R.H., Illescas, F.F., (1987). Renal adenocacinoma: CT-staging of 100 tumours. AJR Am J Roentgenol 148, 59-63
12. Fritscher-Ravens, A., Sriram, P.V.J., Topalidis, T., Jaeckle, S., Thonke, F., Soehendra, N., (2000). Endoscopic ultrasonography-guided fine-needle cyto-diagnosis of mediastinal metastases from renal cell cancer. Endoscopy. George Thieme Verlag Stuttgart· New York 32(07),531–5.
13. Sundaresan, N., Galicich, J.H., Lane, J.M., Bains, M.S., McCormack, P., (1985). Treatment of neoplastic epidural cord compression by vertebral body resection and stabilization. J. Neurosurg 63(5),676–84
14. Agrons, G.A., Kingsman, K.D., Wagner, B.J., Sotelo-Avila, C., (1997). Rhabdoid tumor of the kidney in children: a comparative study of 21 cases. AJR Am J Roentgenol 168(2), 447–51
15. Charles, A.K., Vujanic, G.M., Berry, P.J., (1998). Renal tumours of childhood. Histopathology 32(4),293–309
16. Bracken, R.B., Chica, G., Johnson De., Luna, M., (1979). Secondary renal neoplasms: an autopsy study. South Med J 72(7), 806–7
17. Semelka, R.C., Shoenut, J.P., Magro, C.M., Kroeker, M.A.,MacMahan, R., Greenberg, H.M.,(1993). Renal cancer staging : comparision of contrast-enhanced CT and gadolium-enhanced fat-supressed spin-echo and gradient echo MR imaging 3, 597-602
18. Lee, J.K., McClennan, B.L., Melson, G.L., Stanley, R.J., (1980). Acute focal bacterial nephritis: emphasis on gray scale sonography and computed tomography. Am J Roentgenol 135(1),87–92