ORIGINAL RESEARCH PAPER

Volume-7 | Issue-11 | November-2018 | PRINT ISSN No 2277 - 8179

INTERNATIONAL JOURNAL OF SCIENTIFIC RESEARCH

# ROLE OF DOPPLER IN THYROID NODULES

Endocrinology

**Sudhakar R. Pendyala** Department of Endocrinology, Yashoda Hospital, Secunderabad, Telangana, India.

**Kishore Kharche*** Department of Endocrinology, Yashoda Hospital, Secunderabad, Telangana, India. *Corresponding Author

**Amith Reddy Seri** Medical Student, Osmania Medical College, Hyderabad, Telangana, India

## ABSTRACT

**Aim:** To evaluate the role of thyroid Doppler in screening of thyroid nodules for the risk of malignancy.

**Methodology:** A descriptive observational study conducted in Yashoda Hospital, Secunderabad, Telangana, India from May 2014 –Sept 2015 for screening thyroid nodules for the risk of malignancy. Patients were examined using B mode ultrasound, power Doppler and pulsed Doppler. Fine needle aspiration biopsy was performed for nodules ≥ 10 mm. Thyroid cytopathology was reported using the Bethesda system.

**Results:** 247 subjects were screened and 134 subjects were considered for final analysis (25 males and 109 females). For Benign tumors, mean age was 45.29 ± 14.64 years and for Malignant tumors mean age was 35.50 ± 15.74 years. The mean anteroposterior diameter for benign nodules was 19.31 ± 4.93 mm and for malignant nodules was 25.11 ± 5.89 mm. The incidence of malignancy in this study was 18/134 (13.43 %). Among them 66.66% were papillary carcinoma, 27.77% follicular carcinoma (histopathology results), 5.55% anaplastic carcinoma. 8/18 (44.44 %) malignant nodules were seen in multinodular disease. Majority of the nodules were hypoechoic (37.31%) or mixed (41.79%). Micro-calcifications were seen in 13 of 134 (9.7%) nodules among them 12 (92.30%) were malignant. This study demonstrated that the risk of malignancy increases as intra-nodular blood flow increases.Furthermore, for resistive index (RI) of 0.69, the sensitivity to detect malignancy was 72.22 % and specificity of 93.10%. Malignant nodules had higher RI than benign nodules.

**Conclusion -** The B mode ultrasound features including Hypoechogenicity, Microcalcifications and Antero-posterior diameter versus transverse diameter act as a guide to select nodules potentially requiring surgery. Inclusion of doppler in routine ultrasound imaging gives extra information on nature of thyroid nodule. Ultrasound is imaging of choice for thyroid nodules.

## KEYWORDS

### AIMS AND OBJECTIVES

**Aim of the study:-**

To evaluate the role of thyroid Doppler in screening of thyroid nodules for risk of malignancy.

**Objectives of the study:-**

**Primary Objectives**

a) To assess sensitivity and specificity of Doppler study in diagnosing malignant thyroid nodules.
b) To assess the relationship between the findings of B mode ultrasound and Doppler studies with fine needle aspiration cytology or histopathology.

**Secondary objectives**

a) To study Doppler patterns in thyroid nodules.
b) To study ultrasound findings in thyroid nodules.
c) To calculate sensitivity, specificity, positive predictive value and negative predictive value of B mode ultrasound parameters to screen thyroid nodules for malignancy.

### MATERIALS AND METHODS

**Study place: -** Endocrine Outpatient department at Yashoda hospital Secunderabad, Telangana,

Yashoda Hospital is a tertiary care center at Secunderabad, Telangana, India, catering the urban and sub-urban population in and around the Secunderabad city. This hospital is the NABH accredited and has adequate workload in endocrinology unit.

The study was conducted in this hospital because of the

1. Adequate availability of patient population,
2. Good laboratory support to carry out most of the specific investigations,
3. NABL certified laboratory.
4. Experienced team in radiology, thyroid surgery and pathology is available.

**Study population:-**

a. Any number of patient in OPD fitting in inclusion criteria during study duration from May 2014 to Sept. 2015
b. Patients of any age.
c. Both males and females.
d. Both urban and rural population.

**STUDY DESIGN: -** Descriptive, observational study

**Sample size calculation:-**

$$n = \frac{Z_{\frac{\alpha}{2}}^2 \hat{P}(1-\hat{P})}{d^2}$$

Where= $\hat{P}$ pre-determined value of sensitivity from previous studies (92.30%)

Z∞= Standard normal Variate
d = Standard error of estimate

$$n = \frac{1.96^2 * 0.923(1-0.923)}{0.052}$$

N= 3.84 * 0.923 * 0.077/0.0025
N= 0.273/0.0025 = 109

**Sample Size= 109**

**Number of patient examined: -** 134

**Time Frame:** May 2014 to Sept 2015

**INCLUSION CRITERIA:-**

- Goiter patients with the greatest nodule diameter ≥10 mm

**EXCLUSION CRITERIA:-**

- Patients who underwent FNAB before Doppler
- Thyrotoxicosis
- Patients with diffuse goiter (No thyroid nodule)
- Purely cystic nodules
- Patients with non-diagnostic cytology / cytology of undetermined significance from FNAB

**Data collection:-**
After ethical committee approval, data collection was started according to proforma enclosed in annexures. During study period 247 patients visited endocrinology out- patient department with complaints of thyroid enlargement. Written consent was taken for entry in study. Symptoms and coexisting diseases of the patients were recorded. They underwent complete physical examination and thyroid function tests. 31 patients were having thyrotoxicosis, and 11 patients had FNAB before coming to us, they were excluded from further study. 205 patients were evaluated with B mode ultrasound. Among them 18 patients had diffuse goiter, 26 patients had purely cystic nodule, and 8 patients had nodule <10 mm size. These patients

were excluded from further study analysis. 153 patients underwent FNAB among them 19 reports were non diagnostic and they were excluded. So total 134 patients selected at last for final analysis.

**Flow chart of study:-**

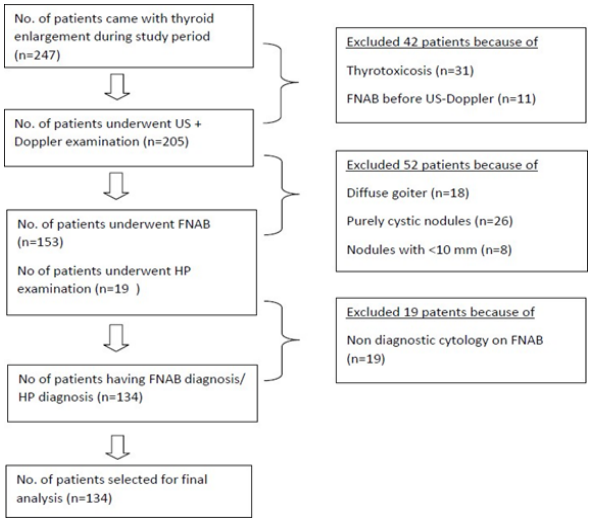


**Methodology**
**ode Ultrasonography**
After taking verbal consent from the patient, US-doppler examination was done. Patient's examined in supine position, neck was extended. Small pillow was kept below shoulders. Number of nodules were noted (solitary / multinodular goiter), their dimensions noted. Each thyroid nodule was observed in both transverse and longitudinal planes. Echogenicity was compared to strap muscles. It was classified as hypoechoic, isoechoic, anechoic and hyperechoic, mixed.

Any presence of calcifications noted. Calcification size less than or equal to 2 mm was labeled as micro-calcification and size more than 2 mm with posterior shadowing labeled as macro- calcification. Nodules containing both type of calcification were noted as mixed.

Peripheral halo if present measurements were taken. Nodules with irregular / micro lobulated margins were considered under absent halo group. Halo with thickness 2 mm or less classified as thin halo and with more than 2 mm labeled as thick halo.

If any cystic nodule with some solid component, same US criteria screening done on solid component. Purely cystic nodules were excluded. In multinodular goiter, nodule with suspicious US findings was subjected to Doppler examination. Only one nodule was taken for study analysis. Suspicious ultrasonography findings were micro-calcifications, hypoechogenicity, absent halo and a taller-than-wide shape (being greater in the anteroposterior dimension than in the transverse dimension)

**Power Doppler**
Power Doppler US was used to assess nodule vascularity. All Doppler studies were be performed by same radiologist who is experienced in thyroid Doppler. All Doppler scans were performed with PHILIPS IU-22, linear transducer-10 MHz. The amplitude gain was individually established in each study. The amplitude gain was raised until random color noise appeared, then slightly lowered to situate it at level immediately under point of appearance of random color noise.

Power Doppler analysis of blood flow to the nodules was classified according to vascular patterns

1) Absence of signal blood flow;
2) Exclusively peri nodular blood flow;
3) Perinodular blood flow > central blood flow;
4) Marked central blood flow > perinodular blood flow;
5) Exclusively central blood flow.

**Pulsed Doppler**
In addition to the qualitative analysis (Power Doppler), arterial blood flow to nodules was quantified via spectral analysis. The same equipment settings used for the qualitative analyses were applied, adding a sample volume of 2 mm.

The duplex parameter, resistance index (RI) obtained. The index was calculated by standard software of our equipment from central and peripheral arteries. It is based on the formula:

RI = PSV – MDV / PSV.

(PSV- peak systolic velocity, MDV= mid diastolic velocity)

The peripheral and central nodule artery samples were selected by mapping the brightest on color Doppler ones. When both peripheral and central blood flow were found, we selected the 1 peripheral and 2 central arteries with the highest indices. If we did not find a suitable second central artery, we chose a second peripheral artery as the third vessel. Presumptive diagnosis of benign or malignant was done before going to FNAB.

**Ultrasound-guided Fine-needle Aspiration Biopsy (FNAB)**
Under aseptic condition, fine needle aspiration biopsy was performed with US guidance for nodules sized ≥10 mm after Doppler study. We used 23 G needle with 10 ml syringe, made 2- 3 passes per nodule, sample was taken from area of vascularity in color doppler or from solid component with negative pressure aspiration. Pressure normalized before needle removed, then biopsy site compressed for hemostasis. Cytological material was smeared on slides immediately after aspiration, slides were air dried and fixed. Staining was done with Papanicolaou, May- Grunwald-Giemsa stain and hematoxylin-eosin (H & E) stain.

All slides were interpreted by an experienced cyto-pathologist who was blinded to the US findings. Slides with less than six thyroid follicular cell groups were stated as insufficient material and FNAB was repeated. The reporting of cytology was done according to "The Bethesda System for Reporting Thyroid Cytopathology" as follows.[18].

**I. Nondiagnostic or Unsatisfactory**
Cyst fluid only
Virtually acellular specimen
Other (obscuring blood, clotting artifact, etc)

**II. Benign**
Consistent with a benign follicular nodule (includes adenomatoid nodule, colloid nodule, etc)
Consistent with lymphocytic (Hashimoto) thyroiditis in the proper clinical context Consistent with granulomatous (subacute) thyroiditis
Other

**III. Atypia of Undetermined Significance or Follicular Lesion of Undetermined Significance**
**IV. Follicular Neoplasm or Suspicious for a Follicular Neoplasm**

Specify if Hürthle cell (oncocytic) type

**V. Suspicious for Malignancy**
Suspicious for papillary carcinoma
Suspicious for medullary carcinoma
Suspicious for metastatic carcinoma
Suspicious for lymphoma
Other

**VI. Malignant**
Papillary thyroid carcinoma
Poorly differentiated carcinoma
Medullary thyroid carcinoma

Undifferentiated (anaplastic) carcinoma
Squamous cell carcinoma
Carcinoma with mixed features (specify)
Metastatic carcinoma
Non-Hodgkin lymphoma

Patients with follicular, suspicious or malignant cytology were advised for surgery depending on severity of cytology. Nodules with follicular cytology or suspicious cytology the final diagnosis was done from histopathology report and considered for evaluation.

Other than these, wherever histopathology available, that result was considered. The final pathological diagnosis for each nodule was made by reports of US-guided FNAB or surgical pathological examination (if available) to categorize all nodules as benign or malignant and accordingly sensitivity and specificity of Doppler ultrasound to screen malignant nodules was calculated.

## STATISTICALANALYSIS

The relationship between qualitative variables and the biopsy result was assessed using the chi-square test. Values of P <0.05 were considered significant. Single factor analysis of variance was used to evaluate the relationship between continuous variable and the cytological findings. For parameters with P < 0.05, an adjusted model of multiple logistic regression was used.

Sensitivity was calculated from formula = True Positive / (True Positive + False Negative) Specificity was calculated by formula = True Negative / (True Negative + False Positive) Positive predictive value was calculated as = True Positive / (True Positive + False Positive) Negative predictive value was calculated as = True Negative / (True Negative + False Negative)

## RESULTS

Total 247 patients were screened in the study during study period. Of these 31 (12.55%) patients were having thyrotoxicosis, and 11 (4.45%) patients had FNAB before coming to us.

On B mode ultrasound, 18 (7.28%) patients had diffuse goiter, 26 (10.52%) patients had purely cystic nodule, and 8 (3.23%) patients had nodule with <10 mm size. These patients were excluded from further study analysis. Total 153 patients underwent FNAB, among them 19 had non diagnostic cytology (12.41%). Total 134 patients were considered for study analysis.

**Graph 1 -Age wise distribution of FNAB diagnosis**

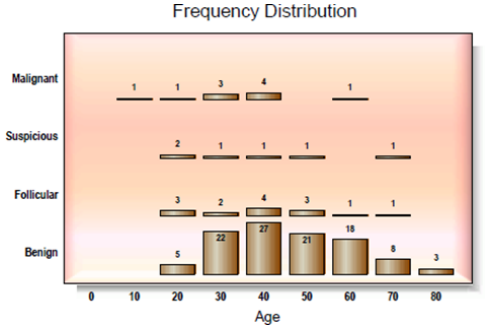


Present study included patients of 8 years to 79 years age. Thyroid nodules were common in middle age, less common in extremes of ages.

**Graph 2 - Age wise frequency distribution of benign / malignant nodules**

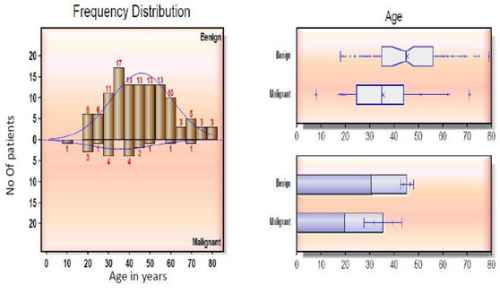


For benign tumors, mean age was 45.29 ± 14.64 years and for malignant tumors mean age was

35.50 ± 15.74 years, for whole study population mean age was 43.97 ± 3.95 year. Malignancy was more common in younger age group. (P=0.01)

**Graph 3 - Gender wise frequency distribution of FNAB diagnosis**

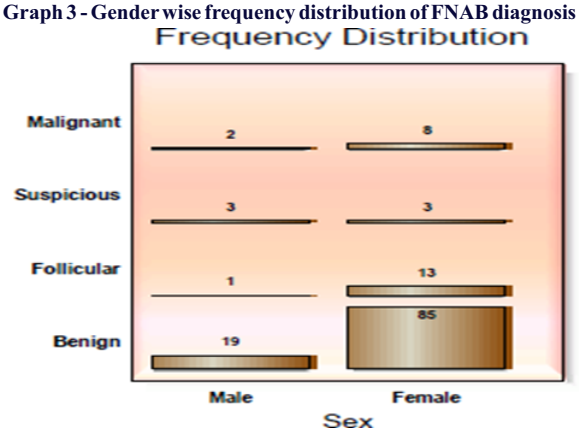


In study population there were 25 (18.65%) males, and 109 (81.34%) females. Thyroid nodules were common in females.

Among males, 19 (76%) had benign cytology, 1 (4%) had follicular cytology, 3 (12%) had suspicious cytology and 2 (8%) had malignant cytology.

Among females, 85 (77.98%) had benign cytology, 13(11.92%) had follicular cytology, 3 (2.75%) has suspicious cytology and 8 (7.33%) had malignant cytology.

**Graph 4 - Gender wise frequency distribution of benign / malignant nodules.**

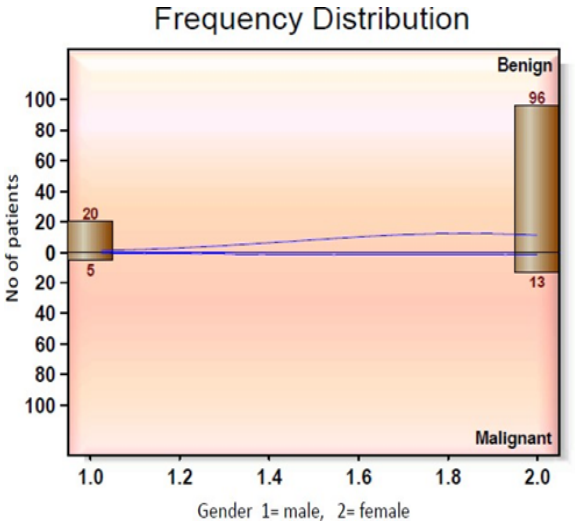


Among total 18 malignant nodules 5 (27.77%) were detected in males and 13 (72.22%) in females,

and among 116 benign nodules 96 (82.75%) were present in females and 20 (17.24%) in males.

**TABLE 2 -Association of gender with benign / malignant nature of thyroid nodule**

| | Benign | Malignant | Total | |
|---|---|---|---|---|
| **Female** | 96 | 13 | 109 | $X^2$=1.14 |
| **Male** | 20 | 5 | 25 | P=0.2871 |
| **Total** | 116 | 18 | 134 | |

So though numerically females have higher incidence of thyroid nodules, as such gender doses not have any association with benign or malignant nature of nodule. (P=0.2871)

**Graph 5- Distribution of nos. of nodules and their benign / malignant nature**

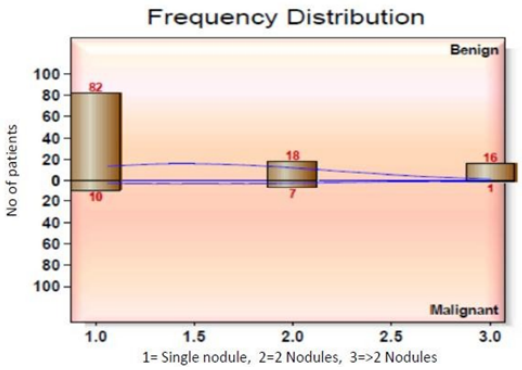


Total 92 (68.65%) patients had solitary thyroid nodule. 25 had 2 nodules (18.65%), 17 (12.68 %) had >2 nodule disease. 10/92 (10.86) solitary nodules, 8/42 (19.04%) multinodular goiter patients had malignant cytology. There was no statistically significant correlation between solitary or multinodular disease. (p=0.19)

**TABLE 3 - Association of No. of Nodules with their benign and malignant nature.**

| | Benign | Malignant | Total | |
|---|---|---|---|---|
| **Solitary nodule** | 82 | 10 | 92 | $X^2$=1.658 |
| **Multiple nodule** | 34 | 8 | 42 | P=0.19 |
| **Total** | 116 | 18 | 134 | |

So number of nodules doesn't have significance in malignancy (p=0.19)

**Graph 6 - Antero-posterior diameter and benign / malignant nature of nodule**

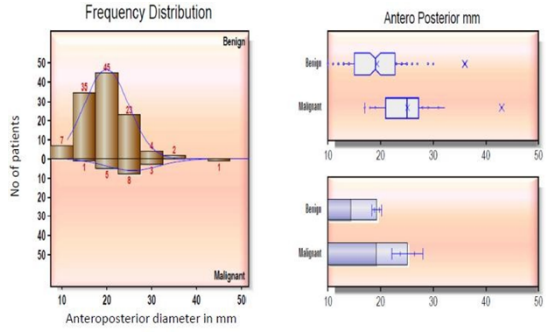


The mean anteroposterior diameter for benign nodules was 19.31 ± 4.93 mm and for malignant nodules was 25.11 ± 5.89 mm. Overall malignant nodules had more anteroposterior diameter (P- 0.001)

**Graph 7- Transverse diameter and benign / malignant nature of nodule**

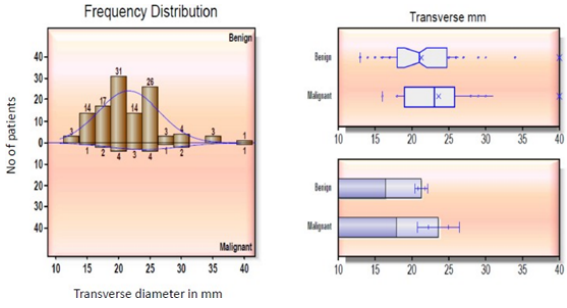


The mean transverse diameter for benign nodules was 21.28 ± 4.84 mm and for malignant nodules mean transverse diameter was 23.61 ± 5.71 mm.

Though malignant nodules were wider than benign nodules there was no statistically significant relationship between transverse diameter and malignancy (p= 0.06)

**Graph 8 -Vertical diameter and benign / malignant nature of nodule**

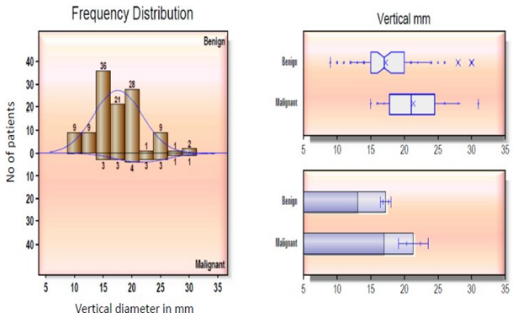


Benign nodules had mean vertical diameter 17.24 ± 4.19 mm and for malignant nodules had mean vertical diameter was 21.33 ± 4.4 mm. Malignant nodules had more vertical diameter compared to benign nodules ( P=0.0002)

**Graph 9 -AP/Transverse diameter ratio and benign / malignant nature of nodule**

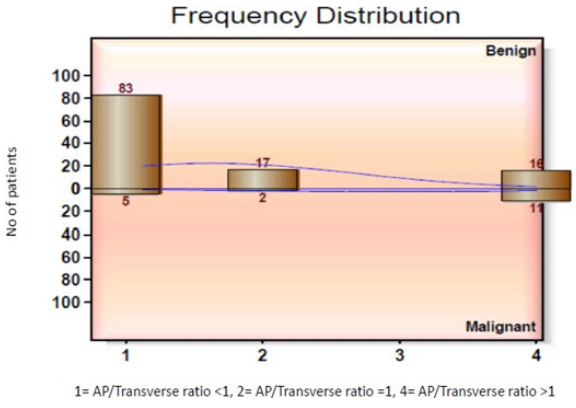


88 (65.67%) nodules had AP/Transverse ratio < 1. Among them 5 (5.68%) were malignant.

19 (14.17%) nodules had AP/Transverse ratio = 1. Among them 2 (10.52%) were malignant.

27 (20.14%) nodules had AP/Transverse ratio > 1. Among them 11 (40.74%) were malignant.

**TABLE 4 - Association of AP/Transverse ratio with benign / malignant nature of nodule**

| AP/Trans diameter ratio | Benign | Malignant | Total | |
|---|---|---|---|---|
| **1** | 17 | 2 | 19 | $X^2$=22 |
| **<1** | 83 | 5 | 88 | |
| **>1** | 16 | 11 | 27 | P=0.00001671 |
| **Total** | 116 | 18 | 134 | |

So AP/Transverse diameter ratio >1 is suggestive of risk of malignancy.

**Graph 10 - Echogenicity and benign / malignant nature of nodule**

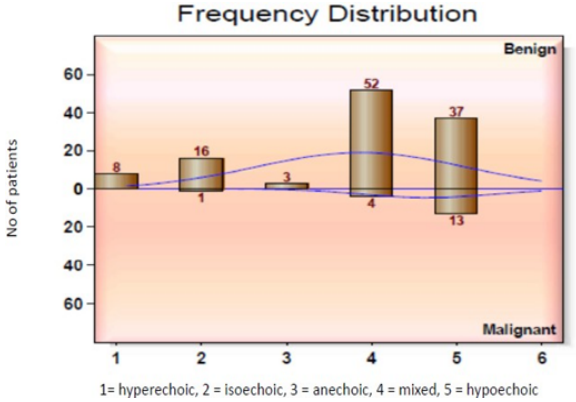

Among all nodules, 8 (5.97 %) were hyperechoic, 17 (12.68%) were isoechoic, 3 (2.23%) were anechoic, 56 (41.79%) were mixed, and 50 (37.31%) were hypoechoic.

13 of 18 (72.22 %) malignant nodules were hypo echoic (p-0.008) and 37 of 116 benign nodules were hypoechoic (31.89%). Mixed echogenicity was the most common pattern, seen in 41.79% nodules, among them 7.11 % were malignant. Hyperechoic, isoechoic, anechoic nodules were predominantly benign.

**TABLE 5 - Association of Hypoechogenicity with benign / malignant nature of nodule**

| Echogenicity | Benign | Malignant | Total | |
|---|---|---|---|---|
| Hypoechogenicity | 37 | 13 | 50 | $X^2$= 10.83 P=0.0009 |
| Others | 79 | 5 | 84 | |
| Total | 116 | 18 | 134 | |

Association of hypoechogenicity and malignancy risk is statistically significant.(P = 0.0009)

**Graph 11 - Peripheral Halo and benign / malignant nature of nodule**

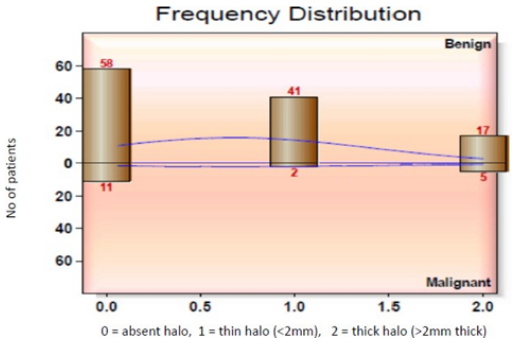


Peripheral halo was present in 65/134 (48.50 %) nodules. Absent halo was seen in 11/18 (61.11%) malignant nodules, and in 58/116 (50 %) of benign nodules. Thin halo was present in 2/18 (11.11%) of malignant nodules and in 41/116 (35.34%) benign nodules. Thick halo was seen in 5/18 (27.77%) malignant nodules & in 17/116 (14.65%) benign nodules. But this finding was not statistically significant (P=0.088).

**TABLE 6 - Association between peripheral halo and benign / malignant nature of nodule**

| P. Halo | Benign | Malignant | Total | |
|---|---|---|---|---|
| Thin Halo | 41 | 2 | 43 | $X^2$=4.86 P=0.08805 |
| Thick Halo | 17 | 5 | 22 | |
| No Halo | 58 | 11 | 69 | |
| Total | 116 | 18 | 134 | |

Although the percentage of absent halo is more in malignant nodules (61.11%) than in benign nodules (50%), the difference was not statistically significant. (P =0.08805).

**Graph 12- Calcifications and benign / malignant nature of nodule**

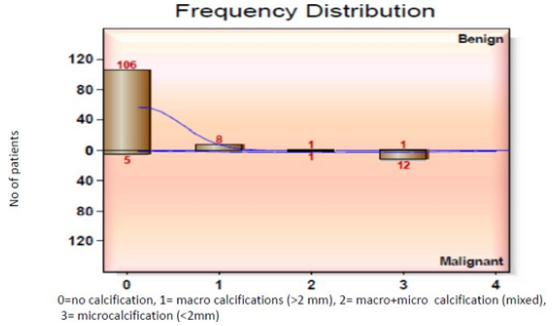


Calcifications were present in 23 (17.16%) nodules, absent in 111 (82.83%) nodules.

Mixed pattern was seen in 2 nodules. 1 of them was benign and other was malignant. Macro calcifications were found in 8 (5.97%) nodules, all of them were benign. 5/111 (4.50%) in absent calcification group were malignant. 13 had micro calcifications among them 12 (92.30%) had malignant cytology.

**TABLE 7- Association between microcalcifications and benign / malignant nature of nodule**

| Calcification | Benign | Malignant | Total | |
|---|---|---|---|---|
| Microcalcification | 1 | 12 | 50 | $X^2$= 77.26 |
| No calcification | 106 | 5 | 84 | |
| Others | 9 | 1 | 10 | P=0.0000001 |
| Total | 116 | 18 | 134 | |

The correlation between presence of microcalcification and malignancy was statistically significant (p=0.00)

**Graph 13- Receiver operating curve for calcifications**

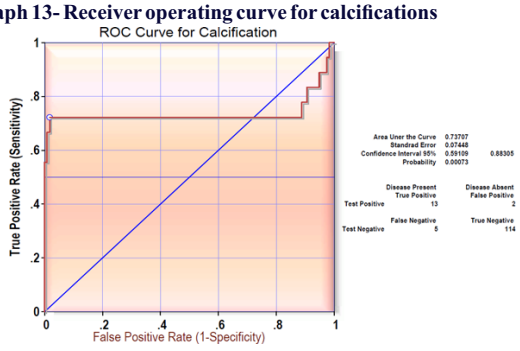


The sensitivity of microcalcification for malignancy was 72.22% and specificity was 98.3%, PPV

=86.66%, NPV =95.79%.

**Graph 14 - Frequency distribution of Vascularity pattern and benign / malignant nature of nodule**

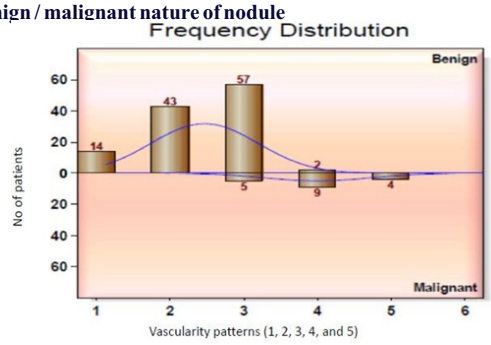


Following percentage of vascular patterns were found, pattern 1→14 (10.44%), pattern 2 → 43 (32.08%), pattern 3 →62 (46.26%), pattern 4→ 11 (8.20%), pattern 5→ 4 (2.98%)

All nodules with pattern 1 &2 were benign. In pattern 3, 8.06% were malignant. In pattern 4, 81.81% were malignant and In pattern 5 all were malignant. So as internal vascularity increased the risk of malignancy increased. Statistical analysis revealed significant correlation between pattern 4 & 5 with malignancy (P=0.0001).

**TABLE 8– Association of vascular pattern and benign / malignant nature of nodule**

| Vascular pattern | Benign | Malignant | Total | |
|---|---|---|---|---|
| ≤ 3 | 114 | 5 | 119 | $X^2$=77.9 |
| >3 | 2 | 13 | 15 | P=<0.0001 |
| Total | 116 | 18 | 134 | |

Vascularity >3 suggests risk of malignancy.

**Graph 15 - ROC for vascular pattern**

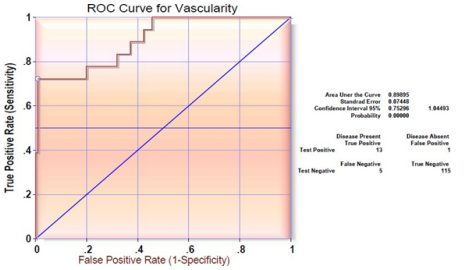

The sensitivity for vascular pattern 4 was 72.22%, specificity 99.13%, PPV 92.85%, NPV 95.83%.

**Graph 16 - Frequency distribution for resistive index**

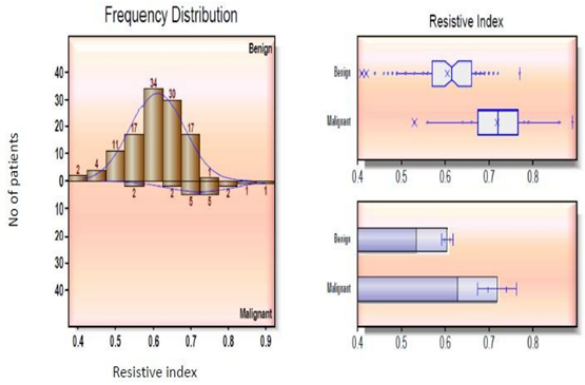


**The mean RI for benign nodules was 60.49% ± 0.07 and for malignant nodules it was 0.71 ± 0.08 (P=0.00)**

**Graph 17 - Receiver operating curve for RI**

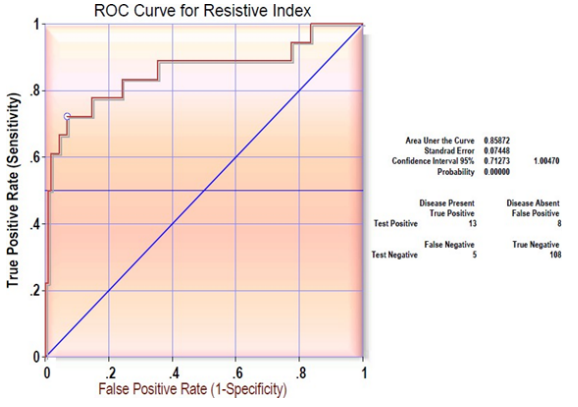


For resistive index of 0.69 the sensitivity to detect malignancy was 72.22 % and specificity of 93.10%. As RI goes above 0.69 sensitivity decreases and specificity increases.

**Factors predicting risk of malignancy.**

**TABLE 9- Distribution of US and color Doppler sonography findings in malignant and benign thyroid nodules and related sensitivity and specificity values of each finding for malignant nodule**

| | Malignant (n=18) | Benign (n=116) | Sensitivity | Specificity |
|---|---|---|---|---|
| **AP>Transverse** | 11 | 16 | 11/18=61.11% | (116-16)/116 = 86.20% |
| **Microcalcifications** | 12 | 1 | 12/18=66.66% | (116-1)/116 = 99.13% |
| **Hypoechogenicity** | 13 | 37 | 13/18=72.22% | (116-37)/116 = 68.10% |
| **Vas. pattern >3** | 13 | 2 | 13/18=72.22% | (116-2)/116 = 98.22% |

The vascular pattern, RI, AP>transverse diameter, echogenicity were all identified as significant predictors of nodules with malignancy.

The nodules having vascular pattern >3 i.e. predominantly intranodular vascular pattern indicate 148 (OR =148, CI 95%; 24.93; 752.30) times increased risk of malignancy.

The nodules with other vascularization patterns demonstrated a substantial risk for malignancy when the RI >0.69.

Logistic regression analysis of these 2 factors revealed the sensitivity and specificity of the model as 96.61% and 87.50%, respectively. PPV was 98.27%, NPV was 77.77% (Table 10).

**TABLE 10- logistic regression of vascular pattern >3 and RI with benign / malignant nature of nodule**

| | Benign | Malignant | Correct class% |
|---|---|---|---|
| **Predicted value benign** | 114 | 2 | 98.27 |
| **Predicted value malignant** | 4 | 14 | 77.77 |
| | 134 (Total) | 128(correctly classified) | 95.52 |

The risk of finding malignant cytology was 5.5-fold higher for hypoechoic when compared with nonhypoechoic nodules; whereas for microcalcifications it was 230 fold and for AP diameter > transverse diameter 9.82 fold. (Table- 11)

**TABLE11- ODDs ratio of B mode ultrasound parameters**

| Parameter | ODDS Ratio | CI 95% |
|---|---|---|
| **Hypoechogenicity vs other echogenicity** | 5.55 | 2.22 – 15.88 |
| **AP>Transverse diameter** | 9.82 | 2.94 – 34.30 |
| **Microcalcifications vs other type of calcifications** | 230 | 28 – 1566.85 |

The Odds ratio for Hypoechogenicity, AP > Transverse diameter, microcalcifications was 5.55, 9.82, 230 respectively.

**TABLE 12 - Logistic regression of B mode parameters**

| Prediction | Benign | Malignant | Correct class % |
|---|---|---|---|
| **Benign** | 114 | 2 | 98.27 |
| **Malignant** | 6 | 12 | 66.66 |
| | Total -134 | Correctly classified 126 | 94.029 |

The sensitivity and specificity of the model was 95 % and 85.71%, respectively, PPV was 98.27% and NPV was 66.66%.

Thus, nodules with AP> Transverse diameter, hypoechogenicity, a mainly central or a central vascular pattern (pattern 4 and 5), and/or increased RI were at greater risk for malignant cytology.

## DISCUSSION

In present days because of easy availability of high resolution ultrasonography, many of the asymptomatic thyroid nodules are picked causing much diagnostic dilemmas. Many studies have shown that the incidence of malignancy in thyroid incidentalomas is same as palpable nodules. [88]

The problem with ultrasonography is that though it is very sensitive for detecting thyroid nodules, many times it cannot characterize the nodule for malignancy risk. So for practical purpose FNAB has become the default preoperative investigation for characterization of thyroid nodules. FNAB is minimally invasive, cause little pain. Despite this, FNAB has several drawbacks like getting insufficient material, non-diagnostic results, cannot characterize follicular lesions etc. This can be seen in 2% to 28% of samples.[9] In the present study 12.41 % cytology reports were non diagnostic.

The expertise for thyroid cytology is not available everywhere. Moreover most of the thyroid nodule patients are evaluated on OPD basis, so patient has to wait for next day for the report, if FNAB is non diagnostic, it is again agony for patient and for treating doctor. Moon et al has shown that the risk of malignancy in non-diagnostic cytology is 7.3% when confirmed by histopathology. [90]

Thyroid nodule is a condition with very high prevalence, prescribing FNAB to each and every patient with thyroid nodule is neither necessary neither cost effective. Thus we need a newmethod, which can guide us for selecting the nodules for FNAB examination. Such method should be easily available, cheap & presumptive diagnosis should be done in one setting with immediate results.

Any malignant growth has neovascularization inside. The Power Doppler can detect this neovascularization in superficial tissues. If the nodule has good internal vascularity, then there is high possibility of its being malignant. If Power Doppler is combined with routine B mode ultrasound, we expect better screening of thyroid nodules for malignancy risk and it can guide us about which nodule should be investigated further.

**B-Mode Sonography Parameters**

There is vast discrepancy in incidence of malignancy in thyroid nodules. The incidence of malignancy in this study is 18/134 (13.43 %). Among them 66.66% were papillary ca, 27.77% follicular ca (histopathology results), 5.55% anaplastic ca. We didn't find any medullary ca. due to small sample size.

**TABLE 13 - Classification of malignant cases in the study population**

| Final diagnosis | Number | Percentage (%) |
|---|---|---|
| Papillary ca | 12 | 66.66 |
| Follicular ca | 5 | 27.77 |
| Medullary ca | 0 | 0 |
| Anaplastic ca | 1 | 5.55 |

**TABLE 14- Comparisons with previously published similar studies**

| Feature | Present study | Soliman et al(66) | Agrawal et al (62) | Samghabadi et al (67) | Rago et al(68) |
|---|---|---|---|---|---|
| Percentage of malignant nodules | 13.43 % | 17.40% | 25.86% | 39.17% | 28.84% |
| Percentage of malignant nodules with hypoechogenicity | 72.22% | 50% | Not evaluated | 71.05% | 66.66% |
| % of malignant nodules with microcalcifications | 66.66% | 16.66% | Not evaluated | 57.89% | 43.33% |
| % of malignant nodules with AP>Transv diameter | 61.11% | Not evaluated | Not evaluated | Not evaluated | Not evaluated |
| % of malignant nodules with absent peri. halo | 61.11% | Not evaluated | Not evaluated | 76.94% | 60% |
| Percentage of malignant nodules In each Vascularity pattern | | | | | |
| 1 | 0% | 0% | 0% | 13.15% | 16.66% |
| 2 | 0% | 3.7% | 0% | Not considered | Not considered |
| 3 | 8.06% | 5% | 25% | 15.78% | 16.66% |
| 4 | 81.81% | 38.88% | 75% | Not considered | Not considered |
| 5 | 100% | 100% | 0% | 71.05% | 66.66% |

In study done by Soliman et al [66] in 2015, the incidence of malignancy was, 17.4%, whereas a study done by Aggarwal et al [62] from India in 2015 showed the incidence of malignancy as 25 .86%.

Naik KS[16] has reported that multinodular thyroid disease has lesser risk of maignancy (1- 4%) vs higher malignancy risk of 10-25% in solitary thyroid nodule. This finding was challenged by other reports. Ross et al [91] and Solbiati et al [92] found 13 % and 30 % incidence of malignant cytology respectively in multinodular disease.

In this study 8/18 (44.44 %) malignant nodules were seen in multinodular disease. This support the concept that multinodular goiter doesn't signify benign nature. Higher incidence in the study can be due to advanced ultrasound machines detecting smaller nodules and the way we have selected the suspicious nodules for FNAB. Frates et al stated that "with multiple nodules, the cancer rate per nodule decreases, but the decrease is approximately pro-portional to the number of nodules so that the overall rate of cancer per patient, 10%-13%, is the same as that in patientswith a solitary nodule"[14]

In present study majority of the nodules were hypoechoic (37.31%) or mixed (41.79%). This may be because we used selected suspicious nodules from multinodular disease for FNAB, and hypoechogenicity was one of the criteria for suspicious nodules.

In the present study 13/18 (72.22 %) malignant nodules were hypoechoic 4/18 (22.22%) malignant nodules were mixed. In studies by Soliman et al,[66] Samghabadi et al [67] and Rago et al [68] the percentage of hypoechogenic nodules among malignant nodules was 50%, 71.05% and 66.66%, respectively. This finding correlated with old reports that hypoechgenicity can be seen in 70 % of malignant nodules. [92]

Few studies have shown that absence of halo signifies risk of malignancy. In a study by Mohammad Garib Salehi [65] absent halo sign was present in 80 % of malignant nodules whereas only 28.2% of benign nodules had absent halo. Studies by Samghabadi et al [67] and Rago et al [68] shown absence of halo in 78.94 % and 60 % respectively. These studies have shown that absence of halo has significant statistical correlation with malignancy. In present study 61.11 % of malignant nodules had absent halo, but it could not reach the level of statistical significance (p=0.088).

Microcalcifications were seen in 13 of 134 (9.7%) nodules among them 12 (92.30%) were malignant. This high percentage could be due to high percentage of papillary carcinoma in study population which is known to harbor microcalcifications. Soliman et al[66] found microcalcifications only in 16.66 % cases. This difference may be because he divided micro calcifications itself in numerous and few microcalcification group. In other studies the presence of microcalcifications was ranging from 43-72% [66,67,68]

This finding correlated with other reports indicating that microcalcifications has good sensitivity and specificity to detect malignancy and thy can be seen in 60-80% of malignant nodules.[93]The anteroposterior diameter more than transverse diameter (i.e. AP/Transverse diameter ratio >1) has been proved to be significant indicator of malignancy.

**TABLE 15- Comparison of studies related to dimensions of thyroid nodule**

| Criteria AP>Transverse diameter | Present study | Kim et al[94] | Cappelli et al[95] | Moon et al[11] |
|---|---|---|---|---|
| Sensitivity | 61.11 % | 32.705 | 76% | 40% |
| Specificity | 86.20% | 92.5% | 60% | 91.40% |

Kim et al [94] initially described the taller-than-wide sign. They postulated that "benign nodules grow parallel to normal tissue planes, whereas malignant nodules (taller than wide) grow across normal tissue planes". But Yoon et al [96] stated there is no evidence of tissue planes in thyroid gland. They hypothesized that the anteroposterior diameter of malignant nodule is more than benign nodules because malignant ones are not compressible by ultrasound probe and benignnodules are compressible. To prove this they compared thyroid nodule dimensions by US and CT. They found that the mean AP diameter of benign nodules was smaller in US than CT reports (because they were compressed by US probe!).

As much as 50 % of population can harbor thyroid nodules being clinically occult. They can be detected as incidentalomas when imaging done for other purposes. Many experts has suggested that FNAB is the best initial approach to palpable and non-palpable nodules with >1.5 cm in diameter that are incidental findings on ultrasound examinations.[87,97] And nodules smaller than that should be followed-up. It is suggested in previous guidelines and Ultrasound Consensus Conferences that for nodules less than 10 mm, only those with a high-risk of malignancy or suspicious US features must be biopsied. [13]Thus for smaller nodules the screening of suspicious findings on initial imaging is of utmost

importance. Addition of Doppler criteria gives extra edge to US to detect suspicious nodules.

**Power Doppler Parameters**

Few previous studies[67,68] had taken 3 types of vascularity patterns; viz no vascularity, perinodular and intranodular vascularity. Also in reports, by Moon et al[11] , Mohd Garib Salehi[65], central and peripheral vascularity pattern was seen in both malignat and benign nodules. Such findings posed a question on reliability of doppler in detecting malignant nodules. To tackle this issue we subdivided the central and peripheral vascular pattern proposed by Lagalla et al [10] into patterns 3 and 4, and also added pattern 5 to indicate exclusively central blood flow.

Present study classification consists of the following 5 vascular patterns: pattern 1→ absence of blood flow; pattern 2→ exclusively perinodular blood flow; pattern 3→ perinodular blood flow > central blood flow; pattern 4→central blood flow > perinodular blood flow; and pattern 5→exclusively central blood flow.

In this study 14/134 (10.44%) nodules were avascular (pattern 1), none of them was malignant. Recent study by Agarwal et al [62] had 1 patient with avascular nature which was benign. Soliman et al [66] also had all benign nodules in absent vascularity group. Samghabadi et al [67] and Rago et al [68], Mohd Garib Salehi et al [65] found 13.15 %, 16.66%, 12% malignant nodules with avascular nature (pattern 1) respectively.

This difference could be because later 3 studies used only 3 patterns avascular, peripheral and central so the precision might be less to detect very low blood flow. Rago et al [68] found absence of signal blood flow in papillary carcinoma patients. This can be due to the equipment used (transducer up to 7.5 MHz with lower color Doppler sensitivity) and methods.

While performing power Doppler study probe pressure should be kept minimum because even light pressure can obliterate slow velocity flow and nodule may appear avascular. Pattern 2 vascularity was seen in 43/134 nodules (32.08%), all of them were benign. Agrawal et al [62] found this pattern in 17.94% nodules, all of them benign. Soliman et al [66] found 5.5% malignancy rate in this pattern. Samghabadi et al[67] and Rago et al[68] didn't consider this pattern. These findings demonstrate that exclusively perinodular blood flow strongly suggests benignity. Pattern 3 grouphad 8.06% malignant nodules. In pattern 4 and 5, 81.81% and 100 % nodules were malignant respectively.

Present study results demonstrate that the risk of malignancy increases as intranodular blood flow becomes more dominant. For example, a small number of the nodules with pattern 3 blood flow (5 of 62 nodules) were malignant, whereas 9 of 11 nodules with pattern 4 blood flow and all 4 nodules with pattern 5 blood flow were malignant. These findings are in concordance with results reported by other authors. [65,67,68]

In present study all nodules in pattern 1 (absence of blood flow) and pattern 2 (exclusively perinodular flow) were benign, collectively accounted 57 (49.13%) of the 116 benign nodules. Individually, pattern 3 (perinodular blood flow > central blood flow) was seen more often. In addition, the greatest proportion of nodules with follicular cytology 9/14 (64.28%) had vascular pattern 3. Vascular pattern 4 (central blood flow > perinodular flow) or 5 (exclusively central blood flow) was collectively seen in 8/10 (80 %), malignant nodules.

**Waved Pulsed Doppler Parameter**

It is technically quite difficult to set the insonation angle, and small-caliber vessels this may be responsible for the discrepant blood flow velocities observed by other authors for malignant nodules. To reduce this interobserver and intraobserver variability it is suggested to use quantitative index i.e. resistive index (RI).In this study for resistive index of 0.69 the sensitivity to detect malignancy was 72.22 % and specificity of 93.10%. As RI goes above 0.69 sensitivity decreases and specificity increases. Malignant nodules had higher RI than benign nodules. This difference was statistically significant. This finding is in concordance with finding of Chammas et al[4] & Agrawal et al[62] where they found mean RI of 0.74 & 0.75 in malignant nodules respectively which was more than RI of benign nodules. This increased RI in malignant nodules can be due to vascular stenosis seen in malignant tissue, leading to low diastolic velocities and high systolic velocities. (RI= PSV-MDV/PSV)

Logistic regression analysis revealed that the vascular pattern and RI are good predictors of malignancy. Sensitivity and specificity of the model was 96.61% and 87.50%, respectively. PPV was 98.27%, NPV was 77.77%.

Thus, nodules associated with vascular pattern 4 and 5 (independent of RI), as well as nodules associated with vascular pattern 3 or 4 and RI of >0.69 are at high risk for malignancy and should be studied by FNAB.

US features like AP/transverse diameter and echogenicity, calcification are additional indicators of malignant nodules. The sensitivity and specificity, positive predictive value and negative predictive value of model having these factors was 95 %, 85.71%, 98.27%, 66.66% respectively.

**Limitations**

Present study had few limitations like the vascularity pattern based classification is subjective. However, it appears to be the best possible way to represent the vascularity in nodules. The similar results have been reported previously but those studies are either retrospective [68], done on cold nodules,[65,67] some took only 3 vascular patterns,[66,67] some didn't consider histopathology findings for suspicious or follicular cytology.[4] This study fulfills these lacunae.

Other limitations were we didn't follow the benign nodules for malignant change. Some authors have suggested to follow benign nodules for 12 month. [11, 96] Histopathology was not available for all nodules. Hyperthyroid and purely cystic nodules were excluded. There are some reports of malignancy in background of thyrotoxicosis[98] and purely cystic nodules.[99] Again study evaluated only one thyroid nodule in MNG so malignancy in deeper nodules may be missed.

## CONCLUSION

Ultrasound is imaging of choice for thyroid nodules. The B mode ultrasound features including hypoechogenicity, microcalcifications, antero-posterior diameter more than transverse diameter guide to select nodules potentially requiring surgery. Inclusion of doppler in routine ultrasound imaging gives extra information on nature of thyroid nodule. As the intranodular vascularity increase in euthyroid patient, the risk of malignancy increases. Nodules having predominant central vascularity should be biopsied. Nodules having no vascularity or peripheral vascularity are usually benign, they can be followed.

The Resistive index has good specificity and positive predictive value in identification of malignant nodules. Overall doppler have a diagnostic sensitivity and specificity of 96.61% and 87.50%, respectively in the detection of malignant nodules.

## RECOMMENDATIONS

1) Since B mode Ultrasound and Doppler both are inexpensive, noninvasive, and accessible imaging tools they should be used more frequently by clinicians to assist or to substitute other invasive methods.
2) The nodules with size <10 mm should be looked for suspicious findings on ultrasound and doppler e.g. hypoechogenicity, microcalcifications, AP>Transverse diameter, intranodular vascularity, RI.
3) Nodules <10 mm with suspicious characteristics should be carefully studied and others without suspicious characteristics should only be followed-up.
4) Nodules >10 mm with benign characteristics (eg, hyperechogenicity, peripheral halo, macrocalcifications, peripheral vascularity, lower RI) should be followed-up and subjected to biopsy if they show any change in appearance or size.
5) In multinodular disease, the nodules with suspicious US findings, having pattern 4 or 5 vascularity or having more resistive index should be subjected to FNAB.
6) While examining the thyroid nodule the probe pressure should be kept minimum so that it will not affect the shape of nodule and vascularity pattern.
7) In situations where FNAB is non diagnostic or shows follicular cytology, one should consider Ultrasound+ Doppler findings for decision about further work up.

## REFERENCES

1. Hegedus L. Clinical practice: The thyroid nodule. N Engl. J Med 2004; 351 17:1764–71.
2. Horvath E, Majlis S, Rossi R, Franco C, Niedmann JP, Castro A, et al. An ultrasonogram reporting system for thyroid nodules stratifying cancer risk for clinical management. J Clin Endocrinol Metab 2009; 94:1748-1751.
3. Ross DM. Diagnostic approach to and treatment of thyroid nodules. In: Rose BD, editor. Wellesley (MA): UpToDate; 2005.
4. Chammas MC, Gerhard R, de Oliveira IR, Widman A, de Barros N, Durazzo M, et al.Thyroid nodules: evaluation with power Doppler and duplex Doppler ultrasound. Otolaryngo Head Neck Surg 2005; 132:874-882.
5. Fukunari N, Nagahama M, Sugino K, Mimura T, Ito K. Clinical evaluation of color Doppler imaging for the differential diagnosis of thyroid follicular lesions. World J Surg 2004; 28:1261-1265.

6. Hossein Gharib, Enrico Papini, Thyroid Nodules: Clinical Importance Assessment, and Treatment. Endocrinol Metab Clin N Am 36; 2007:707–735.
7. Cooper DS, Doherty GM, Haugen BR, Kloos RT, Lee SL, Mandel SJ. Revised American Thyroid Association Management Guidelines for Patients with Thyroid Nodules and Differentiated Thyroid Cancer. Thyroid 2009; 19:1167-214.
8. Brander AE, Viikinkoski VP, Nickels JI, et al. Importance of thyroid abnormalities detected at US screening: a 5-year follow up Radiology 2000; 215:801-6.
9. Sabel MS, Haque D, Velasco JM, et al. Use of ultrasound-guided fine needle aspiration biopsy in the management of thyroid disease. Am Surg 1998; 64:738-41.
10. Lagalla R, G Caruso, Novara V, et al. Analysis fluximetric in thyroid disease: hypothesis of integration with the qualitative study with color Doppler. Radiol Med 1993, 85: 606-10.
11. Moon HJ, Kwak JY, Kim MJ, Son EJ, Kim EK. Can vascularity at power Doppler US help predict thyroid malignancy? Radiology 2010; 255:260-269.
12. Moon WJ, Jung SL, Lee JH, Na DG, Baek JH, Lee YH, et al. Benign and malignant thyroid nodules: US differentiation--multicenter retrospective study. Radiology 2008; 247:762- 770.
13. Gharib H, Papini E, Paschke R. Thyroid nodules: a review of current guidelines, practices, and prospects. Eur J Endocrinol 2008; 159:493-505.
14. Frates MC, Benson CB, Charboneau JW, Cibas ES, Clark OH, Coleman BG, et al. Management of thyroid nodules detected at US: Society of Radiologists in Ultrasound consensus conference statement. Radiology 2005; 237:794-800.
15. Bakhshaee M, Davoudi Y, Mehrabi M, Layegh P, Mirsadaee S, Rad MP, et al. Vascular pattern and spectral parameters of power Doppler ultrasound as predictors of malignancy risk in thyroid nodules. Laryngoscope 2008; 118:2182- 2186.
16. Naik KS, Bury RF. Imaging the thyroid. Clin Radiol 1998; 53: 630-9.
17. Phuttarak W, Somboon porn C, Hongdemnern G . Diagnostic performance of gray scale vs combined gray scale with colour Doppler ultrasound in diagnosis of malignancy in thyroid nodules, Asian pac j cancer prew. 2009:10 (5) 759-764.
18. S. Z. Ali and E. S. Cibas, Eds., The Bethesda System for Reporting Thyroid Cytopathology. Definitions, Criteria and Explanatory Notes, Springer, New York, NY, USA, 2010.
19. Haeger K.: The beginnings of medicine. In .van leuven J. ed. The illustrated history of surgery: London.Harold Starke. 1988.19-23.
20. Leoutsakos V. A short history of the thyroid gland. Hormones. 2004; 3:268–71.
21. Kalra S. Endocrinology in Ayurveda: Modern Science, Ancient history. Indian J Endocrinol Metab. 2011: Jul; 15(Suppl2): S121–S126.
22. Hippocratis M. Lipsiae. Opera Omnia. Carolus Gottlob Kunh. 1825-1827; 3:658.
23. Blumberg BS. Goiter in Gandhara. JAMA. 1964; 189:1008–12. .
24. Marketos S, Eftychiadis A, Koutras DA. Thyroid diseases in the Byzantine era. J R Soc Med. 1990; 83:111–3. .
25. Amideni A, Zervos A. Liber XV. 1909; 21:22–4.
26. Bifulco M, Cavallo P. Thyroidology in the medieval medical school of Salerno. Thyroid. 2007; 17:39–40.
27. O'Malley, C.D. Leonardo on the human body. Dover, New York; 1952 (169-170).
28. Medvei VC. A History of Endocrinology. Lancaster: MTP Press; 1982 (289–96).
29. Hegedus L.Thyroid sizedetermined by ultrasound. Influence of physiological factors and non thyroidal disease.Dan Med Bull 1990:37:29
30. Braun EM, Windisch G, et al. The pyramidal lobe: clinical anatomy and its importance in thyroid sugery. Surg. Radiol. Anat 2007;29:21.
31. Kousta E. Konstantinidis K, Michalakis C el al. Ectopic thyroiid tissue in the lower neck with a coexisting normally locaated multinodular goiter and brief literature review. Hormones (Athens) 2005;4:231.
32. Teitelbaum BJ, Weing BL. Superior Laryngeal nerve injury from thyroid surgery. Head neck 2005; 17-36
33. American Thyroid Association Surgery Working Group, American Association f Endocrine Surgeons, American Academy of Otolaryngology. Head and neck surgery, et al. Consensus statement on the terminology and classification of central neck dissecction for thyroid. Thyroid 2009;19:1153.
34. Salvatore D Devis T. Thyroid Physiology and Diagnostic Evaluation of Patients with Thyroid Disorder In: Shlomo Melmed, Kenneth S. Polonsky, P. Reed Larsen, Henry M, Kroenberg, eds. Williams Texbook of Endocrinology. 12th ed. Philadelphia: Elsevier/Saunders; 2011:327-330.
35. Jameson JL, Weetman AP Disorders of thyroid gland. In: Fauci AS, Braunwald E, Kasper DL, Hauser SL, Longo DL, Jameson JL, et al., editors. Harrison's Principle of Internal Medicine. 18th ed. New York: McGraw-Hill; 2012. pp. 2911-2922.
36. William A Meissner, Shield et al Pathological classifications of thyroid neoplasm, 1989 23(12),166-194.
37. Jenny K. Hoang, FRANZCR, Wai Kit Lee, et al: US Features of Thyroid Malignancy: Pearls and Pitfalls, Aug 2006.114.
38. Stewart RR et al: The thyroid in patients of Hodgkin's disease treated with radiation therapy in childhood, Radiology. 1989; 172: 152.
39. Nordemeyer J P et al: Thyroid sonography in autoimmune thyroiditis. A prospective study on 123 patients, Acta, Endocrinol;1990, 123:301.
40. Carol M Rumack, Stephanie R Wilson et al: Diagnostic Ultrasound. 3rd edition; 735-770.
41. Levine R. Something old and something new: A brief history of thyroid ultrasound technology. Endocrine Practice. 2004; 10(3):227-233.
42. Yamakawaka, S Naito: Proccedings First Int. Conf. Diagnostic Ultrasound,Pittsburgh.
43. Fujimoto Y A oak: Ultrasonic scanning of the thyroid gland as a new diagnostic approach. Ultrasonic, 1967, 5: 177-88.
44. Rasmussen S N et al: A differentiation between cystic and solid thyroid nodules by ultrasonic examination. Acta Chir, Scand.1971, 137;331-333 1971.
45. Brander A, Viikinkoski P, Tuuhea J, Voutilainen L, Kivisaari L. Clinical versus ultrasound examination of the thyroid gland in common clinical practice. J Clin Ultrasound 1992;20:37-42
46. Hassanis et al :Ultrasonography of solid thyroid neoplasm , the multiple 'halo' sign presented at the 23 rd Annual meeting of the American Institute Of Ultrasound In Medicine; Sandiego CA, 1978 .1980;81,129-132.
47. William Scheible et al: High resolution real time ultrasound of thyroid nodules-. Radiology, Nov 79, 133:413-417.
48. Leopold GR: Thyroid cancer, Med Clinics North America Am 1991, 75; 211. 110.
49. Paul D Radecki et al: Thyroid Imaging; Comparison of high resolution real time ultrasound and computed tomography, Radiology, 1984 153: 145-47.
50. Robert FK et al: Thyroid nodule sonographic-pathologic correlation. Radiology 1984, 151; 741-745.
51. Luigi Solbiati L et al: The thyroid gland with low uptake lesions; Radiology 1985; 1156:138.
52. James GM and Charbeneu et al: High frequency ultrasound sonography seminar, AJR 1985, 6(3) 294-309.
53. Hatabu H et al: Cystic papillary carcinoma of the thyroid gland- A new sonographic sign. Clinical Radiology 1991; 43: 121.
54. Mehta N, Tripathi RP, Popli MB, Nijhawan VS. Sonographic Appearances of Solitary Thyroid Nodule. Ind J Radiol Imag 1994; 4: 211-217.
55. Erdogan MF, Anil C et al: Color flow Doppler sonography for the etiologic diagnosis of hyperthyroidism. Thyroid 2007 Mar; 17(3); 223-8.
56. Rago T, Vitti P: Role of thyroid ultrasound in the diagnostic evaluation of thyroid nodules. Best Pract Res Clin Endocrinol Metab ; 2008 Dec; 22(6);913-28.
57. Park M, Shin JH, Han BK, Ko EY, Hwang HS, Kang SS, et al. Sonography of thyroid nodules with peripheral calcifications. J Clin Utrasound. 2009; 37(6):324-8.
58. Lacout A, Marcy P, Thariat J. : RE: Role of Duplex Doppler US for Thyroid Nodules: Looking for the "Sword" Sign. Korean J Radiol 2011: 12(3):400.
59. Young Hun Lee, Dong Wook Kim, Hyun Sin In, Ji Sung Park, Sang Hyo Kim, Jae Wook Eom, et al. Differentiation between Benign and Malignant Solid Thyroid Nodules Using an US Classification System: Korean J Radiol 2011;12(5):559-567.
60. J. Fernández Sánchez. TI-RADS classification of thyroid nodules based on a score modified according to ultrasound criteria for malignancy: Rev. Argent. Radiol. 2014; 78 (3): 138-148.
61 Aggarwal A , Kaur N , Bhardwaj, Amritpal S Grover. Ultrasound of Thyroid Nodules: Finding the Best Parameter for Predicting Malignancy. IJAR 2014; (9)2: 583-9.
62. Aggarwal A, Kaur N, Bhardwaj. Color Doppler evaluation of thyroid nodules: Validation of quantitative & qualitative analysis in predicting malignancy. IJAR 2015; (7) 3: 1120-6.
63. Moon H, Kim E, Yoon J. Malignancy Risk Stratification in Thyroid Nodules with Nondiagnostic Results at Cytologic Examination: Combination of Thyroid Imaging Reporting and Data System and the Bethesda System. Radiology: 2015.274(1):287- 295.
64. Rosario P, Silva A, Borges M. Is Doppler ultrasound of additional value to gray-scale ultrasound in differentiating malignant and benign thyroid nodules?: Arch Endocrinol Metab. 2015; 59 (1):79-83.
65. Salehi M, Nalaini F, Izadi B, Setayeshi K, Rezaei M, Naseri S. Grey scale vs color doppler ultrasound in cold thyroid nodules. GJHS. 2014: 7(3).
66. Soliman H.H. Role of Color Doppler Ultrasonography in Predicting Risk of Malignancy in Thyroid Nodules in Correlation with Ultrasound Guided Fine Needle Aspiration Biopsy: Med. J. Cairo Univ 2015 (2)83,263-73.
67. Samghabadi MA, Rahmani M, Saberi H, Behjati J, Firouznia K, Ghasemian A. Sonography and color doppler in the evaluation of cold thyroid nodules. Iran J Radiol. 2004; 2:12–17.
68. Rago T, Vitti P, Chiovato L, Mazzeo S, De Liperi A, Miccoli P et al. Role of conventional ultrasonography and color flow-doppler sonography in predicting malignancy in 'cold' thyroid nodules. European Journal of Endocrinology. 1998; 138 (1):41-46.
69. Shapiro RS. Panoramic ultrasound of the thyroid. Thyroid 2003; 13:177.
70. Brunese L, Romeo A, Iorio S, et al. A new marker for diagnosis of thyroid papillary cancer: B-flow twinkling sign. J Ultrasound Med 2008; 27:1187.
71. Jacobsen JA. Ultrasound contrast agents: clinical applications. Eur Radiol 2001; 11:1329.
72. Appetecchia M, Bacaro D, Brigida R, et al. Second generation ultrasonographic contrast agents in the diagnosis of neoplastic thyroid nodules. J Exp Clin Cancer Res 2006; 25:325.
73. Garra BS. Imaging and estimation of tissue elasticity by ultrasound. Ultrasound Q 2007; 23:255.
74. Ghajarzadeh M, Sodagari F, Shakiba M. Diagnostic accuracy of sonoelastography in detecting malignant thyroid nodules: a systematic review and meta-analysis. AJR Am J Roentgenol 2014; 202:W379.
75. Peeters EY, Shabana WM, Verbeek PA, Osteaux MM. Use of a curved-array transducer to reduce interobserver variation in sonographic measurement of thyroid volume in healthy adults. J Clin Ultrasound 2003; 31:189.
76. Lyshchik A, Drozd V, Reiners C. Accuracy of three-dimensional ultrasound for thyroid volume measurement in children and adolescents. Thyroid 2004; 14:113.
77. Brauer VF, Eder P, Miehle K, et al. Interobserver variation for ultrasound determination of thyroid nodule volumes. Thyroid 2005; 15:1169.
78. Foley WD. Physical principles and instrumentation. In: Color Doppler Flow Imaging, Foley WD (Ed), Andover Medical Publishers, Boston 1991. p.3.
79. Clark KJ, Cronan JJ, Scola FH. Color Doppler sonography: anatomic and physiologic assessment of the thyroid. J Clin Ultrasound 1995; 23:215[2,3].
80. Hiromatsu Y, Ishibashi M, Miyake I, Soyejima E, Yamashita K, Koike N, Nonaka K 1999 Color Doppler ultrasonography in patients with subacute thyroiditis. Thyroid 9:1189.
81. Kunz A, Blank W, Braun B. De Quervain's subacute thyroiditis - colour D o p p l e r sonography findings. Ultraschall Med.2005; 26:102.
82. Rago T, Chiovato L, Grasso L, Pinchera A, Vitti P. Thyroid ultrasonography as a tool for detecting thyroid autoimmune diseases and predicting thyroid dysfunction in apparently healthy subjects. J Endocrinol Invest 2001.24:763.
83. Dirikoc A, Polat SB, Kandemir Z, Aydin C, Ozdemir D, Dellal FD, Ersoy R, Cakir B Comparison of ultrasonography features and malignancy rate of toxic and nontoxic autonomous nodules: a preliminary study.Ann Nucl Med. 2015:29(10):883-9.
84. Wong R, Cheung W, Stockigt JR, Topliss DJ. Heterogeneity of amiodarone- induced thyrotoxicosis: evaluation of colour-flow Doppler sonography in predicting therapeutic response. Intern Med J 2003.33:420-6.
85. Wang CY, Chang TC. Thyroid Doppler ultrasonography and resistive index in the evaluation of the need for ablative or antithyroid drug therapy in Graves' hyperthyroidism. J Formos Med Assoc 2001;100:753.
86. Nagasaki T, Inaba M, Kumeda Y, Fujiwara-Ueda M, Hiura Y, Nishizawa Y Significance of thyroid blood flow as a predictor of methimazole sensitivity in untreated hyperthyroid patients with Graves' disease. Biomed Pharmacother 2007;61:472
87. Khalid AN, Quraishi SA, Hollenbeak CS, Stack BC, Jr. Fine-needle aspiration biopsy versus ultrasound-guided fine-needle aspiration biopsy: cost-effectiveness as a frontline diagnostic modality for solitary thyroid nodules. Head Neck 2008;30:1035.
88. Wienke Jr, Chong W.K, Fielding, Zou K.H. Sonographic features of benign thyroid nodules: Interobserver reliability and overlap with malignancy. J. Ultrasound. Med.2003 22: 1027- 31.
89. Poller D. Thyroid cytopathology: An Atlas. Cytopathology 2008;19(5):333-333
90. Moon HJ, Kim EK, Yoon JH, Kwak JY. Malignancy risk stratification in thyroid nodules with nondiagnostic results at cytologic examination: combination of thyroid imaging reporting and data system and the Bethesda System. Radiology 2015; 274:287–295.
91. Ross DS. Evaluation of the thyroid nodule. J Nucl Med 1991; 32:2181-92.
92. Solbiati L, Livraghi T, Ballarati E, et al. Ultrasound of superficial structures: high frequencies, Doppler and interventional procedures.New York, NY: Churchill Livingstone; 1995.
93. Takashima S, Fukuda H, Nomura N, et al. Thyroid nodules: re-evaluation with ultrasound. Clin Ultrasound 1995; 23:179-84.
94. Kim EK, Park CS, Chung WY, et al. New sonographic criteria for recommending fine-needle aspiration biopsy of nonpalpable solid nodules of the thyroid. AJR 2002; 178:687–691.
95. Cappelli C, Castellano M, Pirola I, et al. Thyroid nodule shape suggests malignancy. Eur J Endocrinol 2006; 155:27–31.
96. Yoon SJ, Yoon DY, Chang SK et al. "Taller –than –wide sign" of thyroid malignancy: comparison between ultrasound and CT. AJR 2010, 194:194:1343. W420- W424
97. Gharib H. Thyroid nodules: management controversies. Washington, Mayo Foundation, 1995; 1-11-bg (LS). [The Endocrine Society 77th Annual Meeting, Meet the Professor Session, Washington, DC, June 14, 1995].
98. Kalliopi Pazaitou-Panayiotou, Petros Perros, Maria Boudina, George Siardos, Apostolos Drimonitis, Friderіki Patakiouta, Iraklis Vainas: Mortality from thyroid cancer in patients with hyperthyroidism: the Theagenion Cancer Hospital experience: European Journal of Endocrinology (2008) 159 799–803.
99. Patil V, Vijayakumar A, Natikar N. Unusual Presentation of Cystic Papillary Thyroid Carcinoma: Case Reports in Endocrinology 2012; 1-4.