ORIGINAL RESEARCH PAPER

Volume-7 | Issue-11 | November-2018 | PRINT ISSN No 2277 - 8179

INTERNATIONAL JOURNAL OF SCIENTIFIC RESEARCH

# ROLE OF FLUORESCEIN ANGIOGRAPHY IN EVALUATION OF FUNDUS DISORDERS

Ophthalmology

**Dr. M. Yeswant** — Final Year Postgraduate, Department of Ophthalmology, Meenakshi Medical College Hospital & Research Institute, Meenakshi Academy of Higher Education and Research, Kanchipuram, Tamil Nadu- 631552, India

**Dr. Soundarajan*** — Associate Professor, Department of Ophthalmology, Meenakshi Medical College Hospital & Research Institute, Meenakshi Academy of Higher Education and Research, Kanchipuram, Tamil Nadu- 631552, India *Corresponding Author

**Dr. Namitha Bhuvaneshwari.K** — Professor and Head, Department of Ophthalmology, Meenakshi Medical College Hospital & Research Institute, Meenakshi Academy of Higher Education and Research, Kanchipuram, Tamil Nadu- 631552, India

**Dr. Vignesh Govindharaj** — Second Year Postgraduate, Department of Ophthalmology, Meenakshi Medical College Hospital & Research Institute, Meenakshi Academy of Higher Education and Research, Kanchipuram, Tamil Nadu- 631552, India

## ABSTRACT

**Background:** Retinal disorders are the largest cause of legal blindness in the age group of 20 to 65 years. Approximately 18 million people in India have severely impaired vision due to retinal diseases. It has been nearly 40 years since the principle and techniques of fluorescein angiography were first described. The procedure has now become standardized and has found a regular place in routine diagnosis of fundus disorders.

**Objectives :** This study was undertaken to assess the evaluate the role of fluorescein angiography and underline it`s advantages over other conventional methods of ophthalmoscopy in the evaluation of posterior segment diseases.

**Methods:** A prospective study was done which included 40 patients who attended the OPD during study period. Detailed history was taken from the patient and a thorough ocular and systemic examination was done.

**Results:** 40 cases were analyzed and sub-divided into 3 categories of macular disorders, retinal vascular disorders and inflammatory conditions. FA altered the diagnosis in 13.34%, 50% and 12.5% cases while categorized the lesions in 53.34%, 12.5% and 62.5% cases respectively. On statistical analysis, FA proved to be a far superior diagnostic modality.

**Conclusions:** In the present study we conclude that FA can help to detect cases beyond the reach of clinical ophthalmoscopy.

## KEYWORDS

Retinal disease; fluorescein angiography

## I. INTRODUCTION

Visions are our primary contact with the environment. Loss of sight is the most feared of all disabilities especially so if involving the posterior segment. Fundus disorders are increasingly becoming a common cause of permanent and yet avoidable cause of blindness. They carry a high risk of ocular morbidity in all age groups.

Retinal disorders are the largest cause of legal blindness in the age group of 20 to 65 years.[1] Annually, 18 million people in India have severely impaired vision due to retinal diseases. 57 million diabetics are at risk of developing blinding disorders in India. Prevalence of ARMD above 60 years ranges from 0.6% to 1.1% in india.[2] from the international perspective, 8% of legal blindness in the US and 5% in UK has been attributed to retinal diseases[3]. Visual outcomes vary from full recovery to complete blindness with physical and psychological loss and enormous economical burden on the society[3].

Fluorescein angiography has contributed greatly to the diagnosis and treatment of various chorioretinal disorders like diabetic retinopathy, cystoid macular edema, CSR, venous occlusive disease etc. It allows to examine the structures beyond the reach of clinical ophthalmoscopy. A modern angiogram consists of a series of high contrast black and white transparencies taken at speeds of 0.6S interval[4,5].

The blood-retinal barriers are at RPE, Bruch`s membrane and retinal vasculature. FA findings are analyzed in relation to these barriers[6]. A positive fluorescein angiographic findings is a frequent occurrence in ophthalmoscopically invisible lesions. It almost always shows more microvascular lesions. Macular oedema and staining than is observed ophthalmoscopically. After 4-8 years of diabetes, ophthalmos copically diagnosable retinopathy is to expected in patients in whom initial FA showed signs of angiopathy.

## II. METHODOLOGY

The study was conducted in the outpatient Department of Ophthalmology at Meenakshi Medical College Hospital and Research Institute, Kanchipuram from April 2017 to August 2018.

Approval for the study protocol and clearance were obtained from the institutional ethical committee.

A total number of 40 cases were selected for the study and the patient data was categorized into age, sex, history of drug allergy and systemic illness was analyzed.

### Notification of case history

A thorough and detailed history was taken of the selected patients. Complete ophthalmic and medical history was noted with special emphasis on history of drug allergy and systemic illness.

### Ocular examination:

A thorough and detailed ocular examination of the anterior segment was performed on the slit-lamp. Both direct and consensual papillary reactions were checked.

### Vision and refraction

Visaul acuity was recorede and refraction was done for both eyes.

### Intra-Ocular Pressure

- IOP was measured using a Schiotz or Goldmann`s applanation tonometer.
- Sac syringing was performed on both sides.

### Fundoscopy:

- A thorough careful and detailed examination of the fundus was done firstly by a direct ophthalmoscope and subsequently with an indirect ophthalmoscope giving special attention to vitreous opacities, optic disc, exudates, haemorrhage, scars, macula, peripheral retinal degenerations and retinal detachment.
- Fundus was cross- examined by a competent vitreo-retinal surgeon before documentation.
- Slit-lamp biomicroscopy with + 90D lens was performed to look for pathologies in the posterior pole and documented.

**Fluorescein angiography**

**Consent**

Patients were explained in detail in their own vernacular language about the condition of the eye, the procedure and purpose of fluorescein angiography and possible side effects after which an informed consent was taken.

## III. RESULTS

Totally 40 cases which presented to the outpatient department with fundus pathology were evaluated both by ophthalmoscopy and FA

**Classification of cases analyzed**

15 cases of macular diseases (37.5%), 16 cases of retinal vascular disorders (40%), 8 cases of inflammatory disorders (20%) and 1 case of optic drusen were analyzed.

| Sub group | Number of cases | Percentage |
|---|---|---|
| Macular disorders | 15 | 37.5 |
| Retinal Vascular disorders | 16 | 40 |
| Inflammatory disorders | 8 | 20 |
| Miscellaneous | 1 | 2.5 |

**Distribution of Retinal Vascular disorders**

On analysis of retinal vascular disorders, there were 8 cases of diabetic retnopathy (50%), 4 case of hypertensive retinopathy (25%), 5 cases of venous occlusive disease (31.2%) and 1 case of arterial occlusive disease (6.25%). Some cases had significant clinical features of 2 entities abd were considered in both groups.

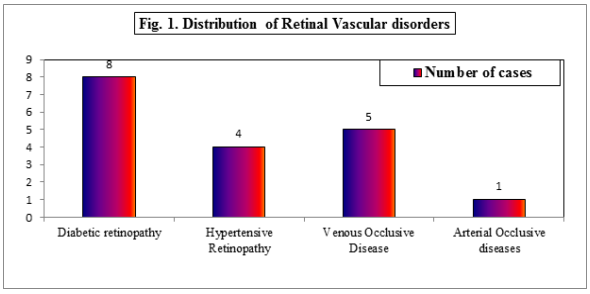


**Analysis of comparison between clinical ophthalmoscopy and FA**

| Sub group | (A) Correct clinical diagnosis (by ophthalmoscopy) | (B) Correct clinical diagnosis (by FA) |
|---|---|---|
| 1). Retinal vascular disorders (n=16) | 6(37.5) | 16(100) |
| 2). Macular disorders (n=15) | 5(33.3) | 15(100) |
| 3). Inflammatory disorders (n=9) | 2(22.2) | 8 (88.9) |
| Total fundus diseases (n=40) | 13 (32.5) | 39 (97.5) |

Applying Z test,
For group 1 between A & B Z=5.16 $p<0.05$, Significant.
For group 2 between A & B Z = 5.48 $p<0.05$, Significant
For group 3 between A & B Z = 5.62 $p<0.05$, Significant.
On applying Z-test,

For total sample size (n=40), between A & B Z=8.33 $P < 0.05$, Significant.

In this present study, FA has proved to be a far superior diagnostic modality as compared to ophthalmoscopy.

**On careful analysis:**

1. 13 patients were detected positive by both diagnostic modalities.
2. 9 clinically observed patients were either positive or showed a greater severity of disease on FA.
3. 3 clinically positive patients were either negative or showed lesser severity of disease
4. 15 patients although diagnosed positive clinically were categorized into specific subtypes on FA.

**For the above analysis:**

- A high percentage of cases detected positive by ophthalmoscopy are confirmed positive by FA.
- On the contrary, a high percentage of cases detected negative by ophthalmoscopy present as positive by FA indicating low negative predictive value.
- A very high percentage of cases although diagnosed positive by ophthalmoscopy are categorized into subtypes by FA.

Thus we deduce that, CO has a high positive predictive value but a low negative predictive value. Hence, FA is a superior diagnostic tool and is a necessity for evaluating clinically negative fundus disorders when in doubt.

## IV. DISCUSSION

In cases of posterior segment pathologices, sometimes the clinical presentation is non-specific and clinical examination alone is not sufficient for diagnosis and management. The development of FA in 1961 by Dr. Novotny and Dr. Alvis has enhanced the diagnostic accuracy of ophthalmic examination. FA examination and its analysis has reached a level of maturity that allows the technique to be first and foremost imaging technique necessary to evaluate the posterior segment of the eye.

Diabetic retinopathy, ARMD and ROP have become important and increasing causes of retinal blindness. It is expected that there would be 57 million diabetics in India by 2025 and 137 million people older than 65 years of age by 2021.

In this study, we have examined 40 patients in whom FA and clinical ophthalmoscopy was done for detection of fundal pathologies. Purpose of the present study is to determine practical value of FA with regards to its role as a diagnostic, confirmatory and prognostic indicator of various diseases in our country.

In our study, incidence of retinal vascular disorders was 40%.

**HTN retinopathy:** Both clinically diagnosed cases of hypertensive retinopathy were merely confirmed on FA. One case of BRVO was found to have signs of HTN retinopathy on FA. FA showed tortuous vessles with dilated veins and a generalized retinal and disc oedema with collaterals. In our study, no significant was found in documenting vessel caliber and A-V crossing changes.

However, Sharma BK et al in their study started that "Blood flow changes, capillary bed abnormalities and abnormal formation of vessels – New vessels and microaneuysms could not be seen on direct ophthalmoscopy but hard exudates by presence of blocked fluorescence with equal efficiacy. No statistically significant difference was found with either of the methods"[7].

**Diabetic retinopathy:**

In our study, as shown in figure.1, the incidence of DR was 50% of all cases of retinal disorders, of which 62.5% were proliferative, out of which 1 case had features of maculopathy also.

Wykes et al in their study in 1991 on 330 patients concluded that "treatment could have proceeded without FA only in 24% of diabetic patients"[8].

**Vascular Occlusive diseases:**

5 cases of venous occlusive and one case of arterial occlusion was analyzed in our study. 2 cases of clinically diagnosed CRVO were categorized into sub-types i.e., ischemic and non-ischaemic on FA. 3 cases of BAVO on FA showed presence of CMO, HTN retinopathy and NVE respectively.

On applying Z-test, analysis of comparison between C and FA was found to be significant. Thus, proving FA to be a superior investigative modality.

**On careful analysis:**

13 patients diagnosed positive on CO were confirmed by FA. Thus, CO had a high positive predictive value, 9 patients who were inconclusive on CO were found to have some lesion or the other on FA. Thus, CO had a low negative predictive value[9].

## V. CONCLUSION:

Thus, we conclude that patients diagnosed positive on CO should be looked with a high degree of suspicion but those found negative on CO should be subjected to FA as it now the "Gold Standard" for diagnosis.

## REFERENCES


1. Kanski JJ. Retinal vascular disease. Chapter 16, In : clinical ophthalmology – A systemic approach, 6th edn. New Delhi; Elsevier 2007: p.567.
2. Hussain N, Khanna R, Husssain A. Trend of retinal disease in developing countries. Expert Rev Opthalmol 2008;3(1):43-50.
3. See JIS, Wong Ty, Yeo KT. Trends in the pattern of blindness and major ocular diseases. Ann Acad Med Singapore 1998;27:540-46
4. Yanoff M, Duker J. Fluorescein and ICG angiography. In : clinical ophthalmology, 2nd edn. Hosby 2004:p.300-301
5. Sachdeva RP. Functional anatomy of macula and diagnostic procedures for macular function in clear media. Indian J ophthalmol 1983;31:105-7
6. Patz A. Principles of fluorescein angiography. International Ophthalmology Clinics 1977; 17(2):1-19.
7. Jain P, Gupta A, Sharma BK. A correlative study of ophthalmoscopy and flurescein angiography in Systemic HTN. Indian J ophthalmol 1990;38:169-74.
8. Wykes WN. Review of fluorescein angiograms performed in one year. Br J opthol 1991 july;75(7): 398-400
9. Hayrch SS. Retinal vein Occlusion. Indian J Ophthalmol 1994;42:109