ORIGINAL RESEARCH PAPER

Volume-7 | Issue-1 | January-2018 | PRINT ISSN No 2277 - 8179

INTERNATIONAL JOURNAL OF SCIENTIFIC RESEARCH

ROLE OF INTRATUMORAL APPARENT DIFFUSION COEFFICIENT VALUES AND MAGNETIC RESONANCE SPECTROSCOPY IN MENINGIOMAS AND SCHWANNOMAS

Radiodiagnosis

Dr. Gaurav Mishra* Assistant Professor, Department of Radiodiagnosis, Acharya Vinoba Bhave Rural Hospital, Sawangi (Meghe), Wardha .*Corresponding Author

Dr. Suresh Phatak Professor and Head, Department of Radiodiagnosis, Acharya Vinoba Bhave Rural Hospital, Sawangi (Meghe), Wardha

Dr. Deorao Kakde Professor, Department of Radiodiagnosis, Acharya Vinoba Bhave Rural Hospital, Sawangi (Meghe), Wardha

ABSTRACT

Application of magnetic resonance spectroscopy and diffusion weighted imaging sequences in the setting of meningioma and schwannoma has been sought after to uncover their traits at a deeper level, a molecular level. Our study includes 59 cases, 40 cases of meningioma and 19 cases of schwannomas, highlighting the role of the said advanced MRI sequences. Our study reported that there is elevation of myoinositol peak in schwannomas specifically , vice versa a reversed peak of the same metabolite in meningiomas with statistically significant difference in between intratumoral ADC values in the two, ones belonging to schwannomas being much higher than those of meningiomas.

KEYWORDS

meningioma, schwannoma, diffusion weighted imaging, apparent diffusion coefficient, magnetic resonance spectroscopy

Introduction :-

Newer modalities and modalities with more and more recent advances are taking their place in today's world when it comes to diagnosing brain tumours. Considering a specific class of these, from the extraaxial compartment, most commonly encountered tumours are meningiomas and schwannomas. They possess characteristic properties and attributes on imaging modalities which helps us in clinching respective diagnosis. Getting a more detailed picture of MRI, using diffusion weighted imaging and magnetic resonance spectroscopy imaging sequences has opened the gates of newer research possibilities and thereby enhanced the perspective of the radiologist researcher. We have carried out a study of 59 cases in order to extract useful traits of these extraaxial tumours on newer MRI imaging sequences. There have been similar studies in recent times emphasising use of these imaging modalities and imaging sequences for betterment of diagnostic edge and accuracy[1,2,3].

Material and methods :-

A prospective study was carried out in the Department of Radiodiagnosis, Acharya Vinoba Bhave Rural Hospital, Sawangi (Meghe), Wardha over a period of 2 years. All cases with cranial meningiomas and schwannomas were included irrespective of their age, sex and occupation, and those cases who were claustrophobic, having post operative history or any metallic implants, stents, coils or pacemakers were excluded. The study approval was obtained from Institutional Ethics Committee and all patients were asked to go through informed consent. 59 patients (40 with meningiomas, 19 with schwannomas) underwent magnetic resonance imaging. MRI was carried out on 1.5 Tesla MRI equipment (GE BRIVO MR 355 make). All cases were examined using routine sequences, diffusion weighted imaging sequences with ADC values and magnetic resonance spectroscopy images were obtained from within the tumours. All tumours were finally diagnosed and classified over histopathological examination. Statistical tests were incorporated by using SPSS software.

Results :-

Our study included 59 cases, 40 with meningiomas and 19 with schwannomas. Out of these, 9 males and 31 females has meningiomas, while 8 males and 11 females had schwannomas. Meningiomas were mostly seen in age group of 51 to 60 years (n=12) followed by 61-70 years (n=10). Schwannomas were mostly seen in age group of 21 to 30 years (n=7) followed by 31 to 40 years (n=4). Most commonly sites for meningiomas were parafalcine and parietal convexities while 100% schwannomas were seen occurring in cerebellopontine region. On diffusion weighted imaging, 16 meningiomas showed presence of mild restriction while 24 meningiomas failed to show any restriction. 17 schwannomas showed mild to moderate restriction on diffusion weighted imaging while 2 cases did not show any demonstrable restriction as such. Intratumoral ADC values recorded in meningiomas showed that minimum, maximum and mean ADC values were 0.631 X 10^{-3} ,1.473 X 10^{-3} and 1.012 X 10^{-3} respectively. Intratumoral ADC values recorded in schwannomas showed that minimum, maximum and mean ADC values were 1.171 x X 10^{-3},1.563 X 10^{-3} and 1.436 X 10^{-3} respectively. There was statistically significant difference in between intratumoral ADC values amongst meningiomas and schwannomas ($p<0.05$). On MRS, schwannomas showed a mild to moderate myoniositol peak in all cases which was not seen in meningiomas. Alanine and glutamate peaks were specifically noted in meningioma cases and were not seen in schwannomas. N- acetylaspartate, lipid lactate peaks were seen at lower than normal levels in schwannomas and meningiomas. Mild choline peaks were seen in both meningiomas and schwannomas. Creatinine was seen decreased in both, but more in meningiomas as compared to schwannomas. However, there was no statistically significant difference in between creatinine peaks in both ($p>0.05$). Also, an important feature of differentiation between the two entities occurring in the cerebellopontine region, widening of the internal acoustic meatus was exclusively shown by schwannomas.

Discussion :-

We recorded lower than normal levels of NAA, Choline, Creatinine and lipid lactate metabolites in both meningiomas and schwannomas. These results are in unison with Kugel et al[4]. Myoinositol was a metabolite which was showing severely lower levels in meningiomas whereas schwannomas showed an elevated peak for the same metabolite. Specific elevation of myoinositol in schwannomas in our study is in conjunction with Y. D. Cho et al[1], Kinoshita et al[5] and Yoshita et al[6]. Alanine and glutamate peaks observed in meningiomas were not seen in schwannomas, in agreement with inferences from Y. D. Cho et al[1]. Intratumoral ADC values in schwannomas were statistically significantly higher than those in meningiomas. These results are in the same direction as Yamasaki et al[7] and Sener at al[8].

Limitation :-

A study with a larger sample size with double blinding will help validate and standardize the obtained results.

Conclusion :-

Use of magnetic resonance spectroscopy and diffusion weighted imaging surely assists in properly diagnosing both meningiomas and schwannomas. Properties of the tumour on a molecular level of metabolites as well as the manner in which water molecules diffuse across the intratumoral cells are well elaborated while using magnetic resonant spectroscopy and diffusion weighted imaging sequences, thus adding to research potential of the same in a developing nation like ours in future, when applied in the setting of other tumour classes therein.

Tables :-

1.Sexwise distribution of meningiomas and schwannomas

Meningiomas	
Males	**Females**
9	**31**
Schwannomas	
Males	**Females**
8	**11**

2. Agewise distribution of cases

Age group in years	Number of meningiomas	Number of schwannomas
11-20	0	1
21-30	0	7
31-40	8	4
41-50	8	2
51-60	12	3
61-70	10	2
71-80	2	0

3. Sitewise distribution of cases

Site of tumour	Number of meningiomas	Number of schwannomas
Parafalcine	11	0
Parietal	9	0
Temporal	7	0
Frontal	5	0
Olfactory	2	0
Sphenoid	1	0
Cerebellopontine	5	19

4. Restriction on Diffusion weighted imaging

	Restriction present	Restriction absent
Meningiomas	**16**	**24**
Schwannomas	**2**	**17**

5.Intratumoral ADC values on ADC mapping in meningiomas and schwannomas

Meningiomas	ADC_{min}	ADCmax	ADCmean
	0.631×10^{-3}	1.473×10^{-3}	1.012×10^{-3}
Schwannomas	ADC_{min}	**ADCmax**	**ADCmean**
	1.171×10^{-3}	1.563×10^{-3}	1.436×10^{-3}

6. Levels of metabolites observed on MRS in benign and malignant meningiomas

Metabolite	Meningiomas	Schwannomas
Cho	+	+
Cr	-	-
NAA	+	+
Ala	++	- -
LL	+	+
MI	- -	++
Glx	++	- -

++ stands for elevated levels; - - stands for severely lowered; - stands for slightly lower than normal levels, + stands for normal levels.

Images :-

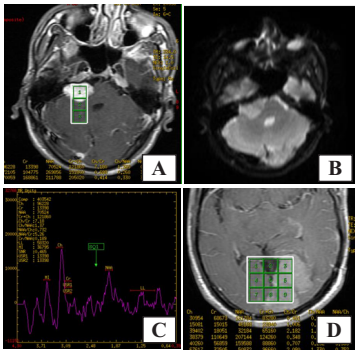

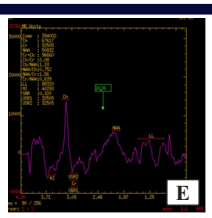

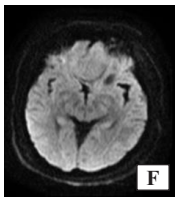

Legends :-

Schwannoma :- Figure a (T1+C)shows a well defined extraaxial round to oval intensely enhancing mass lesion in right cerebellopontine angle causing widening of internal acoustic foramen of same side. Figure b shows restricted diffusion noted on diffusion weighted imaging. Myoinositol peak elevation a seen in figure c. This was histopatho logically diagnosed as vestibular schwannoma.

Meningioma :- Figure d (T1+C))shows extraxial well defined round to oval lobulated intensely enhancing mass lesion. Figure e shows reverse peak of myoinositol signifying its depleted levels. Figure f shows another case of meningioma with no restriction on diffusion weighted imaging.

REFERENCES

1. Y.-D. Cho et al. H-MRS metabolic patterns for distinguishing between meningiomas and other brain tumours. Magnetic Resonance Imaging 21 (2003) 663-672.
2. Gill SS et al. Proton MR spectroscopy of intracranial tumors : in vivo and in vitro studies. J Computed Assisted Tomography; 1990 14:497-504.
3. Higuchi et al. Regional specific changes on n-acetylaspartate, lactate, alanine and glutamate in post globally ischaemic brain. In: Proceedings of the society of Magnetic Resonance in Medicine; 1992:547.
4. Kugel et al. Human brain tumours: spectral patterns detected with localised H-1 MR spectroscopy. Radiology 1992; 183: 701-709.
5. Kinoshita et al. Absolute concentrations of metabolites in the human brain tumours using in vitro proton magnetic resonance spectroscopy. NMR in Biomed 1997; 10: 2-12.
6. Yoshita et al. Utility of proton magnetic resonance spectroscopy in the diagnosis of human brain tumours. No Shinkei Gika 1991; 19; 421-427.
7. Yamasaki F, Kurisu K, Satoh K, et al. Apparent diffusion coefficient of human brain tumors at MR imaging. Radiology 2005;235:985–91
8. R. Nuri Sener. Diffusion Magnetic resonance imaging of solid vestibular schwannomas. Journal of Computer Assisted Tomography. 27(2): 249-252.