Volume : 5 | Issue : 7 | July 2016 • ISSN No 2277 - 8179 | IF : 3.508 | IC Value : 69.48

Role of Magnetic Resonance Spectroscopy and Apparent Diffusion Coefficient Values in the Evaluation of Brain Tumours

Medical Science

KEYWORDS : Magnetic Resonance Spectroscopy, Apparent Diffusion Coefficient, Brain tumours, Choline, Creatine, N- Acetyl Aspartate

Dr A Padmaja — Associate Professor, Department of Radio Diagnosis, NRI Medical College & General Hospital, Chinakakani, Mangalagiri Mandal, Guntur District, Andhra Pradesh, India – 522 503

Dr T Rajeswara Rao — Professor & HOD, Department of Radio Diagnosis, NRI Medical College & General Hospital, Chinakakani, Mangalagiri Mandal, Guntur District, Andhra Pradesh, India – 522 503

Dr N Saroja Ranjith — Radiologist, Narasaraopet

ABSTRACT

Purpose: To evaluate the combination of Magnetic Resonance Spectroscopy and Apparent Diffusion Coefficient values in cerebral tumours.

Materials and Methods: Magnetic Resonance Spectroscopy (MRS) and Apparent Diffusion Coefficient (ADC) values of 50 patients were studied on 1.5 Tesla GE signa excite(General Electric model system) machine by using, T2 W SSFSE, T1WFSPGGR,FLAIR and Diffusion weighted imaging before contrast. Post contrast T1 and multivoxel proton MR spectroscopy were studied after the injection of magnevist 0.2 mg/kg.

Results:In present study, most common (46%) cerebral tumour are gliomas which include low grade, high grade and glioblastoma multiforme.In the total study of 50 cases, MRS showed elevated choline peak with reduced NAA and creatine in all cases of glioma with an average Choine/N-Acetyl Aspartate (Cho/NAA), Cho/Cr(Creatine) and NAA/Cr ratios of 2.6, 2.3 and 1.2 respectively, where as NAA/Cr ratios in meningiomas are 0.8. ADC values are higher in case of gliomas in comparision with other tumours. MR spectroscopy could differentiate benign from malignant tumour, but is not useful in grading of malignant tumour. In the differentiation of malignant from benign tumours, Choline/NAA, Choline/Creatine and NAA/Cr ratios are more significant.ADC values are effective for grading malignant tumours but not for distinguishing different tumour types of same grade.

Conclusion:Combination of Magnetic Resonance Spectroscopy metabolic ratios and ADC values from tumoural core added more information to MR imaging in differentiation and grading of brain tumours.

INRODUCTION:

Conventional Magnetic Resonance (MR) imaging of brain with advanced techniques include perfusion imaging, diffusion-weighted imaging (including diffusion-tensor imaging) and MR Spectroscopy is the most commonly used imaging modality in the diagnosis, treatment planning, and post treatment surveillance of brain tumours. MR spectroscopy does not replace the conventional MRI but complements information provided by it.

Conventional MRI and MR Spectroscopy rely on the same physical principles to collect signal but differ in the way the data is processed, displayed and interrupted. Instead of images, a plot with peak amplitudes compared with a respective frequency is obtained .They generate physiologic data and information on chemical composition[(1)]. ADC has been used to distinguish the normal white matter area from necrosis, cyst formation, oedema and solid enhancing tumour [(2)].

A brain tumour is a group of abnormal cells that grows in or around the brain. Brain tumours are either malignant or benign. Brain tumours are classified based on their location, the type of tissue involved, whether the tumour is benign or malignant, and other factors. With aggressive and timely treatment, some of these can be cured.

MRspectroscopy provides a measure of brain chemistry. The most common nuclei that are used are ^{1}H (proton), ^{23}Na (sodium), ^{31}P (phosphorus). Proton spectroscopy is easier to perform and provides much higher signal-to-noise than either sodium or phosphorus. Proton MRS can be performed within 10-15 minutes.

The brain metabolites that are commonly seen on the MR spectrum are listed in Table1.

TABLE 1:Observable proton Metabolites

Ppm	Metabolite	Properties
0.9-1.4	Lipids	Products of brain destruction
1.3	Lactate	Product of anaerobic glycolysis
2.0	NAA	Neuronal marker
2.2-2.4	Glutamine / GABA	Neurotransmitters
3.0	Creatine	Energy metabolism
3.2	Choline	Cell membrane marker
3.5	Myo-ino-sitol	Glial cell marker, osmolyte hormone receptor mechanisms
1.2	Ethanol	Triplet
1.48	Alanine	Present in meningiomas
3.4&3.8	Glucose	Increased in diabetes

The spectrum represents radiofrequency signals emitted from the proton nuclei of the different metabolites into the region of interest. Specific metabolites always appear at the same frequencies, expressed as parts per million, and are represented on the horizontal axis of the graph. The vertical axis shows the heights of the metabolite peaks, represented on an arbitrary intensity scale.The study of proton magnetic resonance spectroscopy can be either qualitative or quantitative. Qualitative study results in graphs of metabolites from a given region of the brain. Quantitative study measures the real concentration of metabolites, which is proportional to the area under the peak, or the relationship of their rates with each other, through height measurement of the peaks on the graph[(3)]. The metabolite NAA is a neuronal marker and decreases with any disease that adversely affects neuronal integrity. Creatine provides a measure of energy stores. Choline is a measure of

Volume : 5 | Issue : 7 | July 2016 • ISSN No 2277 - 8179 | IF : 3.508 | IC Value : 69.48

increased cellular turn over and is elevated in tumors and inflammatory processes.

The common way to analyze clinical spectra is to look at

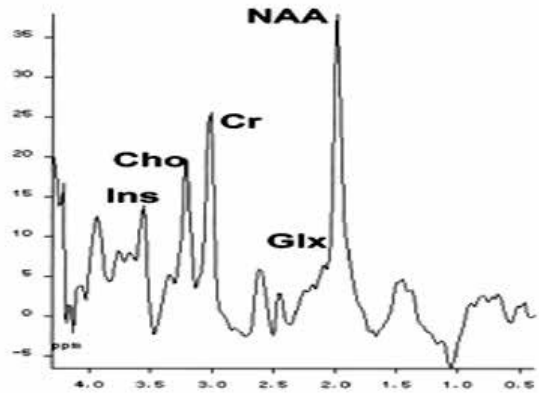

Fig1: Normal MR Spectroscopy.

metabolite ratios, namely NAA/Cr, NAA/Cho and Cho/Cr. Normal and abnormal values are shown in the table 2.

TABLE 2: Metabolite ratios.

Metabolite Ratios	Normal	Abnormal
NAA/Cr	2.0	<1.6
NAA/Cho	1.6	<1.2
Cho/Cr	1.2	>1.5

The typical proton MR spectroscopic features for primary neoplasms are elevated peaks of lipid, lactate, choline and myoinositol and reduced NAA signal. Elevated alanine is a marker for meningioma. Along with ADC, spectroscopic analysis of the peritumoral edema may help to differentiate high grade glioma from solitary cerebral metastasis[4]. The demonstration of elevated choline in peritumoral edema suggest the diagnosis of primary glioma rather than metastases. The disadvantages of MR spectroscopy are its poor spatial resolution and its occasional nonspecificity.

MRS can be used to determine the degree of malignancy. As a general rule, as malignancy increases, NAA and creatine decrease, while choline, lactate, and lipids increase. To get an accurate assessment of the tumor chemistry, the spectroscopic voxel should be placed over an enhancing region of the tumor, avoiding areas of necrosis, hemorrhage, calcification and cysts. Multivoxel spectroscopy is best to detect infiltration of malignant cells beyond the enhancing margins of tumors. Particularly in the case of cerebral glioma, elevated choline levels are frequently detected in edematous regions of the brain outside the enhancing mass. Finally, MRS can direct the surgeon to the most metabolically active part of the tumor for biopsy to obtain accurate grading of the malignancy. A common clinical problem is distinguishing tumor recurrence from radiation effects, several months following surgery and radiation therapy. Elevated choline is a marker for recurrent tumor which differentiates it from radiation necrosis

Diffusion – Weighted (DW) MR sequence is an integral component of the MRI brain protocol for tumors. Diffusion weighting enables one to distinguish rapid diffusion of protons (unrestricted diffusion) from slow diffusion of protons (restricted diffusion)[5]. Lesions that have restricted diffusion appear hyperintense on diffusion images and hypointense on the accompanying Apparent Diffusion Coefficient (ADC) maps. Using an ADC map, it is possible to quantify the diffusion in brain tissues.[6] Restricted diffusion or low ADC in the peripheral, solid component of glioma is known to correspond to higher grades, which include anaplastic astrocytoma and Glioblastoma Multiforme (GBM), whereas, low-grade fibrillary astrocytomas display increased diffusivity. Other brain tumors that characteristically display restricted diffusion are lymphoma, medulloblastoma and meningioma.

In the setting of ring enhancing lesion with perilesional edema and mass effect on CT or conventional MRI, it is often not possible to distinguish an abscess from a high grade necrotic glioma, but with ADC we can differentiate, as the centre of the abscess shows diffusion retriction where as no restriction in necrotic tumour.Thus diffusion weighted images and ADC values have reliable role in the diagnosis and grading of brain tumors.

MATERIAL & METHODS:

The study was conducted in the department of RadioDiagnosis at NRI MedicalCollege and General Hospital, Chinnakakani, Mangalagiri, Guntur, in 50 patients with intracranial space occupying lesions who were subjected for MR Spectroscopy. The duration of the study period was two years (2010 to 2012) . 50 patients with intracranial space occupying lesion found on imaging modalities like CT scan & MRI are subjected to MR spectroscopy and ADC imaging. Informed consent was obtained from all participants for MR examination and for review of patients' records and images.

Inclusion criteria:

Patients of age group 20 – 70 and of both genders, with intracranial space occupying lesions found by imaging modalities like CT scan & MRI.

Exclusion criteria:

Children age group, Patients with cardiac pace makers, Patients with metallic implants, Uncooperative patients, Relative contraindications like patients with renal insufficiency and other contraindications pertaining to MR imaging.

MR Imaging evaluation:

All participants are examined by using a 1.5 T, superconducting MR imager (GE Signa Excite) with a standard circularly polarized head coil. In each participant, axial T1 Weighted , T2 – Weighted, fast Fluid-Attenuated Inversion Recovery (FLAIR) and DW images were obtained by using 5 –mm section thickness. After intravenous administration of magnevist 0.2 mg / Kg, contrast , enhanced T1-weighted SE sequences are obtained in axial, coronal and sagittal planes.

MR spectroscopic evaluation Multi voxel MR spectroscopic data was obtained by using double – SE point-resolved spectroscopy (PRESS) localization with one pluse water signal suppression mainly from metabolite actively contrast enhanced areas , while avoiding contamination from scalp fat. The acquisition time was approximately 3.19 - 6.31 minutes. In most examinations a voxel size is of 2x2x2 cm^3. Metabolic peaks used in the differentiation of the various tumour types are as follows: Spectral peak heights of the main metabolites choline (Cho at 3.2 ppm) , creatine (Cr at 3.0 ppm), N-acetyl aspartate (NAA at 2.0 ppm), lactate

(Lac, an inverted ß – methyl doublet at 1.3ppm). Metabolite ratios of Cho/NAA, NAA/ Cr and Cho/Cr, were calculated.

MR Diffusion Imaging:
DW images were obtained by using an axial T2- weighted echo- planar SE sequence . DW images were acquired by using b values of 0, 500, and 1000s/mm . Postprocessing of ADC maps was performed by using standard software on a different work station. Standard mean ADC values were calculated automatically and expressed in 10^{-3} mm^2 /sec.

Histopathological classification:
During the surgery, total resection or multiple biopsy specimens, were obtained from each patient. Specimens were fixed in formalin and submitted for routine hematoxylin – eosin staining. After the detection of tumour type, presence of necrosis,astrogliosis, and macrophage infiltration were noted for each patient. Tumours were graded by using World Health Organization II criteria. For statistical purposes, all tumours were classified as benign or malignant and later were subdivided into low (grade 2) or high (grade 3 or 4) grade.

Results:
In this study, MRS and ADC values were analysed in 50 patients with intra cranial space occupying lesions. In our study, there was equal distribution of cases in both males and females. Maximum number of cases were in younger age group. Mean age is 40.5 years.

In the present study of 50 cases, 46% of tumours are gliomas which include low grade gliomas, high grade glioma and glioblastoma multiformae. GBM are seen in 10 cases, high grade gliomas in 10 cases and low grade gliomas in 3 cases. Meningiomas and metastases are the other tumours, that are more prevalent each accounting for 18% of the cases studied. Table 3 and 4 about here.

In present study of 50 cases all patients presented clinically are with headache and seizures. In the MRI out of 23 gliomas, 22 cases presented with single lesion and 1 patient with multiple lesions. On the evidence of MR spectroscopy and ADC values, one case diagnosed as multifocal glioblastoma multiformae but histologically it was proved as metastases. All cases of meiningiomas, non-hodgkins lymphoma, haemangioblastoma , recurrent tumours presented with single lesions, where as metastases and tumour mimicking lesions presented as multiple lesions. But one case with multiple lesions was proved histologically as oligodendroglioma .

In the present study of 50 cases of cerebral tumours, the gliomas had hyperintense signals on T2 W images and hypointense on T1W images with no diffusion restriction on diffusion weighted images. In the present study, mild to moderate enhacement was seen in all cases of gliomas. Meningiomas are isointense to hypointense in all sequences, with intense enhancement on contrast administration. In the present study, all tumour mimicking lesions cases are tuberculosis. These lesions are hyperinstense on T2 W and hypointense on other sequences with conglomerate ring enhancement. In our study, one case of haemangioblastoma which was hyperintense to isointense on T2W and hypointense on T1W with intense enhancement on intravenous contrast administration. One case of non- hodgkins lymphoma which is hyperintense on T2W and hypointense signals on T1 W images.

In the present study of 50 cases, Magnetic Resonance Spectroscopy showed elevated choline peak with reduced NAA and creatine in all cases of gliomas with an average of Cho/ NAA ratio of 2.6, Cho/ Cr of 2.3 and NAA/Cr of 1.2 , where as NAA /Cr ratios were reduced in case of meningiomas which is 0.8.

TABLE 5: Metabolic Ratios

	Choline/ Creatinine	NAA/ Creatinine	Choline/ NAA
Gliomas	2.3	1.2	2.6
Meningioma	2.27	0.8	1.9
NHL	2.2	0.9	1.13
Haemangioblastomas	1.8	0.9	1.96
Recurrence	1.98	0.6	1.3
Metastases	1.6	0.7	2.1
Tuberculosis	2.1	0.8	2

In the present study ADC values are higher in case of gliomas than the other tumours. It was found that malignant lymphomas presented with lower ADCs than those of glioblastomas and metastatic tumours. Our results suggest that preoperative measurement of the ADC may help arrive in differential diagnosis of malignant lymphoma.

TABLE 6: ADC Values

ADC Values	
Gliomas	2.98
Meningioma	1.04
NHL	8.67
Haemangioblastomas	6.57
Recurrence	1.86
Metastases	2.14
Tuberculosis	1.7

Of the total study of 50 cases undertaken, 92% of gliomas diagnosed on MRA & ADC are histologically proved. Two gliomas were diagnosed as recurrent on post-operative and post radiation imaging based on MRS & ADC and the patients in which they are diagnosed are on follow up. In metastases, 5 of them are confirmed with sensitivity of 88%. In meningioma,8 were confirmed with sensitivity rate of 96%. In tumour mimicking lesions, 4 cases are proved and 2 of them are on follow up with sensitivity of 100%. In non-hodgkin lymphoma and haemangioblastoma the sensitivity is 100%. The over all sensitivity of MRS& ADC value in the diagnosis was 96%.

TABLE 7:Correlation between Radiological and HistopathlogicalDiagnosis

Diagnosis on MR Spectroscopy & ADC Imaging	Radiological diagnosis	HP Diagnosis	Percentage
Gliomas	23	21	92 %
Gliomas on Post operative/ post-radiation follow-up	2	- Follow-up	
Metastases	8	5	88%
Meningioma	9	8	96%
Tumour mimicking lesions (Granuloma, infarct etc)	6	4 Proved 2 Follow-up	100%

Volume : 5 | Issue : 7 | July 2016 • ISSN No 2277 - 8179 | IF : 3.508 | IC Value : 69.48

Non-Hodgkin lymphoma	1	1	100%
Haemangioblastoma	1	1	100%

DISCUSSION:

Magnetic Resonance Imaging is the most useful radiological technique in evaluation of cerebral tumours. Advanced imaging techniques like MRS and DWI are helpful in differential diagnosis of brain tumours and in characterization of metabolic changes associated with tumour progression, degree of malignancy and response of treatment.[7]

Conventional MR imaging is used to characterize the lesion based on eight criteria: contrast enhancement, border definition, mass effect, signal intensity heterogeneity, haemorrhage, necrosis, degree of oedema and involvement of the corpus callosum or crossing the midline. Based on these observations most probable radiological diagnosis was proposed. All the findings mentioned above are correlated with final histopathological diagnosis and were found to be 80% sensitive and 77% specific for diagnosis, characterization of cerebral tumour and grading of glioma.

Also it was observed that the most common cerebral tumour was the Glioma group comprising 46% of total lesions. The metabolite levels are in accordance with the study of Riyadh et al[1]. Elevated choline peak with reduced NAA and creatine is noted in all cases of gliomas. Lipid and lactate peaks are observed in tuberculomas as well as in aggressive gliomas. Mean level of choline is 4.8 in malignant tumours in comparision to 2.7 in benign tumours. Similarly mean level of creatine is 1.7 in malignant tumours in comparision to 2.8 in benign tumors.

ButzenJet al showed a sensitivity of 79% and a specificity of 77% for a choline/NAA ratio of greater than 1, as an indicator of a neoplastic process[8]. In present study we found sensitivity of 74% and specificity of 72% for Choline/ NAA ratio in predicting neoplastic nature of lesion.

Decrease in NAA/Cho ratios and presence of lactate peak were the most significant MR spectroscopic parameters in the differentiation of benign from malignant tumours. A decrease in the NAA/Cho ratio is mainly due to both an increase in Cho levels and a decrease in NAA levels. NAA/Cho ratio was compared with NAA/Cr ratio and found both of them can differentiate malignant lesions from benign lesions. The NAA/Cho ratio was found to be statistically more superior to NAA/Cr ratio. This finding is in accordance with the study of Nail Bulakbasi et al.[7]

Meningiomas, theoretically, are extra axial brain tumours. Hence they do not contain NAA. But practically this observation will not be found due to voxel bleeding effect from the adjacent cerebral tissue. Lactate and alanine may also be elevated in some meningiomas. As alanine is a non essential amino acid whose function is uncertain, its peak occurs between 1.3 and 1.4 , with a possibility of being over shadowed due to the presence of lactate. Meningiomas showed MR spectrum that are indistinguishable from those of astrocytomas and did not show alanine peak, in the present study.

Burtscher et al found pathologic spectra outside the area of contrast enhancement in gliomas and lymphomas but not in nonastrocytic circumscribed tumors such as meningioma, pineocytoma, metastasis, and germinoma.[9] Also it was found that elevated choline levels are seen in the perienhancing region of glial tumors but not around metastasis. Similar results are noted in the present study.

Calculated ADC values from tumoral area were significantly higher in low-grade malignant tumors than in high-grade ones. We excluded cystic and necrotic areas and enough care was taken to sample from solid portions of the tumors. This method was also used by Nail Bulakbasietal and our values correlated well with them. Lower ADCs suggest high-grade astrocytomas, whereas higher ADCs suggest low-grade one.[7]

Krabbe et al reported that ADC values in contrast enhancing areas within cerebral metastases were significantly higher than the ADC values in contrast enhancing areas of high grade gliomas.[10] But this study found that there was no such statistically significant discrepancy between ADC values of high grade gliomas and metastasis.

Present study also has undertaken the comparision between the Cho/Cr ratio and ADC values from the enhancing tissue component of glial tumors with grading and found ADC values to be better parameter than Cho/Cr ratio in the prediction of grade of glial tumor.

Further the efficacy of advanced MRI techniques were compared with conventional MR imaging techniques in the characterization of cerebral tumors. It was found that conventional MR imaging techniques are 80% sensitive and 77 %specific in characterizing the cerebral tumors. MRimaging coupled with MRS & ADC proved to be 96% sensitive and 94% specific for characterization of cerebral tumors. Also using advanced techniques resulted in better characterisation of the cerebral tumors.

Conventional MR techniques are 80 % sensitive and 77 % specific in grading of glioma. With the addition of MRS, imaging is 96% sensitive and 94% specific for grading of glioma. With addition of ADC, imaging is 92% sensitive and 90% specific for grading of glioma.

Present study has following limitations. Compared to published series of cases the study group is relatively small. Trends in adult age group are only studied.

CONCLUSIONS:

In the present study, 50 cases of cerebral tumours were analysed by multivoxel MR spectroscopy and ADC values, MR spectroscopy showed elevated choline with reduced NAA levels in malignant tumours. Tuberculomas showed elevation of lipid and lactate levels with reduced NAA and choline. In the cases of metastases, raised choline, lipid and lactate with decreased NAA were observed. In recurrence cases, raised lipid and choline levels were encountered.

The cerebral tumours showed higher Cho/ Cr , Cho/NAA with lower NAA/Cr ratios. ADC values of cerebral tumours are helpful in distinguishing between tumour and edema . ADC values are higher in cases of gliomas than other tumours.

Although qualitative interpretation of cerebral tumours with Magnetic Resonance still remains a valuable option, in a significant number of cases this technique is unable to differentiate neoplasms from non neoplastic disorders. Magnetic Resonance Spectroscopy metabolite ratios and ADC values together add more information to Magnetic Resonance Imaging in differentiation and grading of brain tumours.

TABLE 3: Radiological Diagnosis

Diagnosis on MR Spectroscopy & ADC Imaging	No. of Patients	Percentage
Gliomas	23	46%
Gliomas on Post-operative/ post-radiotion follow-up	2	4%

Diagnosis on MR Spectroscopy & ADC Imaging	No. of Patients	Percentage
Metastases	8	16%
Meningioma	9	18%
Tumourmimickinglesions (Granuloma, infarctetc)	6	12%
Non-Hodgkin lymphoma	1	2%
Haemangioblastoma	1	2%

TABLE 4:Types of Gliomas

Glioma Types	No. of Patients
Low Grade	03
High Grade	10
GBM	10

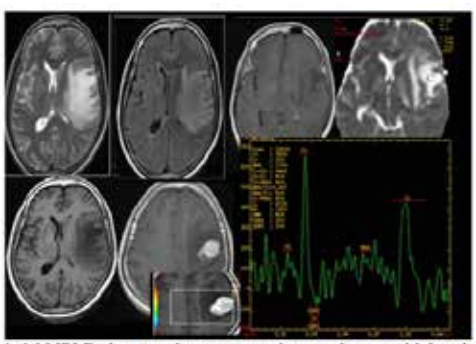

Fig 2: Axial MRI Brain pre and post contrast images shows multiple enhancing mass lesions, the lesion in the left parietal lobe showing moderate to gross perilesional oedema. MRS shows elevated choline, decreased NAA & increased lactate. Probable diagnosis given as metastases but histopathology came as oligodendroglioma(gradeII).

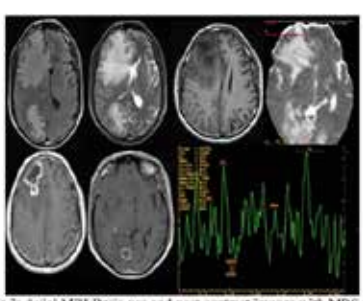

Fig 3: Axial MRI Brain pre and post contrast images with MRS shows Irregural thick walled peripherally enhancing lesions with perilesional oedema and mass effect in right frontoparietal and occipital region with mass effect. No diffusion restriction . MRS shows elevated choline and lactate levels. Radiological diagnosis - Multifocal GBM.HPE- Metastases from adenocarcinoma

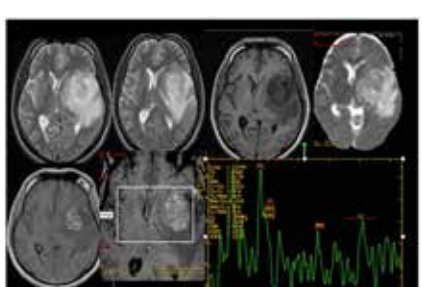

Fig 4: MRI Brain pre and post contrast images with MRS shows Heterogenously enhancing mass lesion in left temporal region with perilesional oedema and mass effect and MRS shows elevated choline, reduced NAA and lipid lactate peak - Radiological diagnosis - GBM .HPE- Gemistocytic Astrocytoma(secondary GBM)

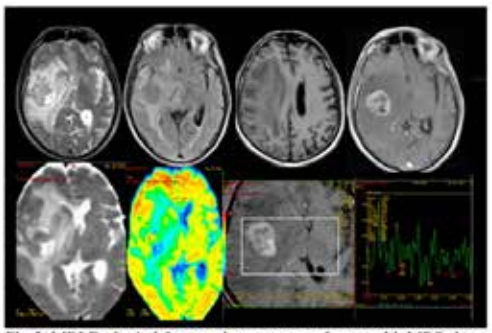

Fig 5: MRI Brain Axial pre and post contrast imges with MRS shows heterogenously enhancing mixed signal intensity mass lesion with perilesional oedema and mass effect in right temporal region .MRS shows elevated choline and reduced NAA. Radiological diagnosis - GBM.HPE - GBM

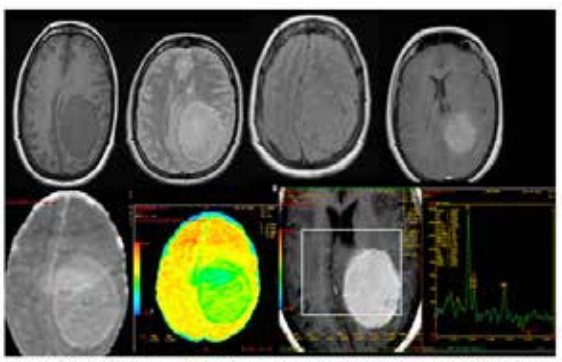

Fig 6: MRI Brain pre and post contrast axial images with MRS shows Homogenously enhancing extra axial mass lesion in left parietal region with mass effect and no diffusion restriction. Radiological diagnosis - Meningioma. MRS shows elevated choline. HPE - Meningioma.

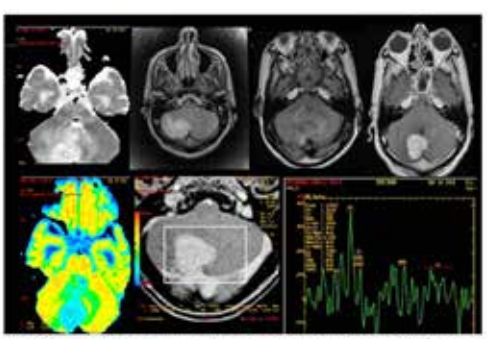

Fig 7: MRI Brain Axial pre and post contrast images with MRS shows Homogenously enhancing solid mass lesion in right cerebellar hemisphere with perilesional oedema , No diffusion restriction and MRS shows elevated choline, reduced NAA and lipid lactate peak.Radiological diagnosis- High grade glioma /haemangioblastoma. HPE - Haemangioblastoma

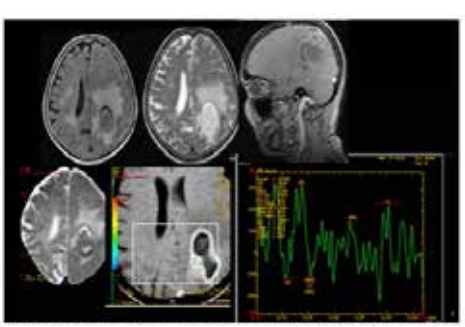

Fig 8: MRI Brain pre and post contart images with MRS showa Thick walled ring enhancing lesion with central diffusion restriction and perilesional oedema in left parieto occipital region.MRS - shows elevated lactate with minimal choline metabolite elevation .Radiological diagnosis - Abscess. HPE- Abscess.

REFERENCES:

1. Riyadh N. Al-Okaili, MD • JaroslawKrejza, MD, PhD2 • Sumei Wang, MD

Volume : 5 | Issue : 7 | July 2016 • ISSN No 2277 - 8179 | IF : 3.508 | IC Value : 69.48

● John H. Woo, MD ● Elias R. Melhem, MD, PhD Advanced MR Imaging Techniques in the diagnosis of intraaxial Brain Tumors in Adults Radiographics2006;26: S173-S189

2. James A.Brunberg, Thomas L.Chenevert, P.E.Mckeever, Donald A.Ross, Larry R.Junck, Karin M.Muraszko, Robert Dauser, James G.Pipe and A.T.Betley : In Vivo MR Determination of Water Diffusion Co efficients and Diffusion Anisotropy : Correlation with Structural Alteration in Gliomas of the Cerebral Hemispheres: AJNR Am J Neuroradiol 16:361-371 Feb, 1995.
3. Kwock L. Localized MR spectroscopy: Basic principles. Neuroimaging Clin N Am 1998;8(4):713-31.
4. EunJa Lee[1,2]Karel terBrugge[2] David Mikulis[2] DaeSeob Choi [2,3]JongMyon Bae-[4]SeonKyu Lee[5] Soon Young Moon[1] Diagnostic Value of Peritumoral Minimum Apparent Diffusion Coefficient for Differentiation of GlioblastomaMultiforme From SolitaryMetastatic Lesions American Journal of Roentgenology.2011; 196:71-76
5. Tadeusz W. Stadnik, Cristo Chaskis, Alex Michotte, Wael M. Shabana, Katrijn van Rompaey, Robert Luypaert, LubosBudinsky, Vladimir Jellus, and Michel Osteaux.Diffusion -weighted MR imaging of Intracerebral masses; Comparision with Conventional MR Imaging and Histologic Findings.AJNR Am J Neuroradiol 22:969-976,May 2001
6. Fumiyuki Yamasaki, MD, PhD Kaoru Kurisu, MD, PhD Kenichi Satoh, PhD Apparent Diffusion Coefficient of Human Brain Tumours at MR Imaging Radiology 2005;235:985-991.
7. Nail Bulakbasi,Muratkocaoglu Combination of Single - Voxel Proton MR Spectroscopy and Apparent Diffusion Coefficient Calculation in the Evaluation of Common Brain Tumours AJNR Am JNeuroradiol 23:225-233 February 2003
8. Jennifer Butzen, Robert Prost, VeerappuChetty, Kathleen Donahue, Ronald Neppl, William Bowen, Shi-Jiang Li, Victor Haughton, Leighton Mark, Thomas Kim, Wade Mueller, Glenn Meyer, HendrikusKrouwer, and Scott Rand Discrimination between Neoplastic and Non neoplastic Brain Lesions by Use of Proton MR Spectroscopy: The Limits of Accuracy with a Logistic Regression Model AJNR Am J Neuroradiol 21:1213–1219, August 2000
9. Burtscher IM, Skagerberg G, Geijer B, Englund E, Stahlberg F, Holtas S. Proton MR spectroscopy and preoperativec diagnostic accuracy: An evaluation of intracranial mass lesions characterized by stereotactic biopsy findings. AJNR Am J Neuroradiol 2000; 21:84 –93
10. Krabbe K, Gideon P, Wagn P, Hansen U, Thomsen C, Madsen F. MR diffusion imaging of human intracranial tumours. Neuroradiology 1997; 39(7):483-489