ORIGINAL RESEARCH PAPER
Volume-7 | Issue-1 | January-2018 | ISSN No 2277 - 8179 | IF : 4.176 | IC Value : 93.98
INTERNATIONAL JOURNAL OF SCIENTIFIC RESEARCH

# ROLE OF MAGNETIC RESONANCE SPECTROSCOPY IN CLASSIFYING MENINGIOMAS WITH HISTOPATHOLOGICAL CORRELATION

Radiodiagnosis

**Dr. Gaurav Mishra*** Assistant Professor, Department of Radiodiagnosis, Acharya Vinoba Bhave Rural Hospital, Sawangi (Meghe), Wardha *Corresponding Author

**Dr. Suresh Phatak** Professor and Head, Department of Radiodiagnosis, Acharya Vinoba Bhave Rural Hospital, Sawangi (Meghe), Wardha

**Dr. Deorao Kakde** Professor, Department of Radiodiagnosis, Acharya Vinoba Bhave Rural Hospital, Sawangi (Meghe), Wardha

## ABSTRACT

MRI has been used extensively in order to delineate characteristics of brain tumours till date. It has been increasingly used to decipher different properties and traits of meningiomas as well involving use of different imaging modalities such as CT, MRI and PET CT. In this original article, we are presenting our findings in MR spectroscopy in 40 cases of intracranial meningiomas attempting to aid in distinguishing benign and malignant meningiomas.

## KEYWORDS

meningioma, grading, magnetic resonance spectroscopy, magnetic resonance imaging

**Introduction** :-

Meningiomas are one of the most common brain tumours and easily diagnosed extraaxial masses as well[1,2]. But, enlightening upon specifying nature of meningioma upon imaging, it can be said that this perspective needs more studies and evidence for future applications, marking its high research potential. There have been studies involving different aspects of MRI by Hakyemez et al, Filippi CG et al, Yamasaki F et al inferring about the value of diffusion coefficients across brain tumours and grading them accordingly[3,4,5]. Magnetic resonance spectroscopy has been incorporated in same direction by Young Dae Cho et al[6]. Literature reports that increase in metabolites like Alanine and Glutamate is specific for meningiomas, whereas an increase in Myoinositol being specific for schwannomas[7,8,9,10]. The rationale of our study was to determine role of MRS in classifying meningiomas as benign or malignant with histopathological correlation.

**Material and methods** :-

A prospective study was carried out in the Department of Radiodiagnosis, Acharya Vinoba Bhave Rural Hospital, Sawangi (Meghe), Wardha over a period of 2 years. All cases with cranial meningioma were included irrespective of their age, sex and occupation and those cases who were claustrophobic, having post operative history or any metallic implants, stents, coils or pacemakers were excluded. Study approval was obtained from Institutional Ethics Committee and patients were asked to go through informed consent. 40 patients with meningiomas underwent magnetic resonance imaging on 1.5 Tesla MRI equipment (GE BRIVO MR 355). All cases were examined using magnetic resonance spectroscopy with long TE (135-144ms) and short TE (35-44ms). Voxels were placed in intratumoral and extratumoral tissues for comparison. Graphical representation of metabolites was obtained for metabolites under consideration : Choline(Cho), Creatinine (Cr), lipid-lactate(LL), myoinositol (MI), n-acetylaspartate (NAA), alanine (Ala), glutamate (Glx). Metabolite ratios were calculated were Cho/Cr, Cho/NAA, Cho/MI, Cr/MI, LL/Cr, LL/NAA and LL/MI. All meningiomas were graded according to WHO classification based upon their histopathological examination.

Statistical tests were incorporated by using SPSS software.

**Results** :-

Our study included total of 40 cases of intracranial meningioma of which, 9 were males and 31 were females. There were 28 benign and 12 malignant meningiomas confirmed on histopathological examination. Elevation of Choline was noted in all cases irrespective of their benign or malignant nature. Creatine peak was noted lower than normal in 26 meningiomas reported benign on biopsy, 2 benign cases showed normal level of creatine, whereas severe depletion of creatine was noted in all 12 malignant meningiomas. Alanine and glutamate peaks were seen in both benign and malignant cases. Malignant meningiomas showed a taller peak for glutamate. N-acetylaspartate peak was seen in 24 benign cases, while depleted levels were seen for the same metabolite in all 12 malignant cases. A decreased level of myoinositol was seen in all the cases irrespective of their benign or malignant nature. Lipid lacate peak was observed normally on benign cases whereas increased levels of same were observed in malignant cases. Presence of an elevated peak at 3.8 ppm was noted in both benign and malignant meningiomas. This peak at 3.8ppm has been observed in meningiomas, attributed to Glycine as inferred by Valeria Righi et al[12].

Mean Cho/Cr ratio was higher in malignant cases (3.375) than benign cases (1.753). Mean Cho/NAA ratio was higher in malignant cases (6.263) than benign cases (1.19). Mean Cho/MI ratio was higher in malignant cases (9.82) than benign cases (4.89). Mean Cr/MI ratio was higher in benign cases than malignant cases (2.794 > 2.487). Mean LL/Cr ratio was higher in malignant cases than benign cases. Similar patterns were noted for LL/NAA and LL/MI peaks as well. Thus, Association of NAA and LL depletion was statistically significant with malignant meningiomas($p<0.005$). Cho/Cr, Cho/NAA and Cho/MI ratios were significantly higher in malignant cases whereas Cr/MI ratio was significantly high in benign meningiomas ($p<0.005$).

**Discussion** :-

Our study reported that degree of malignancy can be identified by assessing Cho/Cr, Cho/NAA, Cho/MI, Cr/MI, LL/Cr, LL/NAA and LL/MI ratios apart from individual metabolite peaks. Higher degree of malignancy (WHO grade iii/iv) was associated with higher Cho/Cr, Cho/NAA and Cho/MI, LL/Cr, LL/NAA and LL/MI ratios and lower Cr/MI ratio. Lower NAA and Cr peaks were associated with higher grade meningiomas. Elevated Ala and Glx can be attributed specific to meningiomas. Our results were consistent with Y. D. Cho et al[6,11]. Lin VY et al had reported that degree of tumour could be predicted on the basis of Cho/Cr and Cho/NAA ratios where our study reassures the same[11]. We reported that higher degree of malignancy was also significantly associated with higher LL/NAA, LL/MI and LL/Cr ratios as well ($p<0.05$).

Increased levels of Cho indicate increased rate of cell proliferation and turnover. NAA is a marker of neuronal integrity. Cr is a marker for energy metabolism. LL are indicative of cell damage and disintegration, so not normally seen in substantial amounts on normal MRS. MI is an essential osmolyte. Thus, higher degree of malignancy can be correlated with increased cell proliferation and turnover, whereby malignant tumour cell is unable to execute energy production manifesting as increased Cho, decreased NAA and Cr. Therefore, a simultaneous increase in Cho, LL, Ala and Glx with decreased NAA, Cr, MI can be attributed towards malignant meningioma. Only ratio seen to be significantly higher in benign meningiomas was Cr/MI. Presence of an additional marker at 3.8 ppm was seen in both benign and malignant meningiomas, and for this reason, could not be used to differentiate in between the two entities. This metabolite attributable to Glycine according to Valeria Righi et al[12], which is also observed in our study.

The overall sensitivity and specificity of MRS in determining the nature of meningiomas accurately was calculated to be 90.41% and 82.79% for malignant meningiomas whereas 92.83% and 87.38% for benign meningiomas respectively. Thus, it can be inferred upon that MRS can prove to be useful adjunct in determining nature of meningiomas upon assessing carefully the metabolite peaks and metabolite ratios.

**Limitation :-**

A study with a larger sample size with double blinding will help validate and standardize the obtained results. Usage of suitable variation in TE, higher magnetic strength MRI machines (3T and above desirably in future), adjusting proper voxel size according to tumour size excluding any voxel contamination therein, properly tweaking acquisition times will help in predicting the tumoral nature and better differentiation of metabolite peaks and avoid ambiguity due to overlapping and superimposition.

**Conclusion** :-

MRS has proved to be useful in deciphering the tumours on a molecular level without any invasion. This statement itself carries weight envisioning the scope and magnitude of improvement and plethora of associated research within its perspective, especially in a developing nation like ours.

**Tables :-**

**1. Levels of metabolites observed on MRS in benign and malignant meningiomas**

| Metabolite | Benign | Malignant |
|---|---|---|
| Cho | + + | + + |
| Cr | + | - - |
| NAA | + | - - |
| Ala | + + | + + |
| LL | + | - - |
| MI | - | - - |
| Glx | + + | + + |
| Unknown marker at 3.8pm | + + | + + |
| Cho/Cr | Significantly less | + + |
| Cho/NAA | Significantly less | + + |
| Cho/MI | Significantly less | + + |
| Cr/MI | + + | - - |
| LL/Cr | Significantly less | + + |
| LL/NAA | Significantly less | + + |
| LL/MI | Significantly less | + + |

+ + stands for elevated levels; - - stands for severely lowered; - stands for slightly lower than normal levels, + stands for normal levels.

**Images :-**

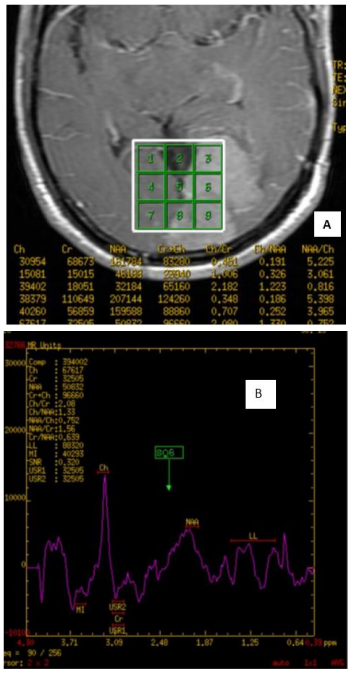


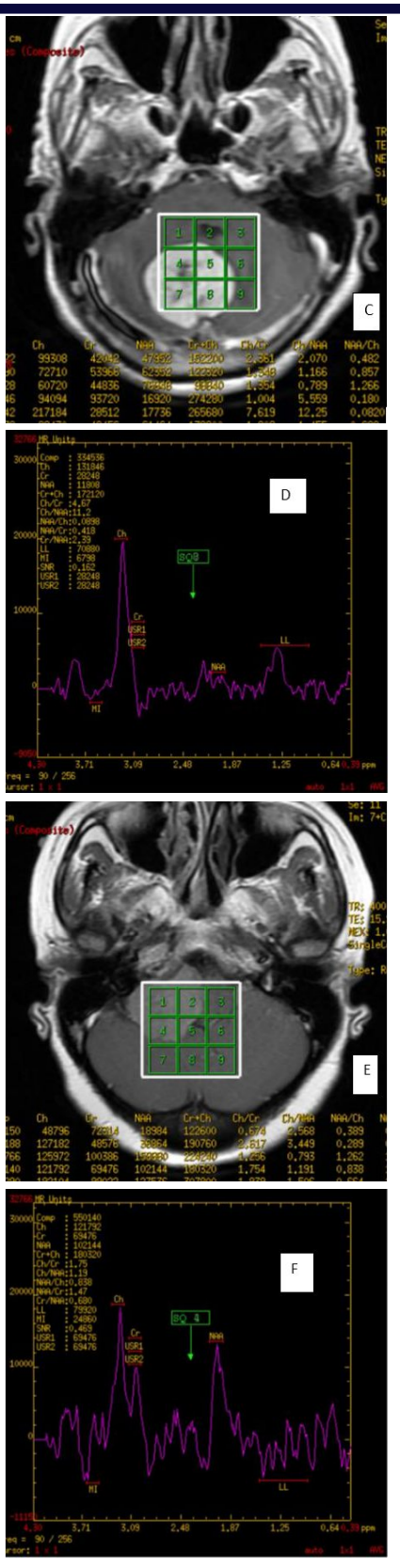


**Legends** :-

Figures A and B show the intratumorally placed voxels with graphical representation of square 6. Figures C and D show intratumorally placed voxels with graphical representation of square 8. In both, there is elevation of Choline, Lipid lactate, Alanine and Glutamate with depleted levels of myoinositol, n-acetylaspartate, creatinine. Figures E and F show normal to lower levels of n-acetylaspartate, elevated levels of choline, normal levels of creatinine, low levels of myoinositol and

lipid lactate. Alanine and glutamate peaks are seen readily. Also, at 3.8 ppm, there is elevated peak noted in all the graphic images attributable to an unknown marker – attributable to Glycine[12].

## References :-


1. Das A, Tang WY, Smith DR. Meningiomas in Singapore: demographic and biological characteristics. J Neurooncol 2000;47:153–60
2. Carpeggiani P, Crisi G, Trevisan C. MRI of intracranial meningiomas: correlations with histology and physical consistency. Neuroradiology 1993;35:532–36
3. Hakyemez B, Yildirim N, Gokalp G, et al. The contribution of diffusionweighted MR imaging to distinguishing typical from atypical meningiomas. Neuroradiology 2006;48:513–20
4. Filippi CG, Edgar MA, Ulug AM, et al. Appearance of meningiomas on diffusion-weighted images: correlating diffusion constants with histopathologic findings. AJNR Am J Neuroradiol 2001;22:65–72
5. Yamasaki F, Kurisu K, Satoh K, et al. Apparent diffusion coefficient of human brain tumors at MR imaging. Radiology 2005;235:985–91
6. Y.-D. Cho et al. H-MRS metabolic patterns for distinguishing between meningiomas and other brain tumours. Magnetic Resonance Imaging 21 (2003) 663-672.
7. Gill SS et al. Proton MR spectroscopy of intracranial tumors : in vivo and in vitro studies. J Computed Assisted Tomography; 1990 14:497-504.
8. Higuchi et al. Regional specific changes on n-acetylaspartate, lactate, alanine and glutamate in post globally ischaemic brain. In: Proceedings of the society of Magnetic Resonance in Medicine; 1992:547.
9. Kinoshita Y et al. Absolute concentrations of metabolites in the human brain tumours using in vitro magnetic resonance spectroscopy. NMR IN Biomed 1997; 10:2-12.
10. Howe FA et al. Are glutamine/glutamate levels elevated in meningiomas? MR of cancer: Physiology and metabolism in :MR of cancer: physiology and metabolism, ISMRM workshop; 1996:78.
11. Lin VY et al. Laryngoscope unilateral acoustic neuromas ; Term healing results in patients managed with fractionated stereotactic radiotherapy, Hearing preservation surgery 2005; 115; 292-6.
12. Valeria Righi et al. High resolution magic angle spinning magnetic resonance spectroscopy detects glycine as a biomarker in brain tumours. International Journal of Oncology. 36: 301-306, 2010.