ORIGINAL RESEARCH PAPER

Volume-7 | Issue-2 | February-2018 | PRINT ISSN No 2277 - 8179

INTERNATIONAL JOURNAL OF SCIENTIFIC RESEARCH

ROLE OF MDCT IN EVALUATION OF CONGENITAL PULMONARY MALFORMATIONS.

Radiodiagnosis

Dr. Dhwani Upadhya* 3rd year radiology resident, Government Medical College, Surat. *Corresponding Author

Dr. Purvi Desai Associate Professor, Department of Radiodiagnosis, Government Medical College, Surat.

Dr. Daxa Chavda Assistant Professor, Department of Radiodiagnosis, Government Medical College, Surat.

ABSTRACT

Congenital pulmonary malformations represent a wide spectrum of anomalies with a varied clinical and pathologic presentation, ranging from recurrent pulmonary infections and acute respiratory distress syndrome, which require timely drug therapy, up to large space-occupying lesions needing surgical treatment. This classification includes three anatomical and pathological entities, represented by Congenital Cystic Adenomatoid Malformation, Bronchopulmonary Sequestration and Congenital Lobar Emphysema. The final result in terms of embryological and fetal development of these alterations is a Congenital Lung Hypoplasia.

Since even Bronchial Atresia, Pulmonary Bronchogenic Cysts and Congenital Diaphragmatic Hernias are due to Pulmonary Hypoplasia, these diseases are also discussed here.

With improved resolution of foetal sonography, many of the pulmonary malformations are detected "in utero." However appropriate postnatal investigations, rather than antenatal diagnosis, are essential for surgical decision. MDCT has broadened the imaging of lung anatomy down to the subsegmental level by offering various reformation techniques, including multiplanar reconstruction, shaded-surface display (SSD), minimum-intensity projection, maximum-intensity projection, sliding thin slab imaging, volume rendering and virtual bronchoscopy . The aim of this work was to evaluate the role of MDCT in congenital anomalies of tracheobronchial tree and lungs.

SUMMARY: MDCT with its ability of reconstructive reformation is a safe and accurate diagnostic modality for congenital pulmonary malformations.

KEYWORDS

Congenital pulmonary malformations, MDCT.

METHODOLOGY:

30 patients in the age group of 0 – 5 years were included in this prospective study done over a period of 1 year.

The clinical indications for undergoing MDCT with or without angiography included lung masses detected on prenatal ultrasound or MRI examination and possible mass detected on chest radiographs obtained because of respiratory distress.

MDCT chest with I.V. contrast was done on Siemens Emotion 6 machine. MDCT angiography was added to the study if the need arose.

After MDCT examination, all patients underwent surgical resection with subsequent histopathologic confirmation of congenital lung anomalies. Final histopathologic diagnoses included congenital pulmonary airway malformation, sequestration , congenital lobar emphysema ,bronchogenic cyst and congenital diaphragmatic hernia. There were no cases of bronchial atresia, congenital segmental emphysema, or hybrid or overlapping bronchopulmonary malformation lesions.

RESULTS:

Sex distribution: Out of 30 patients, 16 were males and 14 patients were females.

Their ages ranged between 1 day and 14 years with a mean age of 6 months to 1 year.

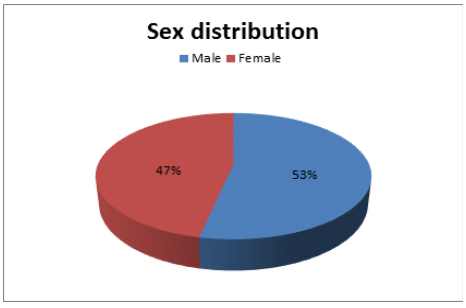

3 patients were found to have congenital cystic adenomatoid malformation (CCAM), 1 patient was found to have intralobar sequestration of lung (ILS), 2 patients were found to have congenital lobar emphysema (CLE), 1 patient was found to have bronchogenic cyst and 2 patients were found to have congenital diaphragmatic hernia. The diagnosis was confirmed by histopathologic examination.

Number of patients	30	PERCENTAGE
Patients with CPAM	3	10%
Patients with ILS	1	3.33%
Patients with bronchogenic cyst	1	3.33%
Patients with congenital lobar emphysema	2	6.66%
Patients with congenital diaphragmatic hernia	2	6.66%

DISUSSION:

Table 1: Common congenital pulmonary malformations.

	Incidence/prevalence	Features and presentation	Treatment	Comments
CPAM	Incidence is 1 per 8300 to 35,000 . No sex predilection	Usually limited to one lobe. Many cases are detected by prenatal U/S. CPAM may present in the early neonatal period with respiratory distress. 86% of patients, who were asymptomatic at birth, had become symptomatic by 13 years of age (median age 2 years). Symptoms include pneumonia with or without infected CPAM, respiratory distress, and spontaneous pneumothorax.	Surgical resection is the definitive treatment. Asymptomatic patients can be observed with serial imaging.	Lesions regress antenatally in 59%. Type 4 and type 1 tend to carry a malignancy risk.
CLE	Prevalence rate of 1 in 20,000 live births. Males > females .	The left upper lobe is affected in half of the cases. Lesions may be asymptomatic or present with respiratory distress in the newborn period. Those with the lesion may experience dyspnoea or recurring respiratory infection. 15% of cases may have congenital heart disease.	Resection of the affected lobe in symptomatic newborn. Conservative treatment in Asymptomatic patients.	Congenital cardiac anomalies often accompany CLE.

BC	Prevalence rate of 1 per 68,000	It can occur throughout the tracheobronchial tree. Large cyst presents with respiratory distress and cyanosis in newborns. BC may be detected as incidental findings on chest radiographs. Newborns with large cysts can develop respiratory distress, cyanosis, and feeding difficulty. Compression of the trachea and respiratory arrest has been reported. Wheeze, stridor, atelectasis of the distal lung, dysphagia, and recurrent pneumonia can occur.	Surgery is recommended in all cases.	Typically presented during the second decade of life.
BPS	Incident is 0.29% Male > female	Lower lobes are mostly affected. Newborn may present with respiratory distress. Patients with ELS may remain asymptomatic. Recurrent pneumonia, chest pain, hemoptysis, and shortness of breath, respectively, can occur. The adjacent lung is frequently bronchiectatic in resected ILS specimens.	Symptomatic Patients require surgical intervention. Elective resection is recommended in asymptomatic patients with ILS.	Infection, heart failure, carcinoma, and bleeding can occur in sequestrated lung.
CPAM: congenital pulmonary airway malformation, CLE: congenital lobar emphysema, BC: bronchogenic cysts, BPS: bronchopulmonary sequestration, ILS: intralobar sequestration, ELS: extralobar sequestration.				

1. CONGENITAL CYSTIC ADENOMATOID MALFORMATION

It is a congenital anomaly that occurs in 70% of cases in the first week of life, and only 10% are diagnosed after the first year of life. It consists of a mass of lung tissue, mainly derived from the bronchioles, disorganized and multicystic. It occurs more frequently in the upper lobes without, however, excluding the possible involvement of any lung segment; it is contiguous to the bronchial tree and it **is supplied by a branch ofthe pulmonary artery.** Cystic Adenomatoid Malformations are classically classified into three types, according to their characteristics and the type of cysts contained; type I, the most frequent, contains one or more cysts greater than 2 cm in diameter, air and sometimes an air-fluid level, and are able to occupy the entire hemithorax.

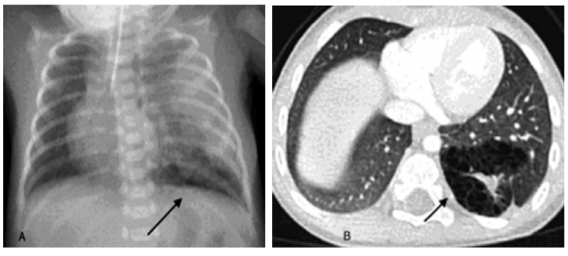

Chest Xray shows left basal soft tissue opacity with accentuated bronchovascular markings.

CT detects a malformation characterized by multiple parenchymal cysts with thin walls and band of dysplastic parenchyma.

2. LUNG SEQUESTRATION

It is a congenital anomaly characterized by a disorganized area of the lung parenchyma, devoid of pulmonary arteries and bronchial branches; however, the sequestration is supplied by branches of the thoracic or abdominal aorta. There are two forms of bronchopulmonary sequestration: intra-lobar and extra-lobar.

Intralobar variety accounts for 75 % of all sequestrations and usually presents in adolescence or adulthood as recurrent pneumonias.

Extralobar variety accounts for 25% of cases and usually presents in infancy with respiratory compromise.

In the **intra-lobar form**, the most common, the lung sequestered is located inside of the pleura of one of the lobes; it is more often found in the postero-basalsegment of the left lower lobe and in most cases is **vascularized by a branch of the descending thoracic aorta.**

At X Ray, the intra-lobar sequestration appears as a space-occupying lesion with well defined margins or as a hyperdiaphanous formation, sometimes with air and septa inside (Fig. 2-A).

With CT it is possible to observe it as a consolidation with its vascularization arising directly from the aorta or as a multicystic lesion with a mucous, fluid or air-fluid content (Fig. 2-B).

The **extra-lobar sequestration** is instead surrounded by its own pleural coating, It is more frequent in the left pulmonary basis and it is replenished from **a branch of the abdominal aorta.**

At XR and CT examinations the extra-lobar sequestration appears as a well defined and homogeneous space-occupying lesion, which does not contain air, but may contain cystic areas. The CT scan also may identify the tributary arterial branch

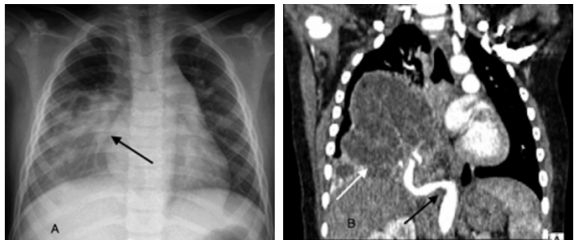

A. X Ray shows parenchymal soft tissue opacity in the middle and lower right lung field.
B. CT displays a complex expansive formation characterized by multiple septations which enhance, associated to a dorso-basal area of pulmonary consolidation replenished by an abnormal blood vessel originating from the aorta near the thoraco-abdominal transition. (black arrows)

3. CONGENITAL EMPHYSEMA

In most cases this disease is recognized during the first month of life and rarely after the second month. It is an anomaly characterized by a marked hyperinflation of a lung. This defect is often associated with congenital bronchial atresia which may be secondary to intraluminal mucosal abnormalities, ab-extrinsic compression or cartilage deficiency. In some cases, however, it does not have any association with bronchial obstructions.

It is more frequent in the left upper lobe and manifests itself with the typical symptoms of the respiratory distress syndrome .

Radiographic exams show marked hyperinsufflation and air trapping, but the involved lobe may appear radiopaque if filled with fetal lung liquid; CT: Fig. 3-B). Often loss of healthy lobes volume may be associated.

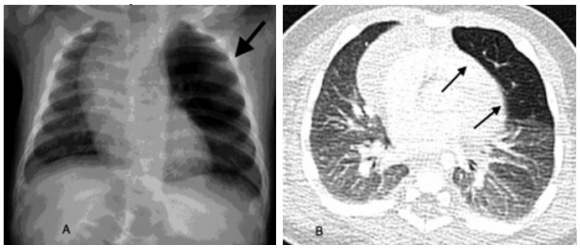

A. Xray shows a hyperlucency in the left upper lobe which displaces the contralateral upper mediastinum.
B. CT detects an increased radiolucency and distension of the left upper lobe associated with contralateral mediastinum shift.

4. CONGENITAL DIAPHRAGMATIC HERNIA

It is a congenital disease originating from anatomical defect in the proper development of the diaphragmatic muscle that occurs in about 1 in 3000 newborns, with estimated 60% mortality rate. This malformation, often associated with chromosomal deletions as Turner

syndrome or trisomy 21, can be part of a broader syndromic picture or be an isolated anomaly. The consequent herniation of abdominal contents into the chest comes at a critical time for lung development, altering the regular formation of bronchi and vessels; this condition results in a parenchymal hypoplasia with reduced surface area for gas exchange and resultant respiratory distress.

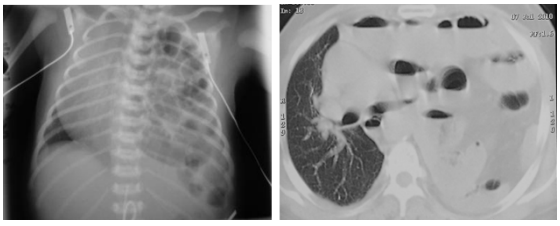

A. Chest X Ray shows fluid and gas filled bowel loops within the left thoracic cavity with resultant mediastinal shift towards right side.
B. Findings are confirmed on CT.

5. BRONCHOGENIC CYST

Bronchogenic cysts of the lung originate from the foregut, as do such cysts in the mediastinum. The foregut cysts develop within the cleavage between the respiratory tract and the digestive tube. When they form early, they are located in the mediastinum by the trachea and esophagus or close to the carina and main bronchi. When they occur later, during bronchial budding and branching, they grow within the lung parenchyma. Most bronchogenic cysts can be confidently diagnosed by using non-enhanced CT; however, administration of contrast material at CT or the addition of MRI can be useful for differentiating problematic soft-tissue-attenuation cysts with internal heterogeneity, high attenuation numbers, streak artifact or atypical location from mediastinal neoplasia. Bronchogenic cysts are more common in the lower lung lobes; in particular, the subpleural region of the lower lobe.

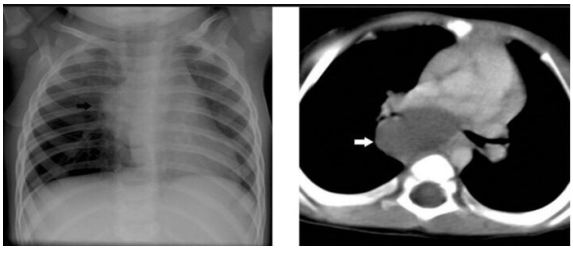

A. Chest Xray shows a soft tissue density rounded structure in right hilar region.
B. CT showed a well defined fluid density lesion in posterior mediastinum – bronchogenic cyst.

CONCLUSION:

Integrated imaging is crucial for the diagnosis of congenital pulmonary malformations; in particular, XR has proven to be highly sensitive but unspecific. CT without contrast is highly specific for the diagnosis of Congenital Lobar Emphysema, Bronchial Atresia and Congenital Diaphragmatic Hernias. CT with contrast is very accurate for the diagnosis of Bronchopulmonary Sequestration, Congenital Cystic Adenomatoid Malformation and Pulmonary Bronchogenic Cysts

References

1. Lee EY, Boiselle PM, Shamberger RC. Multidetector computed tomography and 3-dimensional imaging: preoperative evaluation of thoracic vascular and tracheobronchial anomalies and abnormalities in pediatric patients. J Pediatric Surgery 2010; 45:811–821
2. Siegel MJ. Practical CT techniques. In: Siegel MJ, ed. Pediatric body CT. Philadelphia, PA: Lippincott Williams & Wilkins, 2008:1–32.
3. Siegel MJ. Multiplanar and three-dimensional multi-detector row CT of thoracic vessels and airways in the pediatric population. Radiology 2003; 229:641–650
4. Fitch SJ, Tonkin ILD, et al. Imaging of foregut cysts. Radiographics 1986; 6: 189-201.
5. Ghaye B, Szapiro D, et al. Congenital bronchial abnormalities revisited. Radiographics 2001; 21: 105-19.
6. De Filippo M, Onniboni M, Rusca M, et al. Advantages of multidetector-row CT with multiplanar reformation in guiding percutaneous lung biopsies. Radiol Med 2008 Oct; 113(7): 945-53. doi: 10.1007/s11547-008-0325-y. Epub 2008 Sep 25.
7. De Filippo M, Saba L, Concari G, et al. Predictive factors of diagnostic accuracy of CT-guided transthoracic fine-needle aspiration for solid noncalcified, subsolid and mixed pulmonary lesions.
8. Daltro P, Fricke BL, Kuroki I, Domingues R, Donnelly LF. CT of congenital lung lesions in pediatric patients. AJR 2004; 183:1497–1506