Volume : 5 | Issue : 12 | December-2016 • ISSN No 2277 - 8179 | IF : 3.508 | IC Value : 78.46

Original Research Paper

ROLE OF MDCT IN OBSTRUCTIVE JAUNDICE

Radiology

KEYWORDS: Biliary obstruction, Multidetector CT, Magnetic Resonance Cholangio Pancreatography (MRCP), Obstructive jaundice.

Dr. Chirag Maliwad	Resident Doctor, Department of Radiodiagnosis, Smt SCL general hospital, Ahmedabad-380018
Dr. Hardik Rabari	Resident Doctor, Department of Radiodiagnosis, Smt SCL general hospital, Ahmedabad-380018
Dr. Aniket Chaudhari	Resident Doctor, Department of Radiodiagnosis, Smt SCL general hospital, Ahmedabad-380018
Dr. Dhara Saundarva	Resident Doctor, Department of Radiodiagnosis, Smt SCL general hospital, Ahmedabad-380018

ABSTRACT

The present study was carried out to find out the role of MDCT in the evaluation of obstructive jaundice with respect to cause to correlate CT findings with ultrasonography/histopathology findings as applicable. This was a prospective study conducted over period of August 2014 to October 2016. Data were collected from 90 patients with clinically suspected obstructive jaundice. Among these 56 are males and 34 are females, and majority belonged to 31-60 year age group. The major cause for obstructive jaundice was periampullary carcinoma. MDCT with reformatting techniques was very accurate in picking a mass as the cause for biliary obstruction and was able to differentiate a benign from malignant one with high accuracy. MDCT with good reformatting techniques has excellent accuracy in the evaluation obstructive jaundice with regards to level and cause of obstruction

Introduction:

Jaundice resulting from the blockage of bile flow from the liver to the intestine leading to redirection of excess bile and it's by products like bilirubin into the blood is known as obstructive jaundice. This can lead to complications such as ascending cholangitis, malabsorption and hepatorenal syndrome, thereby requiring urgent surgical intervention. The vital role of a radiologist therefore lies in the early diagnosis & in accurately identifying the level and cause of obstruction, thus helping in staging and pre-op evaluation of tumour resectability. Endoscopic Retrograde Cholangio-pancreatography is an invasive, expensive and physician centered investigation. Although Ultrasonography is a non- invasive and cost effective modality for evaluating biliary obstruction, it has a sensitivity and specificity of 55-95% and 71-96% respectively(1-2). Magnetic Resonance Cholangiography (MRCP) is considered the most reliable non-invasive technique, however it is contraindicated in patients with pacemakers and ferromagnetic implants, claustrophobic patients. It is expensive, involves long examination time and not readily available. It is also susceptible to artifacts(3-4). MDCT's ability to obtain volume dataset with sub-millimeter spatial resolution allows it to display of bile duct optimally by using Multiplanar Reconstruction (MPR) and Minimal Intensity Projection (MinIP) without compromising on image quality. The combined use of MPR and MinIP techniques significantly improves the visualization of the biliary ducts and their site of confluence compared with those obtained by axial CT(5).

Material and Methods:

This was a prospective study conducted over a period of August 2014 to October 2016 in the Dept. of Radio-Diagnosis, Smt. S C L hospital, Ahmedabad, India. Data were collected from 90 patients with clinically suspected obstructive jaundice who were evaluated with MDCT (philips 16 SLICE). CT findings were correlated with ultrasonography/histopathology findings as applicable.

Inclusion Criteria:

All patients with clinically suspected obstructive jaundice.

Exclusion criteria:

All non-obstructive cases of jaundice and Patients with obstructive jaundice but having contraindications for Computed Tomography scanning such as contrast hypersensitivity.

Data Analysis:

Collected data was analyzed for sensitivity, specificity, positive predictive value, negative predictive value, accuracy and test of significance.

Results:

Among the 90 people studied, there were 56 males and 34 females and majority of the patients were in the age group of 31-60 years. The major cause for obstructive jaundice was periampullary carcinoma. There was 100% correlation between the CT diagnosis and the final diagnosis regarding the level and type of obstruction. MDCT was able to determine the cause of obstruction with an accuracy of 100%. The sensitivity for diagnosing periampullary carcinoma was 100% and the diagnosis of choledocholithiasis gave a sensitivity of 100%.

Image 1. CASE OF CHOLELITHIASIS WITH CHOLEDOCHOLITHIASIS

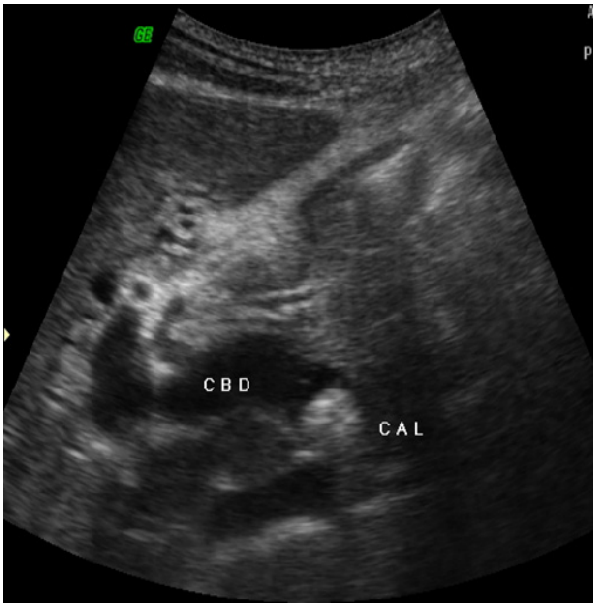

USG showing calculus at lower end of CBD.

Volume : 5 | Issue : 12 | December-2016 • ISSN No 2277 - 8179 | IF : 3.508 | IC Value : 78.46

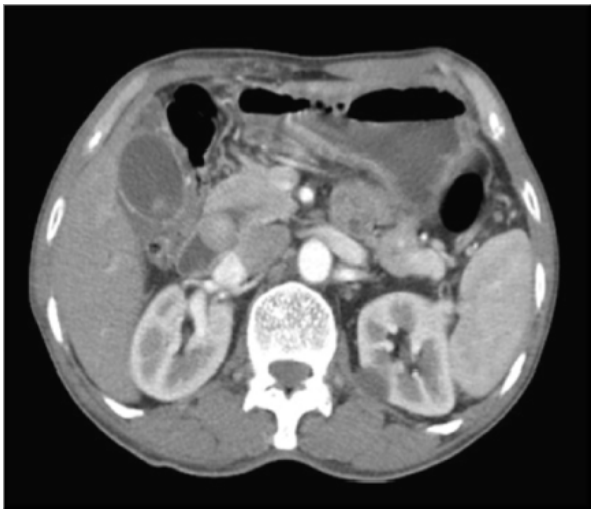

CECT showing calculus at lower end CBD and in GB

Image 2. CASE OF PERIAMPULLARY CARCINOMA



USG showing irregular marginated hypoechoic lesion in periampullary region with proximal CBD dilatation



CECT coronal scan showing lobulated peripherally enhancing lesion in periampullary region with proximal biliary dilatation

OBSERVATION

In my study, there were total 90 patients of obstructive jaundice at their initial presentation was taken. Out of 90 patients, 66 patients were suspected of having malignant biliary obstruction and 24 patients were suspected of having obstruction due to benign cause. Both group of patients were studied for different clinical and radiological features.

Table 1: Table showing diagnosis by helical CT scan and comparision with HPE diagnosis.

causes	No of patients diagnosed by MDCT	No of patients diagnosed by HPE
Benign causes	**24**	-
CBD calculi	3	3
CBD with GB calculi	9	9
Benign stricture	6	6
Anatomic variant	3	3
Cholangitis	1	1
Miscellaneous benign causes	2	2
Malignant causes	**66**	-
Periampullary ca.	28	28
Cholangio ca.	13	13
Ca GB	6	6
Ca head of pancreas	15	15
Miscellaneous malignant causes	4	4

The most common benign cause for obstructive jaundice in the evaluated patients was CBD with GB calculi (38%). The least common cause was cholangitis. Amongst miscellaneous causes there was a case of pancreatic abscess and villous adenoma of intrahepatic bile duct.

The most common malignant cause for obstructive jaundice in the evaluated patients was periampullary carcinoma (42%) followed by Ca head of pancreas (23%). Amongst the miscellaneous causes were one case each of HCC, Liver metastasis, primary colonic mass with metastatic peripotal nodes, lymphoma.

Table 2: Table showing distribution of benign and malignant causes with respect of age

Age	Benign causes		Malignant causes		Total no of Patients
	No of pt.	Percentage	No of pt	Percentage	
0-12	1	4	0	0	1
13-30	4	17	2	3	6
31-60	14	58	48	24	62
> 60	5	21	16	73	21
Total	24	100	66	100	90

Above findings suggest that benign causes of obstruction are more common in age group of 30-60 yrs which is an incidental findings and malignant causes were common after 60 years of age(73%).

Table 3: Table showing level of obstruction detected by CT scan and USG

Level of obstruction	Modality		Percentage	
	CT scan	USG	CT scan	USG
Conclusive	**86**	**62**	**100**	**72**
Inconclusive	**0**	**24**	**0**	**28**
Total	**86**	**86**	**100**	**100**

It was observed that CT scan was able to detect level of obstruction in all (100%) cases. USG was able to show the level of obstruction in only 72% cases. So CT scan is superior to USG in evaluation of level of

obstriuction.

Table 4: Table showing comparision of diagnostic values of USG and helical CT in causes of obstructive jaundice

	USG	CT
Sensitivity	75	83.33
Specificity	65	93.93
PPV	43.9	83.33
NPV	87.7	93.93
Diagnostic accuracy	67.9	88.63

DISCUSSION

Diagnosing patients with suspected biliary or pancreatic pathologies in their early stage is most important in patient care and management. Knowledge of the advantages and disadvantages of each technique are needed to determine the appropriate work up of patients with these pathologies.

In my study I have studied 90 patients suffering from various causes of obstructive jaundice.

Maximum number of patients (68.88%) were adults in the age group of 31-60yrs with majority (62%) sufferers were males.

Bilirubin level was elevated in almost all of the patients with obstructive jaundice.

USG was done in all the patients prior to Helical CT .

The level of obstruction in the biliary tree was accurately depicted by helical CT in almost all (100%) cases. USG was able to show the level of obstruction in only 72% of cases. Level of obstruction was not evaluated in some patients due to small size of the lesion and also due to bowel gas and in fatty patients. Our study is in concordance with R L Baron study done in October 1982, they found that the precise level of obstruction was identified in 82% of cases by CT scan and it was only 72% in case of USG.

USG was able to detect gall bladder calculi in all of the cases with 100% accuracy.

USG showed difficulty in picking up distal CBD calculus in 5 cases from total of 16 cases. In 31% cases it was not able to show distal CBD calculus. These were diagnosed clearly with CT with 100% accuracy. This shows that helical CT is superior to USG in detecting CBD calculi and other distal CBD pathologies. Our study is in concordance with SE Mitchell and R A clark in 1982which showed that the accuracy of CT scan in evaluating cases of choledocholithiasis was 84% and concluded that CT is superior to USG in detecting CBD stones. The study also shows concordance with D M Einstein study of april 1984 which showed that although USG is a useful modality for detecting CBD stone, it can not be used as a definitive preoperative test for CBD stones.

6 patients were diagnosed to have stricture disease. In 2 patients CT diagnosis of malignant stricture based on a findings such as rounded ending of CBD abruptly.

Histopathology examination of the resected specimen revealed benign nature of obstruction in those two cases which CT reported as malignant. This study shows that CT is not the ideal modality to assess for the nature of biliary stricture disease.

Anatomic variants of 3 cases have been diagnosed on Helical CT . One case of biliary atresia and two cases of choledochal cysts. The study showed diagnostic accuracy of 100%. Out of 3 cases USG was inconclusive in 2 cases regarding cause of obstruction. This study shows that CT is superior to USG in detection of anatomic variants.

In imaging of malignant lesions (n=66), 28 cases of periampullary growth was diagnosed with histopathological correlation. Among these 26 patients were diagnosed to have periampullary growth on Helical CT. The diagnosis was based on findings such as contrast enhancement of the lesion, nipple sign of abrupt cut off of distal end of CBD , metastasis and local infiltrative effect and double duct sign of ampullary growth. One patient was diagnosed to have stricture disease among the periampullary growth patients, due to technical fault and due to patient non-cooperation. Amongst the 28 cases of periampullary growth USG was able to show the malignant nature of the disease in 17 cases . Hence the diagnostic accuracy was 92 % with helical CT as compared to USG which was only 60 %. Our study found slightly higher diagnostic accuracy as compared to Anderrson et al 2005; In their study they found 80% accuracy for CT in diagnosing periampullary growth.

In imaging of malignant lesions (n=66), 13 cases of cholangiocarcinoma were diagnosed with histopathological correlation. Among these 11 patients were diagnosed to malignant mass lesion involving biliary system on helical CT. 2 patients were diagnosed to have hilar stricture . The diagnosis was based on findings such as contrast enhancement of the lesion, typically the delayed enhancement of contrast . The mass forming variety was easily diagnosed to have cholangiocarcinoma, the intraluminal variety was difficult to asess on CT scan and for them MRCP/ERCP were the ideal modalities. One patient diagnosed to be having hilar cholangiocarcinoma was actually proved on HPE to have villous adenoma. Hence the diagnostic accuracy was 84 % with helical CT, USG proved inferior to CT scan in diagnosing cholangioca cases. This study is in accordance with the study of Amandeep singh et al in march 2004 which showed 82% accuracy of CT in diagnosing cholangiocarcinoma.

Total 16 patients of histologically proven cases of Ca Head of pancreas were included in the study. Helical CT scan diagnosed all the cases correctly with 100% diagnostic accuracy. Calcification , nature of the lesion (cystic/solid),contrast enhancement, pancreatic duct dilatation , local invasion and metastasis were the features which were included in diagnosing carcinoma. USG was able to diagnose 14 cases as malignant in nature, our study is in accordance with the Patrick C Fanny et al study of may 1993 which showed 97% accuracy of CT scan in pancreatic carcinoma imaging. S J Hessel et al in 1982 showed 70% sensitivity of USG in diagnosing pancreatic malignancy. In our study the sensitivity of the study was around 87%. This discrepancy may be due to small sample size or late presentation of pancreatic carcinoma (when size is significantly increased to be easily visualized on USG or presented with metastasis).

Out of 66 cases of malignant biliary obstruction, 6 cases were of Ca GB. The cause of biliary obstruction was primary GB mass lesion in 2 cases, recurrent lesion in 1 case and both primary mass lesion and surrounding metastatic nodes in 3 cases. Both CT scan and USG were able to identify the GB mass with 100% diagnostic accuracy. But CT scan was better in staging of malignancy due to better assessment of vascular invasion and perilesional nodes and metastasis. Nafissa et al in their study showed diagnostic accuracy of USG of 95% in detecting GB pathology and of 100% of CT scan, our study correlates well with that study. Other studies have also found diagnostic accuracy of CT scan over 95%.

Of the miscellaneous causes one case was of hepatocellular carcinoma causing infiltration of CHD and causing proximal dilatation. This is relatively rare entity as HCC is not known to cause infiltration of bile duct.

Other case was metastasis in liver causing compression of bile ducts. A patient of primary colonic mass developed metastatic lymphadenopathy which caused obstruction of upper CBD with proximal dilatation.

One case was of lymphoma with nodal mass at the level of ampulla

Volume : 5 | Issue : 12 | December-2016 • ISSN No 2277 - 8179 | IF : 3.508 | IC Value : 78.46

causing compression of distal CBD with proximal dilatation.

In all the miscellaneous causes CT was better in evaluation of the level and cause of obstruction as compared to USG.

CONCLUSION

During our study we found that helical CT scan is having higher sensitivity, specificity, PPV and diagnostic accuracy as compared to USG and is clearly a better imaging modality as compared to USG.

CT scan shows better demonstration of calculi in lower CBD as compared to USG and is a better modality for cholelithiasis.

CT scan shows better anatomical detail than USG in demonstrating anatomical variants.

CT scan depicts level of obstruction and cause of obstruction better than USG.

Helical CT scan is a better modality than USG in evaluation of malignant causes because of better assessment of size and extent of the lesion, better anatomic visibility, better assessment of invasiveness, staging of tumor.

Acknowledgement:

The scientific guarantor of this publication is associate professor Dr. Gurudatt Thakkar & head of department Dr. Viplav Gandhi. The authors of this manuscript declare no relationships with any companies whose products or services may be related to the subject matter of the article. The authors state that this work has not received any funding. Statistical methods were necessary for this paper. Written informed consent was obtained when possible. No study objects or cohorts have been previously reported (in previous publications).

BIBLIOGRAPHY

1. Lalani T, Corey AC, Max PR, Mark EB, et al: ACR appropriateness criteria on jaundice. American College of Radiology 2012. 2.
2. Guibaud L, Bret PM, Reinhold C, Atri M, Barkun AN. Diagnosis of choledocholithiasis: value of MR cholangiography. AJR Am J Roentgenol. 1994 Oct; 163(4):847-50. 3.
3. David V, Reinhold C, Hochman M, Chuttani R, McKee J, Waxman I, Wang L, Li W, Kaplan R, Edelman RR. Pitfalls in the interpretation of MR cholangiopancreatography. AJR Am J Roentgenol. 1998 Apr;170(4):1055-9. 4.
4. Moore KL and TVN Persaud: The Developing Human - Clinically Oriented Embryology, 7th ed. Elsevier Science (WB Saunders), Philadelphia (2003), p. 78. 5.
5. Ferrari FS, Fantozzi F, Tasciotti L, Vigni F, Scotto F, Frasci P. US, MRCP, CCT and ERCP: a comparative study in 131 patients with suspected biliary obstruction. Med Sci Monit. 2005 Mar;11(3):MT8-18.
6. Robert et al. Normal Intrahepatic Bile Ducts CT Depiction. Radiology1990;176:633-635.
7. CT and MR Imaging of the Whole Body, Fourth Edition, Volume Two;1341-1486.
8. Koichi Hirao et al. Evaluation of Aberrant Bile Ducts before Laparoscopic Cholecystectomy. AJR 2000;175:713-720.
9. Todani T, WAtanable T, Narusue M, et al. Congenital bile duct cysts Classification, operative procedures and review of 37 cases, AM J. Surg.1997.72.
10. Joseph K.T. Lee, Stuart S. Sagel, et al. Computed Body Tomography with MRI correlation, 3rd edition, volume 2, Philadelphia, 1998.
11. Taylor KJW, Rosenfield AT, de Graaff CS. Anatomy and pathology of the biliary tree as demonstrated by ultrasound. Clinics in Diagnostic Ultrasound 1979; 1:103-21.
12. Majoie CB, Smits NJ, Phoa SS, Reeders JW, Jansen PL. Primary sclerosing cholangitis : sonographic findings. Abdom Imag 1995; 20: 109-12
13. Malini S, Sabel J. Ultrasonography in obstructive jaundice. Radiology 1977; 123:429-33.
14. Baron R L, Stanley RJ, Lee JKT, Koehler RE, Melson GE, Balfe DM et al. A prospective comparison of the evaluation of biliary obstruction using computed tomography and ultrasonography. Radiology 1982; 145: 91-8.
15. Khandelwal KC, Merchant NH, Udani RJ, Joshi MS, Parikh VP, G Pradipkumar et al. Role of ultrasonography in obstructive jaundice. Ind J Radiol Imag 1991; 1: 17-20.
16. Zagoni T, Benko Z, Telegdy L, Antony A, Keleti G, Peter Z. Diagnostic value of abdominal ultasonography and endoscopic retrograde cholangiopamcreatography in obstructive jaundice. Orv Hetil 1995; 136 (28): 1483-6.
17. Kumar M, Prashad R, Kumar A, Sharma R, Acharya SK, Chattopadhyay TK. Relative merits of ultrasonography, computed tomography and cholangiography in patients of surgical obstructive jaundice. Hepatogastroenterology 1998; 45(24): 2027-32.
18. Baron RL. Common bile duct stones: re-assessment of criteria for CT diagnosis. Radiology 1987; 162: 419-24.
19. Jeffrey RB Jr, Federle MP, Laing FC, Wall S, Rego J, Moss AA. Computed tomography of choledocholithiasis. AJR 1983; 140: 1179-83.
20. Pedrosa CS, Casanova R, Lezana AH, Fernandez MC. Computed tomography in obstructive jaundice. Part II: The cause of obstruction. Radiology 1981;139:635-