ORIGINAL RESEARCH PAPER

Volume-8 | Issue-1 | January-2019 | PRINT ISSN No 2277 - 8179

INTERNATIONAL JOURNAL OF SCIENTIFIC RESEARCH

ROLE OF RADIOLOGICAL IMAGING IN THE DIAGNOSIS OF PULMONARY HYPERTENSION

Medicine

Ravi Bhaskar Associate professor, department of pulmonary medicine, career institute of medical sciences, Lucknow, Uttar Pradesh, India.

Seema Singh* Research Scholar, Department of Respiratory Medicine, King Georges Medical University, Lucknow, Uttar Pradesh, India. *Corresponding Author

Pooja Singh Research Officer, Department of pulmonary medicine, career institute of medical sciences, Lucknow, Uttar Pradesh, India.

Mohd Tariq junior resident, Department of Respiratory Medicine, King Georges Medical University, Lucknow, India.

Arvind K Suman Senior Resident, Department of General Surgery, King Georges Medical University, Lucknow, India.

ABSTRACT

Pulmonary hypertension is a disorder of pulmonary arteries leading to high resistance and low compliance vascular nature, mostly by cardiovascular disorders and the second leading cause is chronic respiratory disorders contributing nearly 10% of total cases of pulmonary hypertension. The most common chronic respiratory disorders causing pulmonary hypertension is chronic obstructive pulmonary disorders, interstitial lung diseases, sleep-related breathing disorders and as a post tubercular complications. Most commonly the PH associated with chronic respiratory disorders are mild to moderate degree. PH leading to progressive right heart failure is associated with poor prognosis, frequent exacerbations of respiratory symptoms and low health-related quality of life. Right heart catheterization remains the gold standard for evaluation of pulmonary hypertension. The pitfalls of RHC like lack of proper standardization of technique, associated complications and lack of skill full hands in poor resource countries leading to a non-invasive way of evaluation of PH and prediction of prognosis like clinical evaluation, serology, radiological imaging and 2D echocardiography. The goal of this study is to use the radiological imaging to diagnose pulmonary hypertension and manage accordingly. Analysis of this study results shows radiological imaging plays an essential role in the diagnosis and management of suspected pulmonary hypertension.

KEYWORDS

radiological imaging, diagnosis, pulmonary hypertension,

Introduction

Pulmonary hypertension (PH) is a progressive, life-threatening, pulmonary vascular condition with a wide array of etiologies and comorbidities. (1,2). Pulmonary hypertension is a pathophysiological condition and associated hemodynamic changes in the pulmonary vasculature with an increased mean pulmonary arterial pressure of ≥25mmHg at rest as assessed by RHC (3). The following chest radiographic findings may indicate the presence of pulmonary hypertension: enlargement of the right and left main pulmonary arteries; hilar enlargement; tapering or pruning of peripheral pulmonary arteries; enlargement of the right interlobar artery (greater than 15-mm diameter on a postero anterior frontal radiograph); right atrial and right ventricular enlargement; and areas of oligemia, which appear as increased lucency and decreased vascularity (4). Pulmonary venous pressure can be measured as pulmonary capillary wedge pressure (PCWP), which reflects left atrial pressure and left ventricular diastolic filling pressure. PCWP can be estimated by observing the vascular pattern and the presence of interstitial or alveolar edema on chest radiographs. It has been suggested that PCWP greater than 13 but less than 18 mm Hg indicates the presence of vascular redistribution with relative hypervascularity of the upper lung fields; 18–25 mm Hg, interstitial pulmonary edema; and greater than 25 mm Hg, alveolar edema and, often, pleural effusions. If pulmonary hypertension is present in these clinical situations, strong consideration should be given to left ventricular failure as a causal factor (5-6). Despite the fact that a lot of conditions leading to pulmonary hypertension, the chronic respiratory disorders are the second major contributors and related morbidity and mortality. Chronic obstructive pulmonary disease and diffuse parenchymal lung disorders, post tubercular complications like fibro-cavitary lung diseases and/or amyloidosis of lung and sleep-related disorders of breathing are important respiratory disorders causing hypoxia-induced changes and/or fibrosis causing changes in the physiological parameters of pulmonary vasculature leading to changes in the pulmonary (7-8). Failure of recognition of pulmonary hypertension in patients with respiratory disorders linked to the overlapping of symptoms, late decade presentation as they ignoring the symptoms as part and parcel of the ageing process and associated cardiovascular diseases prevalence in developing countries as a part of westernization and urbanization. Combined negligence of Clinician and patient from early recognition of pulmonary hypertension leading to increased morbidity and mortality and low health-related quality of life.

The confirmative diagnosis and grading of pulmonary hypertension require the invasive Right Heart Catheterization. It is used less commonly in India due to the cost and complications of the procedure, and non-availability of infrastructure and technically skilled personnel in developing worlds. Now a day's several non-invasive diagnostic methods used for the evaluation of PH including clinical assessment, serological tests, radiological imaging modalities and 2D echocardiography.

Methods

In this study, the patients with chronic respiratory disorders were selected and screened for pulmonary hypertension clinically and the suspected one was evaluated with radiological imaging modalities like chest X-ray and CECT/HRCT Thorax and confirmation and grading of the PH was done with 2D echocardiography. Universal availability and cost-effectiveness of the chest X-ray and CECT/HRCT thorax gives easy and early assessment of the PH.

Study populations

Total 26 patients with chronic respiratory disorders having clinical suspicions of pulmonary hypertension were enrolled and evaluated for PH. out of 26 patients, 19 patients were demonstrated to have likely PH, 3 patients have possible PH and 4 patients have unlikely PH, as defined by mPAP at 2D Echocardiography ≥25mmHg. The mPAP ranged from >25mmHg, 20-24mmHg and < 19mmHg in patients with like the ly PH, possible PH and unlikely PH respectively

Statistical analysis

SPSS software was used to assess statistical analysis. p Values <0.05 were considered significant. Results were expressed as mean with SD. Comparisons were performed by using Student t-tests and to compare the categorical data Chi-square test was used. Univariate correlations were assessed using the Pearson product-moment coefficients. Identification of the strength of the association between mPAP and other variables was assessed using forward stepwise multiple

regression analyses. To predict pulmonary hypertension, a combining two to three variables, best correlated to mPAP, the higher value indicating a higher risk of PH.

Results:

Chest radiography

Chest X-ray may suggest the presence of pulmonary hypertension with variable sensitivity and specificity. At the time of clinical suspicion of pulmonary hypertension, about 85-90% of patients have abnormal chest radiography. The major radiological features suggestive of PH include enlargement of the right and left main pulmonary arteries, tapering or pruning of peripheral pulmonary arteries, right atrial and ventricular enlargement, increased translucency, decreased vascularity and elevated cardiac apex due to right ventricular hypertrophy with features suggestive of chronic respiratory diseases includes reticulonodular pattern and honeycombing in DPLD, hyperinflation, flattening of diaphragm and tubular heart in COPD and destroyed lung (fibro-cavitary lesions) in post tubercular complications also expected to be present with corpulmonale.

CECT/HRCT THORAX

This is the most effective radiological imaging tool at present for the assessment of lung parenchyma, cardiac pathology and extracardiac vascular pathology. The classical features that highly suggestive of pulmonary hypertension includes for example the parenchymal features are mosaic pattern, centrilobular nodules and neovascularity, the cardiac features are right ventricular hypertrophy(wall thickness >4mm), straightening or bowing of interventricular septum, RV/LV ratio more than 1 (at the midventricular level on axial images), dilation of inferior vena cava (≥21mm) and pericardial effusion and the extracardiac vascular features are enlarged pulmonary artery trunk (>29mm), main pulmonary artery and ascending aorta ratio (PA/Ao) ≥ 1 and segmental artery to bronchial diameter ≥ 1 in three or four lobes in the presence of dilated pulmonary artery. These features have the diagnostic specificity of 100% in pulmonary hypertension.

2D echocardiography

This non invasive and non radiation hazard method plays a critical role in the semi quantitative evaluation of cardiac anatomy and function and pulmonary hypertension and grading complimenting chest X-ray and CT thorax. 2D echocardiograph parameters that suggestive of pulmonary hypertension includes RV hypertrophy (RV wall thickness > 5mm from the subcostal view), RV dilation (diameter > 42mm at the base, >35 mm at the midlevel, >86mm at longitudinal), RA dilation (area > 18 cm^2, minor-axis dimensions >44 mm, major-axis dimensions > 53 mm), RVOT dilation (PSAX distal diameter > 27 mm at end-diastole), systolic flattening of the inter ventricular septum, LV eccentricity index (>1 in systole 6 diastole),pericardial effusion, SPAP = 4 x TRV^2 + RAP (TRV > 2.8–2.9 msec : SPAP 36 mm Hg),RAP = IVC size and collapsibility (>2.1 cm, collapse < 50%: RAP 15 mm Hg),MPAP = 0.61 x SPAP + 2mmHg and PVR = TRV/TVI_{RVOT} (cm) x 10+ 0.16 (>0.2: PVR > 2 WU; <0.15: normal PVR).2D echocardiography features of Impaired RV systolic function includes TAPSE (<16 mm), Tei index: (IVRT + IVCT)/ET (>0.40 by PW Doppler; >0.55 by DTI) and RV FAC (<35%).

DTI, Doppler tissue imaging; SPAP, systolic pulmonary artery pressure; FAC, fractional area change; IVC, inferior vena cava; RVOT, RV outflow tract; TAPSE, tricuspid annular plane systolic excursion (M-mode echocardiography); TVI, time-velocity integral; TRV, tricuspid regurgitation velocity; MPAP, mean pulmonary artery pressure; WU, woods unit; PVR, pulmonary vascular resistance; RAP, right atrial pressure.

Association between mPAP and radiological parameters of chest X-ray and CECT/HRCT thorax were assessed in patients with clinically suspected PH patients of chronic respiratory disorders. In the chest X-ray evaluation of RA/RV enlargement, Right descending pulmonary artery diameter (>16mm) and pruning have a sensitivity of 82%, 77% and 66% respectively and have a specificity of 50% and positive predictive value of 90%. This suggests that the most reliable chest x-ray feature is RA/RV enlargement with 76.9% validity and 33% of negative predictive value. CT thorax features of PA/A ratio ≥1.0, Enlargement of main pulmonary artery ≥ 29mm, RV wall thickness ≥4mm, IVC enlargement ≥21mm, Mosaic pattern, Centrilobular nodules and Pericardial effusion have sensitivity of 95.5%, 90.9%,90.9%,81.8%,50%,36.4% respectively and 9.1% and have specificity of 0-100%. The most reliable CT thorax feature is the main pulmonary artery and aortic artery ratio ≥1.

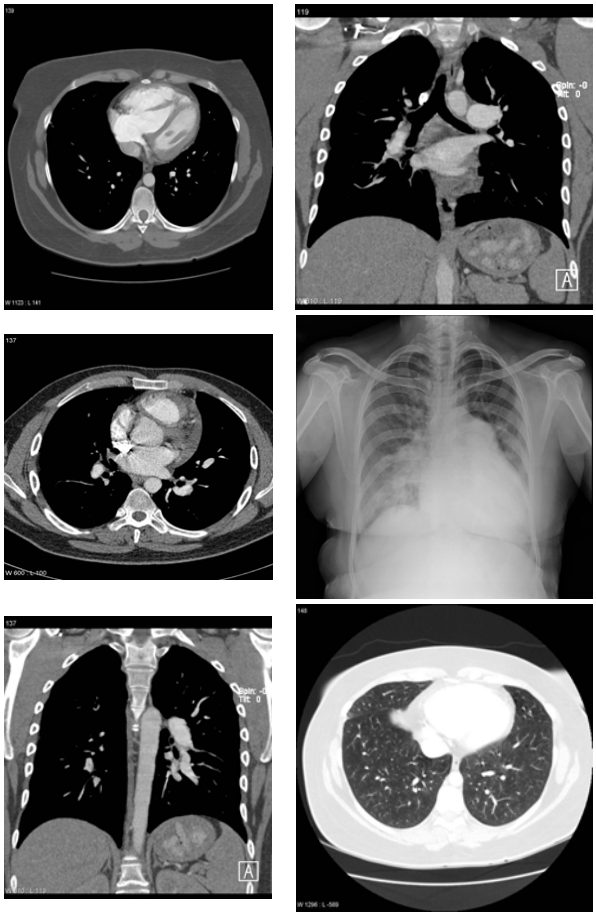

Fig. 1—52-year-old woman with chronic dyspnea and smoking history. **A** and **B,** Posteroanterior (**A**) and lateral (**B**) chest radiographs show hyperinflation of lungs and enlargement of central pulmonary arteries, representing pulmonary hypertension secondary to chronic obstructive

Table no: 1

S. No.	Chest Parameters	Sensitivity	Specificity	PPV	NPV	Validity	kappa	P value
1	Chest X ray Right descending pulmonary artery diameter ≥ 16mm	77.3 %	50%	89.5 %	28.6%	73.07	9.3%	0.258
2	Chest X ray Pruning	66.6 %	0%	77.8 %	0%	53.84	11.4%	0.14
3	Chest X RA/RV enlargement	81.8 %	50%	90%	33.3%	76.9	11.9%	0.16
S. No.	**CT thorax parameters**	**Sensitivity**	**Specificity**	**PPV**	**NPV**	**Validity**	**kappa**	**P value**
1	Ct thorax Enlargement of main pulmonary artery ≥ 29mm	90.9 %	25%	87%	33.3%	80.7	8.2%	0.36
2	Ct thorax Pericardial effusion	9.1%	100%	100 %	16.7%	23.07	1.3%	0.53
3	Ct thorax Rv wall thickness ≥4mm	90.9 %	50%	90.9 %	50%	84.6	18.8 %	0.03

4	Ct thorax IVC enlargement ≥21mm	81.8 %	100%	100 %	50%	84.6	25.7 %	0.00 1
5	Ct thorax Mosaic pattern	50%	75%	91.7 %	21.4%	53.8	5.3%	0.35
6	Ct thorax Centrilobular nodules	36.4 %	75%	88.9 %	17.6%		2.1%	0.66
7	Ct thorax PA/A ratio ≥1.0	95.5 %	0%	84.0 %	0%	80.7	3.2%	0.66

Discussion

As a whole of this study demonstrates pulmonary hypertension can be predicted in chronic respiratory disorders by using a CT thorax and chest X-ray. The PA/Ao ratio, enlargement of main pulmonary artery ≥29 mm and right descending pulmonary artery diameter >16mm were the three best-correlated parameters with mPAP and pulmonary hypertension. Right and left ventricular function can be quantitatively assessed with ECG-gated chest CT. The distensibility of the right pulmonary artery has the strongest correlation with mean pulmonary arterial pressure (8). It is superior to right ventricular outflow tract wall thickness and systolic diameter, indicating that functional measurements obtained with ECG-gated chest CT add value to anatomic assessment of pulmonary arterial calibre in the diagnosis and management of pulmonary hypertension. CT has long been shown to provide valuable clues by allowing non-invasive and quantitative assessment of structural alterations from bronchi, lung parenchyma, mediastinal vessels and cardiac features. Pulmonary hypertension is a complex, clinically relevant condition that causes substantial morbidity and mortality if undiagnosed and untreated (9). Several clinical entities converge into one of multiple pathobiologic pathways that lead to pulmonary hypertension and right-heart dysfunction, as delineated by the current classification schemes. Because of the increasing availability of effective therapies tailored to the specific mechanism leading to pulmonary hypertension, early and accurate etiologic diagnosis is paramount. In this scenario, imaging, particularly noninvasive imaging, plays a central role in the diagnosis and management of this challenging condition.Another approach involves measurement of pulmonary circulation time, which is usually prolonged in pulmonary hypertension. A study in which the subjects were 18 patients with combined pulmonary fibrosis and emphysema involved calculation of mean transit time through the pulmonary artery with MR angiography (10). the result was correlated with mean pulmonary arterial pressure as measured by right-heart catheterization, and correlation of 0.71 was found ($p < 0.001$).Right ventricular catheterization remains the reference standard for diagnostic confirmation. (11). Chest radiography and echocardiography are the cornerstones of initial assessment of suspected pulmonary hypertension. Chest CT and, increasingly, MRI are advanced non-invasive modalities that with minimum patient risk yield crucial detailed information on the pulmonary parenchyma, cardiac anatomy and function, and the status of the pulmonary vasculature. They are useful not only for precise etiologic diagnosis but also for effective treatment of patients with pulmonary hypertension (12).

Chest CT and, increasingly, MRI are advanced noninvasive modalities that with minimum patient risk yield crucial detailed information on the pulmonary parenchyma, cardiac anatomy and function, and the status of the pulmonary vasculature. They are useful not only for precise etiologic diagnosis but also for effective treatment of patients with pulmonary hypertension.

Conclusion

CT measurements of PA/Ao ratio is a distinct phenotype in patients with chronic respiratory disorders with severe PH and combined with main pulmonary artery diameter and right descending pulmonary artery diameter which may offer a better non-invasive tool for diagnosis of pulmonary hypertension in resource-poor settings.

REFERENCES

1. Simonneau G, Gatzoulis MA, Adatia I, Celermajer D, Denton C, Ghofrani A. Updated clinical classification of pulmonary hypertension. J Am Coll Cardiol. 2013;62(25 Suppl):D34–41. [PubMed: 24355639]
2. Barst RJ, Gibbs JS, Ghofrani HA, et al. Updated evidence-based treatment algorithm in pulmonary arterial hypertension. J Am Coll Cardiol 2009; 54(suppl):S78–S84
3. Galiè N, Humbert M, Vachiery JL, Gibbs S, Lang I, Torbicki A. 2015 ESC/ERS Guidelines for the diagnosis and treatment of pulmonary hypertension: The Joint Task Force for the Diagnosis and Treatment of Pulmonary Hypertension of the European Society of Cardiology (ESC) and the European Respiratory Society (ERS): Endorsed by: Association for European Paediatric and Congenital Cardiology (AEPC), International Society for Heart and Lung Transplantation (ISHLT) Eur Heart J. 2016;37:67–119. [PubMed: 26320113]
4. Badesch DB, Abman SH, Simonneau G, Rubin LJ, McLaughlin VV. Medical therapy for pulmonary arterial hypertension: updated ACCP evidence-based clinical practice guidelines. Chest 2007; 131:1917–1928
5. Fleischner FG. Pulmonary embolism. Clin Radiol 1962; 13:169–182
6. Simon M, Sasahara AA, Cannilla JE. The radiology of pulmonary hypertension. Semin Roentgenol 1967; 2:368–388
7. Milne EN. Physiological interpretation of the plain radiograph in mitral stenosis, including a review of criteria for the radiological estimation of pulmonary arterial and venous pressures. Br J Radiol 1963; 36:902–913
8. 8. Revel MP, Faivre JB, Remy-Jardin M, et al. Pulmonaryhypertension: ECG-gated 64-sectionCT angiographic evaluation of new functionalparameters as diagnostic criteria. Radiology2009; 250:558–566
9. Hoeper MM, Bogaard HJ, Condliffe R, Frantz R, Khanna D, Kurzyna M. Definitions and diagnosis of pulmonary hypertension. J Am Coll Cardiol. 2013;62(25 Suppl):D42–50. [PubMed: 24355641]
10. Sergiacomi G, Bolacchi F, Cadioli M, et al.Combined pulmonary fibrosis and emphysema:3D time-resolved MR angiographic evaluationof pulmonary arterial mean transit time andtime to peak enhancement. Radiology 2010;254:601–608
11. Zisman DA, Karlamangla AS, Ross DJ. High-resolution chest CT findings do not predict the presence of pulmonary hypertension in advanced idiopathic pulmonary fibrosis. Chest 2007; 132:773–779
12. Alhamad EH, Al-Boukai AA, Al-Kassimi FA. Prediction of pulmonary hypertension in patients with or without interstitial lung disease: reliability of CT findings. Radiology 2011; 260:875–883