ORIGINAL RESEARCH PAPER

Volume-8 | Issue-1 | January-2019 | PRINT ISSN No 2277 - 8179

INTERNATIONAL JOURNAL OF SCIENTIFIC RESEARCH

ROLE OF ULTRASONOGRAPHY AND MULTIDETECTOR SPIRAL CT IN DIAGNOSIS OF RENAL INFLAMMATORY DISEASES.

Radiodiagnosis

Dr. Rupinder Singh Associate Professor, Department of Radiodiagnosis and Imaging, M.M. Institute of Medical Sciences and Research, Mullana, Ambala.

Dr. Japujit Resident, Department of Radiodiagnosis and Imaging, M.M. Institute of Medical Sciences and Research, Mullana, Ambala

Dr. Avkirat Senior Resident, Department of Radiodiagnosis and Imaging, M.M. Institute of Medical Sciences and Research, Mullana, Ambala.

Dr. Amit Mittal* Professor, Department of Radiodiagnosis and Imaging, M.M. Institute of Medical Sciences and Research, Mullana, Ambala. *Corresponding Author

ABSTRACT

Background: Acute renal infections are usually diagnosed based on clinical conditions and laboratory data without imaging examinations. Thus, imaging is not indicated in uncomplicated renal infections, however in patients with severe symptoms and at high risk especially those with immunocompromised state, diabetes mellitus and antibiotic non-responders; imaging becomes important. [1].Ultrasonography (USG) is the earliest screening modality and is used for guiding interventions as well and CT is the gold standard for diagnosis and management of severity of pyelonephritis and its complications.

Aim: The purpose of this study was to evaluate the role of USG and MDCT in renal inflammatory diseases and to correlate USG and MDCT findings with one another and to compare with clinical outcome and laboratory results

Sample size: 50 patients with renal infection. In all patients USG and CT were done.

Results: In our study USG was able to correctly detect 76% cases of renal infections and CT was able to detect 94% cases correctly. Among these 40% were diagnosed as APN, 20% as EPN ,and 30% as pyonephrosis. 2 cases of each renal abscess and renal tuberculosis were diagnosed. 1 case of XGP was also found in our study.

Conclusion: MDCT has high sensitivity and specificity and is the mainstay for diagnosing renal infections. However , USG forms an excellent screening tool for evaluation in emergency setting.

KEYWORDS

Renal infection, pyelonephrits, USG, CT.

Introduction:

Renal infections range from mild to severe, acute to chronic and they may also be associated with various risk factors such as most commonly diabetes mellitus, leukemia, staghorn calculi and vesico-ureteric reflux [1]. Acute infections include acute pyelonephritis that can be either focal or diffuse and may also resolve with time and can also lead to abscess formation depending upon the management given and immune status of the patient. The anatomic structure of the urinary tract—an epithelium-lined tube with an opening at the body's surface—makes this organ system susceptible to both symptomatic and asymptomatic colonization by infectious organisms, most commonly *Escherichia coli*. Fortunately, most of these infections are uncomplicated and involve only the urinary bladder. When infection migrates to the upper urinary tract or is seeded there hematogenously, both the renal pelvis and parenchyma become inflamed; thus, the condition is characterized as pyelonephritis . Pyelonephritis is but one cause of interstitial nephritis [2]. Immunocompromised state and diabetes may lead an individual to more severe and life threatening conditions such as emphymsematous pyelonephritis necessitating nephrectomy. An obstructing pathology which has a superimposed infection causes pyonephrosis for which drainage has to be done. Renal infection may lead to chronic irreversibly damaging forms such as chronic pyelonephritis and xanthogranulomatous pyelonephritis. Tuberculosis may also involve the kidney with a calyceal irregularity being the initial manifestation which leads to scarring, fibrosis and infundibular ureteric stricture formation. Immunocompromised patients are particularly pre-disposed to fungal infections, most common organisms being candida, aspergillus and mucormycosis. Some of the inflammatory conditions include malakoplakia and eosinophilic cystitis[1].

The role of diagnostic imaging in the evaluation of patients with suspected urinary tract infections has been much debated. In general, routine radiologic imaging is not required for diagnosis and treatment of uncomplicated cases in adult patients. When images are obtained, however, they demonstrate the nature and extent of disease and reveal complications such as abscess or obstruction. Hence the present study is done to find out role of USG and CT in case of renal infection[2].

Material and Methods:

Present study was carried out in the department of Radio-diagnosis M.M. Institute of Medical Sciences and Research, Mullana, Ambala. Fifty patients with signs and symptoms suggestive of renal inflammatory disease referred from various wards and outpatient departments were included. Patients with renal inflammatory disease were evaluated both by ultrasonography and computed tomography. Ultrasonography was done first followed by computed tomography. CT scan was performed on multi-detector spiral CT ingenuity (Philips medical system, USA). Oral contrast was used depending upon clinical situation. Low dose Plain NCCT of KUB was done at 80 KV ,250 MAS. Then contrast enhanced CT of KUB area was done and slices were taken with pitch 0.765, collimation 640x625, 5mm thickness, 5mm increment at 120 KV and 300 MAS after intravenous administration of 80-120 ml of non-ionic contrast medium (Iohexol) containing 300 mg/ml of iodine. Delayed excretory images were taken at 80KV,150 MAS in all cases. All the images were evaluated in axial, coronal and sagittal plane. Findings of US and CT of renal infections were analyzed in a prospective manner to evaluate their use as a diagnostic modality as well as to determine their contribution in patient management.

Results:

This study had a total of 50 patients out of which there were 32 were females and rest 18 were male. The mean age of patients was 47.8 years with an age range of 21-70 years. Maximum patients (36%) belong to 51-60 years age group. Majority of the patients presented with dysuria and most of them had associated fever. 28 patients came with complain of flank pain. 34 patients had positive history of diabetes mellitus. The various biochemical parameters of patients showed creatinine within a range of 0.9 to 1.8 with a mean of 1.33. Blood urea was within a range of 17 to 49 with a mean of 36.6. Patients with deranged RFT were excluded from the study as CECT could not performed in these patients. TLC ranged from 5000 to 38,600. On analysis of urine the urine culture was positive in half of the cases. Maximum 18 patients had growth of E.coli and 5 patients had pseudomonas infection. In 2 patients positive urine culture for M. tuberculosis was found.

On USG 70% of the kidneys appeared bulky and 12% showed irregular outline. More than 50% appeared heterogeneous and hyperechoic in echotexture. The PCS was found to be thickened in 26% of the cases. In 32% of the cases PCS was dilated and showed echoes within it s/o pyonephrosis. PCS was dilated with presence of echogenic foci within it in 18% of the cases suggesting emphysematous pyelonephritis. Abscess was seen only in one case on ultrasonography. 12% of the patients showed positive findings for nephronia. 24% patients showed calculi on USG.The other findings on USG were involvement of psoas muscle with formation of psoas abscess in 6% cases, perinephric collections in 6% of cases and perinephric air containing collection in 10% of the cases. 6% of the cases were detected as rupture of kidneys. Abdominal lymphadenopathy was detected in 12% of the cases.

Table No.1:-Distribution of patients based on provisional diagnosis by USG:-

USG DIAGNOSIS	No. of cases	Percentage
ACUTE PYELONEPHRITIS	12	24%
EMPHYSEMATOUS PYELONEPHRITIS	09	18%
PYONEPHROSIS	16	32%
RENAL INFECTIONS WITH ABSCESS FORMATION	01	2%
NORMAL	12	24%

On USG (Table-1) various patients were provisionally diagnosed to be cases of APN (12), EPN (9), Pyonephrosis (16), Renal infections with abscess formation (1) based on their USG findings. 12 were found to be normal.

On CT 90% of the kidneys appeared bulky 24% showed irregular outline. After injection of IV contrast enhancement of cortex was found to be heterogeneous and reduced in more than 85% of the cases and in these cases the excretion of contrast was found to be delayed. PCS was thickened in 42% of the cases. PCS was only dilated in 2 cases. PCS was dilated with pelvic wall enhancement in 14 cases and in 10 cases it was dilated with presence of air pockets suggesting pyonephrosis and emphysematous pyelonephritis respectively. One case each of hiked up pelvis and caliectasis with coarse calcification was seen on CT.The CT showed presence of calculi in 36% of the cases. Abscess and nephronia were seen in 4% and 16% of the cases respectively. 10% of the cases showed psoas involvement with psoas abscess formation. Perinephric collections were diagnosed in 10% of the cases and perinephric air containing collections in 14%. Perinephric stranding was seen in majority of the cases of renal infections. Rupture of kidneys were seen in 12 cases out of which 5 cases were of pyonephrosis and 7 cases of emphysematous pyelonephritis. Lymphadenopathy was detected in 22% of the cases.

Table No.2:-Distribution of patients based on provisional diagnosis by CT:-

CT DIAGNOSIS	No. of cases	Percentage
ACUTE PYELONEPHRITIS	19	38%
Type 1 EMPHYSEMATOUS PYELONEPHRITIS	03	6%
Type II EMPHYSEMATOUS PYELONEPHRITIS	07	14%
PYONEPHROSIS	14	28%
RENAL INFECTIONS WITH ABSCESS FORMATION	02	4%
RENAL TB	02	4%
HYDRONEPHROSIS	02	4%
NORMAL	01	2%

On CT (Table-2) various patients were provisionally diagnosed to be APN (19) , EPN(10), Pyonephrosis (14), renal infections with abscess formation (2) , Renal TB (2) , Hydronephrosis (2). One case only was found to be normal. In our study 3 out of 10 cases were diagnosed as Type I EPN and rest 7 cases as Type II EPN

Table No. 3:-Distribution of patients according to final diagnosis based on clinical, investigations and surgical specimen findings:-

FINAL DIAGNOSIS	No. of cases	Percentage %
ACUTE PYELONEPHRITIS	20	40%
EMPHYSEMATOUS PYELONEPHRITIS	10	20%
PYONEPHROSIS	15	30%
RENAL INFECTIONS WITH ABSCESS FORMATION	02	4%
RENAL TUBERCULOSIS	02	4%
XANTHOGRANULOMATOUS PYELONEPHRITIS	01	2%
Total	50	100%

The final diagnosis (Table-3) was arrived at by observing the clinical parameters, investigations and surgical findings wherever performed. There were 20 cases of APN, 10 cases of EPN, 15 cases of pyonephrosis, 2 cases of renal infections with abscess formation , two cases of renal TB and one case of XGP. XGP was misdiagnosed as pyonephrosis on both USG and CT which was diagnosed by histopathological examination of surgical specimen.

CT diagnosed 47 patients correctly out of 50. While USG diagnosed only 38 cases correctly. Thus the accuracy of CT is 94% and of USG is 76% in diagnosing renal inflammatory diseases in our series. On ultrasonography only 12 cases of APN were diagnosed correctly and 19 were correctly diagnosed on CT. Remaining one case was diagnosed with correlation of clinical and laboratory parameters which was not detected by both USG and CT.

EPN was diagnosed with accuracy of 100% on CT while 1 case was misdiagnosed as normal study on USG. Rest 9 were correctly diagnosed on sonography. USG diagnosed 16 cases of pyonephrosis while CT diagnosed only 14 cases. Rest 2 were diagnosed as hydronephrosis on CT. Both ultrasonography and CT misdiagnosed one case of XGP as pyonephrosis which was diagnosed by histopathological examination of specimen.

CT diagnosed 2 cases of renal infections with abscess formation while USG was able to detect only 1 case.

In our series there were two cases of renal tuberculosis which were not diagnosed on ultrasonography and were diagnosed by CT scan and confirmed by urine culture.

Discussion

The purpose of this study was to evaluate the role of USG and CT in renal inflammatory diseases and to correlate their findings with one another and also with clinical outcome and laboratory results. Urine culture was negative in 50% of patients in our study. **Venkatesh et al**[3] had similar findings to our study which showed 76 % negative urine cultures. In our study positive urine culture showed E. coli as the common causative organism followed by pseudomonas similar to study done by **Kumar S et al**[4]

Browne RF et al[5] stated diffuse pyelonephritis shows renal enlargement , poor enhancement and poor excretion in proportion to severity of infection. In our study 86% of cases showed heterogeneous and reduced enhancement of parenchyma and almost same cases showed delayed excretion of contrast. Renal enlargement was seen in most of the cases of acute pyelonephritis, emphysematous pyelonephritis, renal abscess and pyonephrosis in our study.

Kaplan et al[6] and **Rauschkolb et al**[7] reported that CT urography was superior to USG in detecting perinephric collections. Similar findings were present in our study where CT detected perinephric collections in 10% of the cases while only 6% were detected by USG. Breach in PCS and rupture of capsule were better detected by CT than USG. CT was able to detect perinephric fat stranding in all the cases.

Similar to our study which shows air containing perinephric collection in 70% of patients diagnosed with EPN on CT **Singh A**[8] found 44% patients of EPN with air containing perinephric collections on CT.

In our study, CT showed pockets of air in the renal regions in all 10 (100%) patients. Perinephric extension of gas with perinephric collection was noted in 7(70%) patients. CT was able to classify the EPN, with 3 (30%) cases of Type I EPN and 7(70%) cases of Type II EPN. While USG showed echogenic foci in pelvicalyceal system in 9 (90%)cases and perinephric air containing collection in 5 (50%) cases suggesting EPN.

Goncalves E et al[9] opined CT is the most sensitive and specific modality for diagnosing emphysematous urinary tract infections. CT is

most reliable in demonstrating the presence and location of gas in collecting system , renal parenchyma and perinephric spaces. **Wan et al**[10] in their study described classification of EPN by CT : type I characterized by parenchymal destruction and presence of air in parenchyma with absence of fluid collection having mortality rate 69%(11 out of 16 patients) and type II characterized by either renal/perinephric fluid collection with presence of gas in collecting system having mortality rate of 18%(4 out of 22). In our study 66% (2 out of 3) mortality was seen in patients with type I EPN with poorly controlled diabetes while none was reported in type II EPN due to early diagnosis and management (Table No. 22). **Wan et al**[10] hypothesized that clinicopathological difference between type I and type II EPN is due to difference in severity of immune compromise and vascular insufficiency in kidney in patients with diabetes mellitus.

One of the aims of this present study is to compare ultrasound and CT results in evaluation of renal infections. Of all the 50 cases, we reached the final diagnosis either by histopathological examination of nephrectomy specimen (wherever performed), by pathological examination of aspirated material or by follow-up. USG was able to diagnose renal infections in 38 out of 50 cases while CT diagnosed 47 cases correctly..

In our study only 12 cases were diagnosed with Acute pyelonephritis sonographically and 19 out of 20 were diagnosed by CT. All of them improved after antibiotic treatment. **Noble VE and Brown DF** [11] opined that conventional ultrasonography is relatively insensitive for detecting renal parenchymal lesions in APN. **Mitterberger M et al**[12] also concluded that CT is superior to USG for determining severity of APN. They stated that CT can provide better information about underlying abnormalities such as stones, abscesses and congential anomalies than USG.CT enables the extent of APN to be ascertained and produce results that are examiner dependent.`

Venkatesh et al[3] diagnosed renal abscess in 3 patients which were not detected by USG but were diagnosed on CT scan. In our study it was observed that CT was able to diagnose two cases of renal infections with renal abscess while only one case was detected by USG. **Rollino C et al**[13] in their study showed that sensitivity of USG and CT in diagnosing renal abscess was 92% and 96% respectively. Both the cases of renal abscesses were put on antibiotics and they improved with resolution confirmed on USG.

16 cases of pyonephrosis were diagnosed on USG and 14 cases on CT scan. Rest two were misdiagnosed as hydronephrosis on CT. PCS was dilated with presence of echoes on USG and CT showed dilated PCS with pelvic wall enhancement. Thus USG was found to be more sensitive in diagnosing pyonephrosis than CT. Similar to our study **Subramanyam BR et al**[14]concluded that sonography has high accuracy (96%) in differentiation of pyonephrosis from hydronephrosis.

Both CT and USG misdiagnosed one case of xanthogranulomatous pyelonephritis as pyonephrosis which was diagnosed by histopathological examination of the specimen. Kidney enlargement and hydronephrosis were common findings in studies done by **Loffroy R et al**[15] and **Leoni F et al**[16]. In their study XGP was misdiagnosed pre-operatively as pyelonephritis, tuberculosis and renal cell carcinoma and concluded definitive diagnosis of XGP depends on histopathological examination.

Ultrasound was not able to detect renal tuberculosis which were correctly diagnosed on CT showing hiked pelvis, caliectasis with coarse calcification. **Sankhe A et al**[17] opined computed tomography is highly sensitive for detection of calcification which is commonly seen in tuberculosis.

Conclusion:

The modality of choice for the initial examination in renal infection cases will almost universally be ultrasound . USG is inexpensive, immediate, painless, requires no sedation and is widely available, and is radiation free. USG forms an excellent screening tool for evaluation in emergency setting.However there are few limitations such as operator dependency, bowel gas, edema and obesity making it less sensitive. Unlike USG CT involves the risk of radiation exposure and allergic reaction to IV contrast. However, CT scan has excellent spatial resolution and less artefacts making it the mainstay in evaluation of renal infections as CT is more sensitive and specific in diagnosing APN, EPN, calculi and extent of perinephric involvement. In our study CT scan had high sensitivity (97.6%) and high specificity in diagnosing renal inflammatory diseases with accuracy of 96% than ultrasonography.

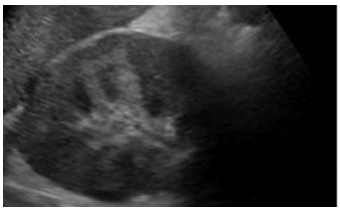

Fig-1a

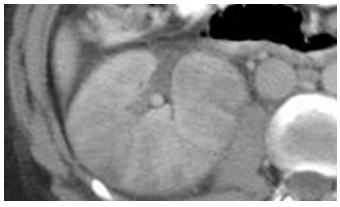

Fig-1b

Fig-1a USG shows bulky right kidney with heterogeneous echotexture of renal parenchyma.

Fig-1b Axial section of Contrast enhanced CT shows renal enlargement with hetereogenous enhancement of right kidney

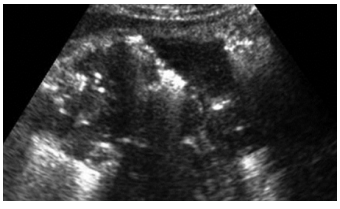

Fig-2a

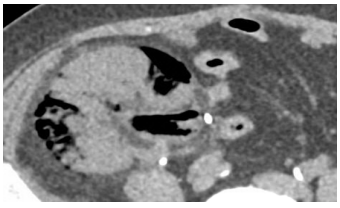

Fig-2b

Fig:2a - USG shows hypoechoic right kidney with presence of echogenic foci with dirty shadows in renal parenchyma and PCS.

Fig-2b- Axial sections of CT shows enlarged right kidney with presence of air pockets within the parenchyma and PCS.

REFERENCES

1. Das CJ, Ahmad Z, Sharma S et al. Multimodality imaging of renal inflammatory lesions. World J Radiol 2014; 6:865-73.
2. Craig WD, Wagner BJ, Travis MD. Pyelonephritis: Radiologic-Pathologic Review. RadioGraphics 2008; 28:255–276
3. Venkatesh L ,Hanumegowda RK. Acute pyelonephritis – correlation of clinical parameter with radiological imaging abnormalities. JCDR 2017; 11:15-18
4. Kumar S, Ramachandran R, Mete U et al. Acute pyelonephritis in diabetes mellitus: Single center experience. Indian J nephrol 2014; 24(6): 367-71
5. Brown RF, Zwirewich C, Torreggiani WC. Imaging of urinary tract infection in the adult. EurRadiol 2004; 14:168-183
6. Kaplan DM, Rosenfield AT, Smith RC. Advances in the imaging of renal infection: Helical CT and modern co-ordinated imaging. Infect Dis Clin North AM 1997; 11:681-705
7. Rauschkolb EN, Sandler CM, Patel S et al. Computed tomography of renal inflammatory disease. J Comput Assist Tomogr 1982; 6:502-506.
8. Singh A. Clinico-radiological features and classification of emphysematous pyelonephritis: A prospective study. NJR 2014; 4:38-46
9. GoncalvesE , Maia BT, Versiani CM et al. Unilateral emphysematous pyelitis: case report. Radiol Bras 2013; 46:56-58
10. Wan YL, Lee TY, Bullard MJ et al. Acute gas producing bacterial renal infection: correlation between imaging findings and clinical outcome. RSNA 1996; 198:433-438
11. Noble VE, Brown DF. Renal ultrasound. Emerg Med Clin North Am 2004; 22:641-659
12. Mitterberger M, Pinggera GM, Colleselli D. Acute pyelonephritis: comparison of diagnosis with computed tomography and contrast enhanced ultrasonography. BJU Int 2008; 101:341-344.
13. Rollino C, Beltrame G, Ferro M et al. Acute pyelonephritis in adults: a case series of 223 patients. Nephrol dial 2012; 27:3488-3493

14. Subramanyam BR, Raghavendra BN, Bosniak MA et al. Sonography of pyonephrosis: A prospective study. AJR 1983; 140:991-993
15. Loffroy R, Guiu B, Watfa J et al. Xanthogranulomatous pyelonephritis in adults: Clinical and radiological findings in diffuse and focal forms. ClinRadiol 2007; 62:884-90
16. Leoni FA, Kinleiner P, Revol M et al. Xanthogranulomatous pyelonephritis: Review of 10 cases. Arch Esp Urol. 2009; 62:259-271.
17. Sankhe A and Joshi AR. Multidetector CT in renal tuberculosis. CurrRadiol Rep 2014; 69:1-11