ORIGINAL RESEARCH PAPER

Volume-8 | Issue-2 | February-2019 | PRINT ISSN No 2277 - 8179

INTERNATIONAL JOURNAL OF SCIENTIFIC RESEARCH

ROLE OF ULTRASOUND ELASTOGARPHY IN DETECTION OF VARIOUS BENIGN AND MALIGNANT LESIONS OF BREAST WITH CYTOLOGY OR HISTOPATHOLOGICAL CORRELATION

Radiodiagnosis

Dr. Vinod Kumar Mogha Junior Resident, Department of Radio-diagnosis, SRMS IMS, Bareilly

Dr. Rajneesh Madhok* Professor & HOD, Department of Radio-diagnosis. , SRMS IMS, Bareilly
*Corresponding Author

ABSTRACT

INTRODUCTION: Breast cancer is the most frequent cancer site in women. Elastography is a relatively new imaging technology that creates images of tissue stiffness. On the elastogram, different colour modes imply different tissue stiffness, thereby offering more information with respect to differentiation between benign and malignant lesions.

AIM: The aim of the study was to evaluate the role of ultrasound elastography in detection of various benign and malignant lesions of breast with cytology or histopathological correlation.

MATERIAL & METHODS: 50 female patients with breast lump were evaluated. All cases were examined clinically and investigated with ultrasound elastography followed by cyto/histopathological examination. The data so procured was analysed statistically, were documented and the results analysed.

RESULTS: On Elastography 33 lesions were diagnosed as benign and 17 as malignant, and Histopathology revealed 27 lesions to be benign and 23 lesions to be malignant. On elastography sensitivity for malignant lesions was 73.91% and specificity was 100.0%.

CONCLUSION: Sonoelastography is a simple, non invasive and rapid diagnostic method that can provide a diagnostic contribution to conventional ultrasound by increasing specificity.

KEYWORDS

Elasto- Elastography, FNAC – Fine Needle Aspiration Needle, BIRADS- Breast Imaging reporting and data system

INTRODUCTION

Breast cancer is the most frequent cancer site in women (28.8%) of all cancer sites, and an estimated lifetime risk of 1/9 women. It is the fifth cause of tumor death overall (7.5%) and the first in women. Breast masses have a variety of aetiologies; they can be either benign or malignant. Fibroadenoma is the most common benign breast mass; whereas invasive ductal carcinoma is the most common malignancy[1]. Most of the breast masses are of benign nature; breast cancer is the most common cancer.[2]

Diagnostic senology has the purpose of the early diagnosis of breast cancer[3]. Mammography was used primarily for early detection of malignancies in their curable stages, to decrease the malignancy related mortality. It is screening tool which is easily available, cheap and fairly accurate with minimal radiation to detect micro-calcifications, speculated masses and small lymph nodes seen in malignancies. Incidence of breast cancer can be reduced by 30% by the routine mammographic screening of healthy women.[4,5] . According to BIRADS CLASSIFICATION, the Lesions are classified as:-

BIRADS 0: Incomplete, further imaging required,
BIRADS I: Negative, symmetrical & no masses, architectural disturbance,
BIRADS II: Benign findings,
BIRADS III: Probably benign,
BIRADS IV, Probably malignant (classification IVa, IVb, Ivc) -

- BIRADS IVa: low level of suspicion for malignancy
- BIRADS IVb: intermediate suspicion for malignancy
- BIRADS IVc: moderate suspicion for malignancy

BIRADS V: Mammographic appearance s/o malignancy
BIRADS VI: Biopsy proven malignancy.

Ultrasonography plays a key role to differentiate solid mass from cyst, which accounts for approximately 25% of breast lesions, also it helps in differentiating benign from malignant lesions if their criteria for diagnosis are fulfilled.[6] It is useful in the evaluation of palpable masses not visible in radiographically dense breasts, abscesses, masses that are not completely evaluable with mammography and in young patients susceptible to radiation damage.[6,7]

Elastography is a relatively new imaging technology that creates images of tissue stiffness. It can be thought of an extension of the ancient technique of palpation but it gives better spatial localization information and is less subjective. Two main types of elastography are currently in use, strain elastography where the tissue displacement in response to gentle pressure is used to compute and image tissue strain (compression), and shear wave elastography where the speed of shear waves traversing tissue is measured and used to create an image of tissue stiffness. Each method has advantages and disadvantages but generally strain imaging is excellent for focal lesions and shears wave imaging, being more quantitative, is best for diffuse organ diseases [8] like liver stiffness.

Real-time ultrasound strain elastography is one of the most widely used techniques in breast lesions. The two most important elastographic characteristic in evaluating breast lesions are size and stiffness criteria. The size criterion denotes the difference in the measurement of the longest diameter on the corresponding B-mode image and the elastogram. Structures that are less compressible than surrounding tissues measure larger on the elastogram than they do on the corresponding B-mode image, resulting in size discordance. Therefore, cancers will be larger on the elastogram than on the conventional US image. Alternatively, this characteristic can be expressed as a ratio, such that a ratio (strain ratio) of elastogram–to–B mode lesion diameters that is greater than or equal to one is suggestive of malignancy .This phenomenon is attributed to the desmoplastic reaction incited by many malignant breast neoplasms.

In Stiffness criteria, the malignant lesions have higher stiffness than that of surrounding normal tissue .Consequently; breast cancers will appear dark on elastograms. The elastogram, which reflects the elasticity of the tissues, is created as a color coded map. On the elastogram, different colour modes imply different tissue stiffness, thereby offering more information with respect to differentiation between benign and malignant lesions. Blue indicate 'hard tissue/area of great stiffness', green indicate 'medium stiffness' of the tissue and red indicate 'soft tissue'.Consequently the malignant lesions that are subtle or even unapparent on B-mode US images are prominent on color coded elastograms.

Elastography images of breast lesions has shown the potential to improve the diagnostic accuracy of radiologists in distinguishing between malignant and benign breast lesions [9,10] interpretation of color-coded elasticity images, a 5-point visual scoring system has been widely used and a cut-off point between an elasticity score of 3 and 4 has been recommended for the classification of benign and malignant tumors.[11]

Score 1	Benign Lesion
Score 2	Benign Lesion
Score 3	Benign/ Malignant Lesion
Score 4	Malignant Lesion
Score 5	Malignant Lesion

MATERIAL AND METHODS

A prospective study of 50 female patients of breast lumps was evaluated in our department of Radio-diagnosis in 2016-18. The sample size was calculated using the nMaster 2.0 software. The power of the study was taken to be 80% and Confidence Interval (C.I.) of 95% was taken.

Acuson S 2000 system (Siemens Medical Solutions) having capability of colour doppler and sonoelastography and a linear array transducer (Siemens Medical Solutions) with a centre frequency of 7.5 MHz (range, 5.0–14.0 MHz).

Inclusion criteria:

- Patients referred for breast mammography or/and B mode ultrasonography and are detected to have breast lesions, in category 3, 4, 5 of the Breast Imaging Reporting and Data Systems (BI-RADS) will undergo real time ultrasound elastography & confirmed by cyto / histopathological examination.

Exclusion criteria:

- Patients who had previous diagnosis of breast cancer.
- Post operative breast.
- Any breast implant.

ULTRASOUND EXAMINATION

Every mass was examined for shape, margin, posterior acoustic shadow, echopattern, calcification, and associated features; architectural distortion, duct changes, skin thickening, skin retraction and interstitial edema in transverse and longitudinal scans. Irregular spiculated margin, heterogeneous echogenicity and posterior acoustic shadow were considered the malignant criteria for breast lesions.

All examined masses were categorized according to BI-RADS categories according to ACR2013, according to US lexicon; grade 2: benign findings (essentially 0% malignancy), grade 3: probably benign (less than 2% malignant), grade 4: suspicious abnormality (4a: 2–10%, 4b: 10–50%, 4c: 50–95% risk of malignancy), grade 5: highly suggestive of malignancy (more than 95% malignancy), grade 6: known proven malignancy.

SONOELASTOGRAPHY EXAMINATION

B-mode images with sonoelastographic images were obtained together, then the sonoelastographic image were coded with color, The hardest lesion was blue with no strain, the softest one was red with the highest strain, and the green color indicated the intermediate elasticity. Lesions classification was performed on the basis of a 5-point scoring method proposed by Tsukuba elasticity score developed by Itoh and Ueno11 . Score 1: given to the lesions had the same color (green) and elasticity of normal breast tissue, score 2: lesions with inhomogeneous elasticity (strain), displaying mixed green and blue color, score 3: lesions with elastic green periphery and stiff blue centre, and score 4: all the mass area was blue (stiff), and score 5: the lesions and the adjacent tissue showed blue color. Score 1&2 indicating benign lesions; score 3 indicating benign or malignant, score 4 & 5 indicating malignant lesions.

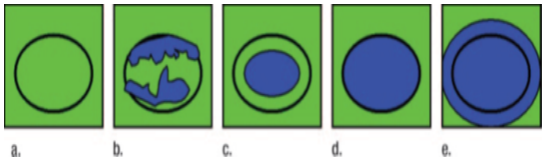

Figure 1: Images present general appearance of lesions for elasticity scores of (a) 1, (b) 2, (c) 3, (d) 4, and (e) 5. Black circle indicates outline of hypoechoic lesion (ie, border between lesion and surrounding breast tissue) on B-mode images.

The strain ratio allows semiquantitative measurements. Recent studies have suggested that strain ratio is an objective method of assessing elasticity for differentiating benign from malignant lesions[12,13]. In addition strain ratio increases the sensivity & positive predictive values for the differentiation of breast lesions to 90% & 89%, compared with 81% and 84% for the elasticity score, respectively[14].

However the results have not been consistent across studies. In recent ,prospective study by Yeril et al15, the strain ratio and elasticity score had similar diagnostic performance for differentiating between benign and malignant breast masses, thus we concluded that additional semiquantitative evaluation using the strain ratio is not mandatory and only elasticity score is calculated. Jin yu et al16 in their study had similar opinion and performed only elastography score.

RESULTS

A total of 50 female patients were studied age ranged between 17 to 68 years.

Table 1: Distribution of the study population according to age groups

Age groups	Frequency	Percentage
17-30 years	12	24.0
31-45 years	23	46.0
46-60 years	12	24.0
Above 60 years	3	6.0

The study population consisted of 12 (24.0%) subjects belonging to 17-30 years age group, 23 (46.0%) subjects belonging to 31-45 years, 12 (24.0%) subjects belonging to 46-60 years and 3 (6.0%) subjects belonging to Above 60 years.

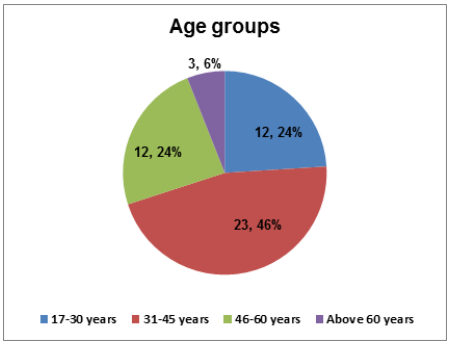

Table 2: Distribution of the clinical symptoms among the study population.

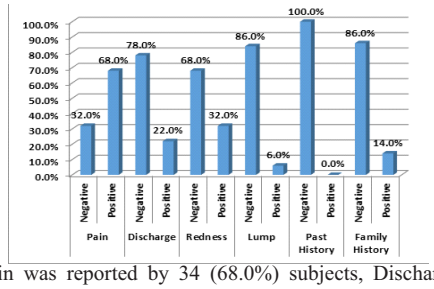

The Pain was reported by 34 (68.0%) subjects, Discharge by 11 (22.0%) subjects, Redness by 16 (32.0%) subjects, Lump by 43 (86.0%) subjects and Positive family history by 7 (14.0%) subjects.

Table 3: Distribution of shape of lesion among study population in ultrasound

Shape	Frequency	Percentage
Ill-defined	14	28.0%
Well defined (Round to oval)	36	72.0%
Total	50	100.0%

The shape of the lesion was ill-defined in 14 (28.0%) and Well-defined (Round to oval) in 36 (72.0%) subjects.

Table 4: Distribution of size, Nodules involved among the study population

		Frequency	Percentage
Size	< 5 cm	47	94.0
	> 5 cm	3	6.0
Nodules	Multiple	13	26.0
	Single	37	74.0

Size less than 5 cms was reported by 47 (94.0%) subjects and more than 5 cms by 3 (6.0%) subjects. Single nodule was reported by 37 (74.0%) and Multiple nodule by 7 (14.0%) subjects.

Table 5: Distribution of Internal echo among study population in ultrasound

Internal echo	Frequency	Percentage
Heteroechoic	9	18.0%
Hypoechoic	41	82.0%
Total	50	100.0%

Internal echo was found to be Heteroechoic in 9 (18.0%) and Hypoechoic in 41 (82.0%) subjects.

Table 6: Distribution of Lymph node involved among study population in ultrasound

Lymph nodes	Frequency	Percentage
Negative	34	68.0%
Positive	16	32.0%
Total	50	100.0%

Lymph nodes were found to be positive among 16 (32.0%) subjects.

Table 7: Distribution of Colour scale in elastography among study population

Colour scale	Frequency	Percentage
Red	1	2.0%
Blue	9	18.0%
Green	1	2.0%
Blue + Green	39	78.0%
Total	50	100.0%

Blue indicate 'hard tissue/area of great stiffness', green indicate 'medium stiffness' of the tissue and red indicate 'soft tissue as per colour coding of S-2000 ultrasound machine. Distribution of colour scale showed that Red was found among1 (2.0%), Blue was found among 9 (18.0%), Green was found among 1 (2.0%) and Blue + Green was found among 39 (78.0%) subjects.

Table 8: Distribution of Elastography Score among study population

Elastography Score	Frequency	Percentage
1	1	2.0%
2	1	2.0%
3	39	78%
4	4	8%
5	5	10.0%
Total	50	100.0%

For characterization of breast lesions, elastography scoring is done by the Tsukuba scoring system developed by Itoh et al.[11]

Score 1 is assigned to even strain or elasticity in the entire lesion and was found in 2%. Score 2 is assigned to strain or elasticity in most of the lesion with some areas of no strain which was the most common finding and accounted to be 2%, Score 3 is assigned to strain or elasticity at the peripheral part of the lesion sparing the central part of the lesion and was found in 78%, Score 4 is assigned to no strain or elasticity in the entire lesion was found in 8%,, Score 5 is assigned to no strain or elasticity in the entire lesion or in the surrounding area was found in 10%.

Table 9: Comparison between Cyto/ Histopathology and Elastography.

	Cyto / Histopathology	Elastography		
Diagnosis	**Frequency**	**Percentage**	**Frequency**	**Percentage**
Benign	27	54.0%	33	66.0%
Malignant	23	46.0%	17	34.0%
Total	50	100.0%	50	100.0%
Chi-square value = 1.500, p-value = 0.221#				

Chi-square test **# Non-significant difference**

Cyto/Histopathology found 27 (54.0%) lesions to be benign and 23 (46.0%) lesions to be malignant whereas in Elastography 33 (66%) lesions were diagnosed as benign and 17(34%) as Malignant. The distribution of identification of benign and malignant lesions was compared between Cyto/Histopathology and Elastography using the Chi-square test. There was no significant difference in the identification of benign and malignant lesions between Cyto / Histopathology and Elastography.

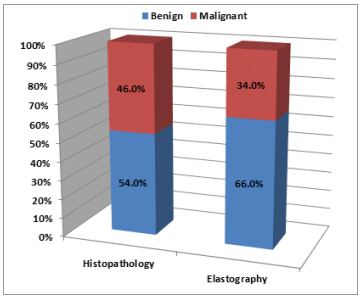

Table 10: Comparison of Cyto/Histopathlogical diagnosis with Elastography Score

Cyto / Histo pathological Diagnosis	Elastography Score	Total				
Benign	1	2	3	4	5	
	1	1	25	0	0	27
	3.7%	3.7%	92.6%	0.0%	0.0%	100.0%
Malignant	0	0	14	4	5	23
	0.0%	0.0%	60.9%	17.3%	21.8%	100.0%
Total	1	1	39	4	5	50
	2.0%	2.0%	78.0%	8.0%	10.0%	100.0%

Chi-square test **# Non-significant difference**

The distribution of identification of benign and malignant lesions was compared between **Elastography Score** using the **Chi-square test**. There was no significant difference in the identification of benign and malignant lesions between different categories of **Elastography Score**.

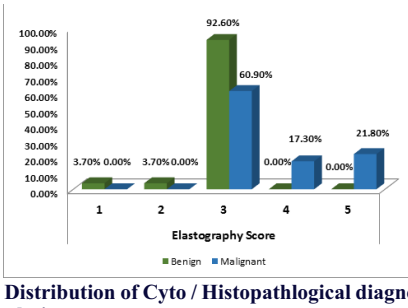

Table 11: Distribution of Cyto / Histopathlogical diagnosis among study population

Cyto / Histopathlogical diagnosis	Frequency	Percentage
Acute mastitis	1	2.0%
Benign breast disease; Fibrotic disease	1	2.0%
Benign cystic lesions	2	4.0%
Benign proliferative disease	1	2.0%
Fibroadenoma	15	30.0%
Fibrocystic disease	3	6.0%
Phyllodes tumor	2	4.0%
Tubercular abscess	2	4.0%
Invasive ductal carcinoma	22	44.0%
Positive for malignant cells	1	2.0%

Cyto/Histopathological diagnosis showed that Acute mastitis was found among 1 (2.0%), Benign breast disease; Fibrotic disease 1 (2.0%), Benign cystic lesions among 2 (4.0%), Benign proliferative disease among 1 (2.0%), Fibroadenoma among 15, (30.0%), Fibrocystic disease 3 (6%), Phyllodes tumor among 2 (4.0%), Tubercular abscess among 2 (4.0%), Invasive ductal carcinoma among 22 (44.0%) and Positive for malignant cells among 1 (2.0%).

Table 12: ROC (Receiver operating characteristic) **curve showing the Sensitivity, Specificity, Cut-off value and Area under curve (AUC).**

	Sensitivity	Specificity	Cut-off value	AUC	P-value
Elastography score	73.91%	100.0%	>2	0.884	<0.001 *

The cut-off value was found to be more than 2 for the malignant lesions as per the Elastography score when compared to

Cyto/Histopathological examination with a sensitivity of 73.91% and specificity of 100.0%.

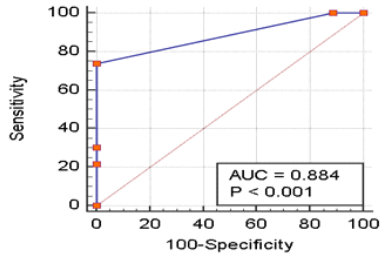

CASE NO. – 1

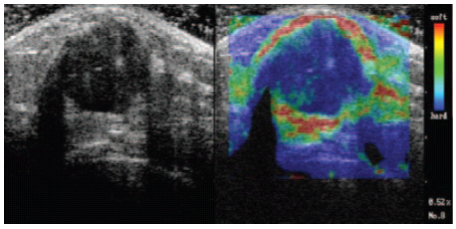

Case of Invasive Ductal Carcinoma In Right Breast. On Conventional B-Mode Image (Left) Shows Well Defined Hypoechoic Lesion. On Elasticity Image (Right) Shows the Entire Hypoechoic Blue Strain Lesion.

Case No. -2

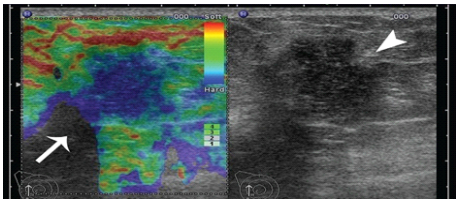

Case of Invasive Ductal Carcinoma In Left Breast shows B-Mode Ultrasound (Right) shows Ill-Defined Hypoechoic lesion with Strain Elastography (Left), Both Entire Hypoechoic lesion and Its surrounding area were blue.

Case No. – 3

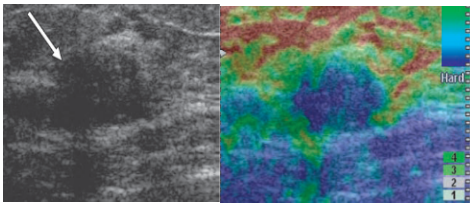

Case of Ductal Carcinoma in Right Breast shows (B-Mode Image) Hypoechoic Mass with Ill-Defined margins (*Arrow*). Elasticity image with Color Coding shows Blue Strain at Periphery of Hypoechoic lesion and Sparing of center of lesion.

Case No. – 4

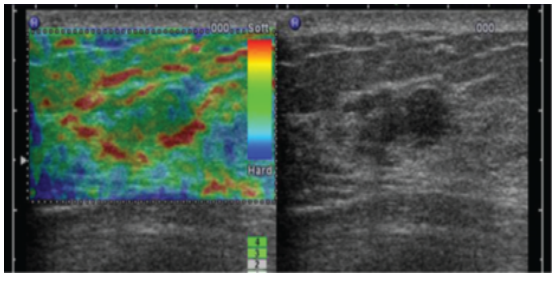

Case of Fibroadenoma in Left Breast. B- Mode Image (Right) Shows Ill-Defined, Hypoechoic Lesion. Elastogram (Left) Shows The Entire Lesion Shaded In Green With Focal Red Spots.

Case No. – 5

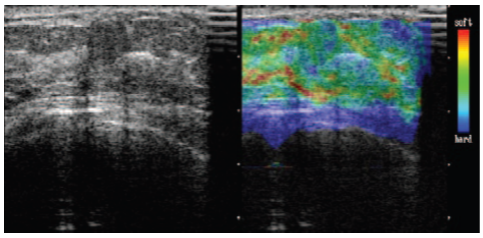

Case of fibroadenoma in right breast shows (B-mode image) hypoechoic lesion. Elasticity image with color coding shows the entire hypoechoic lesion was evenly shaded green.

Case No. – 6

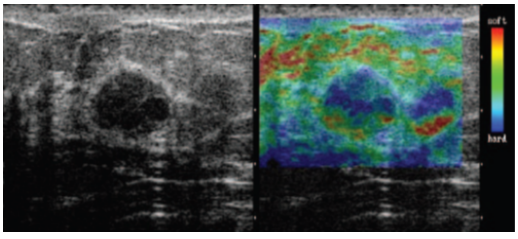

Case of Fibroadenoma in right breast. on conventional B-mode image (left) shows hypoechoic lesion. On elasticity image (right), hypoechoic lesion shows mosaic pattern of green and blue.

DISCUSSION

Strain elastography can differentiate between benign and malignant lesions on the basis of their firmness. The lesion's contours, dimensions, colour, strain ratio, and appearance on elastography are some of the criteria used for differentiating benign from malignant lesions. Malignant lesions, which are very stiff, deform less and are displayed in red/blue on the Elastography images, whereas benign lesions deform much more easily and are depicted in green colour in ours study.[17,18]

For characterization of breast lesions, we used elasticity scoring systems by Tsukuba score developed by Itoh et al.[11]

In present study, Histopathology found 54.0% lesions to be Benign and 46.0% lesions to be malignant whereas Elastography found 66.0% lesions to be Benign and 34.0% lesions to be malignant with no significant difference between them.

In our ROC analysis, if the cut off value was set as 3.0, the sensitivity of the test was calculated as 73.91% that was compatible with other studies, however, the specificity rate was calculated as 100.0% and the number of masses with false-positive diagnosis increased. Area under the curve was found to be 0.884.

According to the results of the present study, we observes that sonoelastography presents sensitivity and specificity to differentiate breast lesions.

Recent studies have showed that elastography markedly increased the specificity of ultrasound and the early diagnosis of breast cancer under one centimeter, and it decreased the number of unnecessary biopsies especially in BIRADS 3 and 4 lesions.[19,20]

It is stated that elastography can be clinically used as an imaging method in patient follow-up or as a method for determining whether to perform an invasive procedure or not. It has been reported that distinguishing between score 2 and score 3 lesions by elastography might be difficult in some cases, but diagnosing score 1 lesions is very easy since a blue color is not present in these lesions.[21]

Our results were found to be quite similar to the studies by **Bakdeet al**,[22] when a cut-off point of 3 was used, a sensitivity of 83.9% and a specificity of 91.7% obtained for elasticity score and a sensitivity of 81% and a specificity of 89% were reported by Thomas et al.,[23] in a study where 227 breast lesions were examined.

Ours results were also consistent with other published data on the use of real-time USG Elastography.[11]

Cho et al.[24] detected the sensitivity as 100% and specificity as 33% with a cut-off value between conventional ultrasound BI-RADS categorization category 3 and category 4a. In contrast, when the cut-off value for sonoelastography score of 2 and scored 3 were used, they determined the sensitivity as 82% and specificity as 84% which was similar to our study.

Okar Atabey et al.[25] evaluated 96 patients with 110 lesions by US elastography and used the 5 score system. For US elastography, the specificity was reported as 83%, sensitivity 89%, positive predictive value 79% and negative predictive value 91% which was similar to the present study.

Parajuly et al.[26] studied 342 lesions in 325 patients according to the elastography scoring system with a threshold score between 3 and 4, they found the sensitivity as 77.7% and specificity as 96.2% which was similar to ours study.

In our study, we took a cut-off value of 3.Other studies have taken different cut-off values, When Yağtu et al.[27] evaluated 76 lesions of 76 patients, with a cut-off value of 4.0 they reported the sensitivity as 83.3%, specificity 76.9%, positive predictive value 62.3%, and negative predictive value as 90.7%.

In the clinical setting, SE is useful for deciding whether to follow-up patients with imaging or to intervene.[19] Sometimes it is difficult to differentiate between scores 2 and 3 on SE images, but it is very easy to diagnose a lesion as having score 1, because no blue area is observed.[20] In the study by **Bakdeet al**,[22] there was good correlation (Pearson coefficient = 0.936) between qualitative and quantitative elastography methods (elasticity score and SR) and by performing both techniques a more confident diagnosis can be made.

According to the results of the present study, it is observed that sonoelastography increases sensitivity and specificity to differentiate breast lesions, Other Recent studies **Zhu et al (2008) Daniel T. Ginar et al (2009) & Yaðtu et al (2014)** have showed that elastography markedly increased the specificity of ultrasound and the early diagnosis of breast cancer under one centimetre, and it decreased the number of unnecessary biopsies especially in BIRADS 3 and 4 lesions.[28-30] It is stated that elastography can be clinically used as an imaging method in patient follow-up or as a method for determining whether to perform an invasive procedure or not.

It has been reported that distinguishing between score 2 and score 3 lesions by elastography might be difficult in some cases, but diagnosing score 1 lesions is very easy since a blue colour is not present in these lesions.[31] Similar were the results in ours study

Although mammography is recognized as the best method of screening for breast cancer, breast sonography has become well establish a valuable imaging technique. Although there has been some controversy regarding the utility of sonography when evaluating solid breast masses for the likelihood of malignancy,[32] several studies have suggested that sonographic appearance can be useful in differentiating benign from malignant solid breast masses.[33-35] **Rahbaret al**.[34] found that the features most likely to predict a benign diagnosis in solid masses were round or oval shape, had a circumscribed margin, and had a width-to-antero- posterior ratio greater than 1.4. Features most predictive of malignancy were irregular shape, micro- lobulated or speculated margin, and width-to-antero-posterior ratio of less than or equal to 1.4.

However, ultrasonographic elastography has little dis-advantages such as the sensitivity of ultrasonographic elastography is less than classic ultrasonography in the evaluation of non-focal pathologic changes. It also fails to identify postoperative changes, diffuse lesions, and lesions larger than that of the probe. In addition, the role of elastography is limited in very dense fibrous parenchyma, in presence of hematoma and breast implants. Some studies have also showed its value in the differentiation of benign and malignant lymph nodes.[21] It is reported that both the mechanical type of elastography method that we used in this study and the shear wave elastography method that is more software dependent provide similar results.[36]

The lack of diversity of malignant lesions due to the small number of lesions is a limitation of our study. In addition, lack of inter observer evaluation creates another limitation.

CONCLUSION

Sonoelastography is a simple, noninvasive and rapid diagnostic method that can provide a diagnostic contribution to conventional ultrasound by increasing specificity. It also may help in classification of BIRADS 3 solid mass lesions as either BIRADS 2 or 4. This might in turn reduce the rate of unnecessary biopsies, reduce anxiety in patients and may contribute to lowering biopsy costs. Although elastography is not a method that can replace conventional breast ultrasound for detecting breast cancer, it may be an adjunct to conventional ultrasound by increasing its diagnostic power.

REFERENCES

1. American Cancer Society. Cancer facts and figures 2003.Accessed,online October 14,2004
2. Kopans DB. Imagem da mama. 2ª ed. Rio de Janeiro: Medsi; 2000.
3. Diego DB, Dalmar A , Elisabetta G, Jacopo N, Ermanno V, Leonardo C.Radiological anatomy of the breast. IJAE 2016;121(1):20-36.
4. Morris KT, Vetto JT, Petty JK, Lum SS, Schmidt WA, Toth-Fejel S, Pommier RF. A new score for the evaluation of palpable breast masses in women under age 40. Am J Surg. 2002;184(4):346-7.
5. Berg WA, Gutierrez L, Ness Aiver MS, Carter WB, Bhargavan M, Lewis RS, Ioffe OB. Diagnostic Accuracy MR Imaging in Preoperative Assessment of Breast Cancer. Radiology 2004;233:830-49.
6. Hall TJ.AAPM/RSNA physics tutorial for residents. Topics in US: beyond the basics – elasticity imaging in the US.Radiographics 2003;23:1657-71.
7. Regner DM, Hesley GK, Hangiandreou NJ, et al. Breast lesions: evaluation with US strain imaging – clinical experience of multiple observers.Radiology 2006:238:425-37.
8. Wang Y, Dan H-J, Dan H-Y, Li T, Hu : Differential Diagnosis of Small Single Solid Nodules using real time ultrasound elastography. Journal of International Medical Research. 2010;38:466.
9. Chang RF, Huang SF, Moon WK, Lee YH, Chen DR. Solid breast masses: neural network analysis of vascular features at three-dimensional power Doppler US for benign or malignant classification. Radiology 2007;243:56–62.
10. Joo S, Moon WK, Kim HC. Computer-aided diagnosis of solid breast nodules on ultrasound with digital image processing and artificial neural network Conf Proc IEEE Eng Med Biol Soc 2004;2:1397–1400.
11. Itoh A, Ueno E, Tohno E, Kamma H, Takahashi H, Shiina T, et al. Breast disease: clinical application of US elastography for diagnosis. Radiology 2006;239:341–350.
12. Zhi H, Xiao X, Yang H, et al. Semi-quantitating stiffness of breast solid lesions in ultrasonic elastography. Acad Radiol 2008; 15:1347–1353 [Crossref] [Medline] [Google Scholar].
13. Cho N, Moon WK, Kim HY, Chang JM, Park SH, Lyou CY. Sonoelastographic strain index for differentiation of benign and malignant nonpalpable breast masses. J Ultrasound Med 2010; 29:1–7 [Medline] [Google Scholar]
14. Thomas A, Degenhardt F, Farrokh A, Wojcinski S, Slowinski T, Fischer T. Significant differentiation of focal breast lesions: calculation of strain ratio in breast sonoelastography. Acad Radiol 2010; 17:558–563 [Crossref] [Medline] [Google Scholar
15. Yerli H, Yilmaz T, Kasati T, Gulay H. Qualitave and semiquantitavie evaluations of solid breast lesions by sonoelastography. J Ultrasound Med 2011:30;179-186 [Medline] [Google Scholar].
16. Jin You, Kim,Jongki, Shin and Suck and HongLee. American journal of Roentgenology.2015;205:W630-W638.10.2214/AJR.14269.
17. Alam SK, Ophir J, Varghese T: Elastographic axial resolution criteria: An experimental study. IEEE Trans UFFC 2000;47(1):304–309.
18. Itoh A. Review of the techniques and diagnostic criteria of breast ultrasound elastography. Medix Hitachi 2007;1:8-11.
19. Thomas A, Kümmel S, Fritzsche F, et al. Realtime sonoelastography performed in addition to B-mode ultrasound and mammography: improved differentiation of breast lesions? Acad Radiol. 2006;13:1496–504.
20. Kim MY, Cho N, Yi A, Koo HR, Yun BL, Moon WK. Sonoelastography in distinguishing benign from malignant complex breast mass and making the decision to biopsy Korean J Radiol 2013; 14:559-67.
21. Scaperrotta G, Ferranti C, Costa C, Mariani L, Marchesini M, Suman L, Folini C, Bergonzi S. Role of sonoelastography in nonpalpable breast lesions. Eur Radiol 2008; 18:2381-9.
22. Bakde A, Gaur P. Ultrasound Elastography evaluation of breast masses with FNAC and/or Histopathological correlation. International Journal of Current Research 10;(01):65008-16.
23. Thomas A., Degenhardt F., Farrokh A., Wojcinski S., Slowinski T, Fischer T. Significant differentiation of focal breast lesions: calculation of strain ratio in breast sonoelastography. AcadRadiol. 2010;17(5):558–63
24. Cho N, Moon WK, Park JS, Cha JH, Jang M, Seong MH. Nonpalpable breast masses: evaluation by US elastography. Korean J Radiol 2008; 9:111-8
25. Okar Atabey A, Arıbal E, Ergelen R, Kaya H. Ultrason Elastografinin Meme Lezyonlarının Ayırıcı Tanısındaki Yeri ve Histopatolojik Korelasyon. J Breast Health 2014; 10:234-8.
26. Parajuly SS, Lan PY, Yun MB, Gang YZ, Hua Z. Diagnostic potential of strain ratio measurement and a 5 point scoring method for detection of breast cancer: Chinese experience. Asian Pac J Cancer Prev 2012;13:1447-52.
27. Yağtu M, Turan E, Öztürk Turan Ç. Meme Kitlelerinin Ayrıcı Tanısında US Elastografinin Rolü ve Klasik Ultrasonografik Değerlendirmeye Katkısı. J Breast Health 2014;10:141-6.
28. Zhu QL, Jiang YX, Liu JB, Liu H, Sun Q, Dai Q, Chen X. Real-time ultrasound elastography: its potential role in assessment of breast lesions. Ultrasound Med Biol. 2008;34(8):1232-8.
29. Daniel TG, Stamatia V, Richard G., Benjamin C. John G, Deborah J: US Elastography of Breast and Prostate Lesions Radiographics 2009;29:2007–16.
30. Yağtu M, Turan E, Öztürk Turan Ç. Meme Kitlelerinin Ayrıcı Tanısında US Elastografinin Rolü ve Klasik Ultrasonografik Değerlendirmeye Katkısı. J Breast Health 2014;10:141-6.
31. Kim MY, Cho N, Yi A, Koo HR, Yun BL, Moon WK. Sonoelastography in distinguishing benign from malignant complex breast mass and making the decision to biopsy Korean J Radiol 2013; 14:559-67.
32. Jackson VP. Management of solid breast nodules: what is the role of sonography? Radiology 1995;196:14–15., Hall FM. Sonography of the breast: controversies and opinions. AJR 1997;169:1635–6.
33. Stavros T, Thickman D, Rapp CL, Dennis MA, Parker SH, Sisney GA. Solid breast nodules: use of sonography to distinguish between benign and malignant lesions. Radiology 1995;196:123–34.

34. Rahbar G, Sie AC, Hansen GC, et al. Benign versus malignant solid breast masses: US differentiation. Radiology 1999;213:889–94.
35. Harper AP, Kelly-Fry E, Noe JS, Bies JR, Jackson VP. Ultrasound in the evaluation of solid breast masses. Radiology 1983;146:731–6
36. Gluseppetti GM, Martegani A, Di Cioccio B, Baldassarre S. Elasto¬sonography in the diagnosis of the noduler breast lesions: preliminary report. Radiol Med 2005; 110:69-76.