Original Research Paper

Volume : 5 | Issue : 11 | November 2016 • ISSN No 2277 - 8179 | IF : 3.508 | IC Value : 69.48

# Sacral parameter for sex determination in Navi Mumbai population.

Anatomy

**KEYWORDS:** Sacral morphometric study, Navi Mumbai population, Bone study, Sex determination.

**Pravin.R.Rathod** lecturer, Department of Anatomy, MGM Medical College, Navi Mumbai.

**Monali.D.Sonawane** Assisstant Professor, Department of Anatomy MGM Medical College, Navi Mumbai.

## ABSTRACT

*Sacrum is a large triangular bone. It is formed by fusion of five sacral vertebrae and forms the caudal end of the vertebral column. It forms posterosuperior wall of the pelvic cavity wedged between the two innominate bones.*[1]

*This study was carried on 60 human sacra (30 male and 30 female) which were collected from Department of Anatomy, MGM Medical College, Navi Mumbai.*

*The study showed significant p value for sacral and auricular length, with mean sacral length for males and females were 10.53 cm and 9.20 cm. Mean auricular length for males were 5.42 cm (right) and 5.41 cm (left), and mean auricular length for females were 3.45 cm (right) and 3.48 cm (left). Maximum sacral width and Antero posterior diameter for 1st sacral vertebra are other important parameters used for sex determination.*

**Introduction**

Sacrum has been studied extensively in the past research because of its important anatomical position at the caudal end of spinal cord and access for caudal epidural anesthesia. It's a fusion of sacral vertebrae and it is known for its developmental variation. Thus it becomes mandatory to study region wise for its clinical implication in various field of medical science. Thus our study is based on morphometric evaluation and best parameter for sexual differentiation in Navi Mumbai population

**Material and method**

Study was carried on 30 dry human sacra and 30 cadaveric sacral bones which were collected from Department of Anatomy, MGM Medical College, out of which 30 were males and 30, were females.

Cadaveric sacrum were dismantled from sacro iliac joint after dissection approach from gluteal region. Only sacra with complete sacral hiatus were taken for the present study. Damaged, mutilated and deformed sacra were excluded. Sacra exhibiting variations were not included in taking measurement.

**Parameters taken**

- Maximum sacral length: it is the maximum straight vertical height taken from mid ventral promontory to the apex of the sacrum in centimeter(cm)
- Maximum sacral width: it is calculated as maximum straight transverse length at the level of alae (cm).
- Maximum auricular length: it is the maximum vertical height of the auricular surface of sacrum (cm).
- Maximum auricular width: maximum transverse length of the auricular surface of the sacrum (cm).
- Maximum transverse diameter and antero-Posterior (AP) diameter of 1st sacral vertebral body (cm).

Findings:

1. Maximum sacral length and width
2. Maximum sacral length

**Table no.1-Maximum sacral length(cm)**

| Gender | Total | Mean | SD | p-value |
|---|---|---|---|---|
| Male | 30 | 10.53 | 1.18 | 0.000** |
| Female | 30 | 9.20 | 0.63 | |

***Significant at 5% level of Significance***

****Significant at 1% level of Significance***

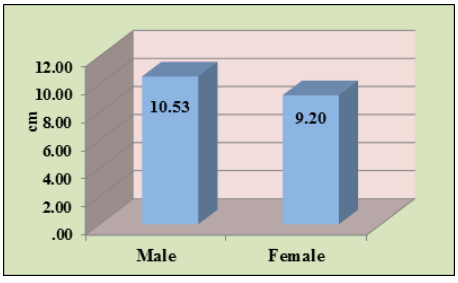


**Chart no. 1-Maximum sacral length(cm)**

b) Maximum sacral width

**Table no.2-Maximum sacral width (cm)**

| Gender | Total number | Mean | SD | p-value |
|---|---|---|---|---|
| Male | 30 | 9.59 | 0.70 | 0.788 |
| Female | 30 | 9.55 | 0.68 | |

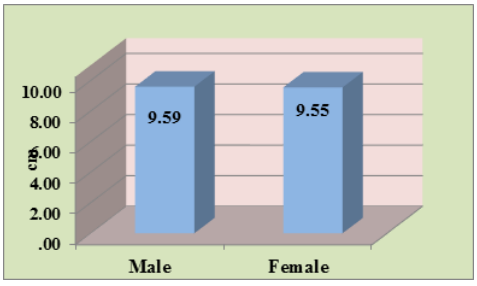


**Chart no.2-Maximum sacral width (cm)**

**2. Maximum auricular length**

**Table no.3-Maximum auricular length(cm)**

| Gender | | Right side | | | | Left side | | |
|---|---|---|---|---|---|---|---|---|
| | No. | Mean | SD | p-value | No. | Mean | SD | p-value |
| Male | 30 | 5.42 | 0.58 | 0.002** | 30 | 5.41 | 0.64 | 0.001** |
| Female | 30 | 4.98 | 0.49 | | 30 | 4.67 | 0.94 | |

Mean value of auricular length for right and left side was not significant but for sexual dimorphism it was more in males than females.

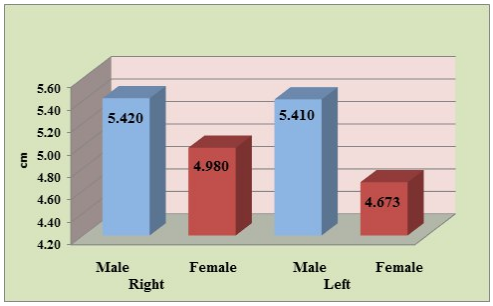


**Chart no 3-Auricular Length (cm)**

**3. Maximum auricular width**

**Table no.4-Maximum auricular width (cm)**

| Gender | Right side | | | Left side | | |
|---|---|---|---|---|---|---|
| | No. | Mean | P-value | No. | Mean | P-value |
| Male | 30 | 3.45 | 0.002** | 30 | 3.48 | 0.001** |
| Female | 30 | 3.38 | | 30 | 3.32 | |

Mean value of auricular width for both right and left were little higher in males then females.

**Chart no.4- Maximum auricular width (cm)**

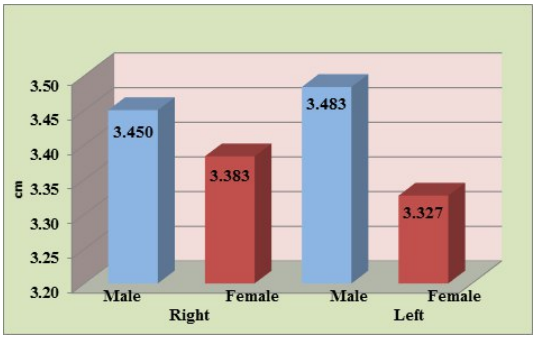


**4) 1st sacral vertebra**

a) Transverse diameter

Maximum transverse length of 1st sacral vertebra

**Table no.5-Transverse diameter of 1st sacral vertebra(cm)**

| Gender | No. | Mean | SD | P-value |
|---|---|---|---|---|
| Male | 30 | 4.71 | 0.83 | 0.553 |
| Female | 30 | 4.49 | 1.76 | |

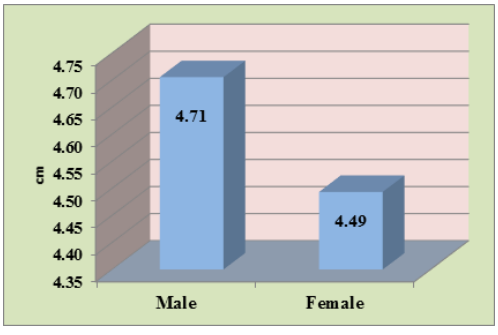


**Chart no.5- Transverse diameter of 1st sacral vertebra (cm)**

**b) Antero-posterior diameter**

Maximum antero posterior length of 1st sacral vertebra

**Table no.6-Antero-posterior diameter of 1st sacral vertebra(cm)**

| Gender | No. | Mean | SD | p-value |
|---|---|---|---|---|
| Male | 30 | 3.02 | 0.33 | 0.411 |
| Female | 30 | 3.30 | 1.81 | |

No statistical significant result was found in both genders for transverse and anteroposterior diameter of 1st sacral vertebra.

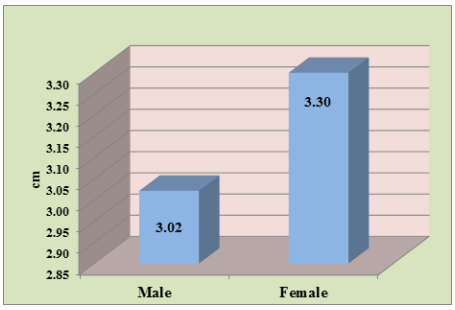


**Chart no.6- Antero-posterior diameter of 1st sacral vertebra (cm)**

**Results**

Mean **sacral length** for males and females was 10.53 cm and 9.20 cm (table no. 1). Mean sacral breadth in males was 9.59 cm and in females was 9.55 cm (table no. 2). Males had higher values then females. Mean **auricular length** for males was 5.42 cm (right) and 5.41 cm (left) with mean auricular width was 4.98 cm (right) and 4.67 cm (left).Mean auricular length for females was 3.45 cm (right) and 3.48 cm (left) with mean auricular width was 3.38 cm (right) and 3.32 cm (left) (table no 6,7).

Mean **transverse diameter** of 1st sacral vertebra in males was 4.71 cm and in females was 4.49 cm (table no 8) .Mean **anteroposterior diameter** of 1st sacral vertebra for males and females were 3.02 cm and 3.30 cm respectively (table no 8). Maximum sacral height, maximum sacral width, maximum auricular length, and antero posterior diameter for 1st sacral vertebra are important parameters used for sex determination. Mean sacral length with mean auricular length is significantly more in males than in females.

**Discussion**

Mean sacral length was 10.53 (male) and 9.20 (female) with significant *p* value. Our study showed higher value in males which match with Basaloglu et al[2] ,Vasantha M et al[3], Kanika S et al[4].Mean maximum sacral breath was 9.59 and 9.55 with no much significant *p* value. Males had higher values which match with rest of the previous study. Mean auricular length was higher for males with significant *p* value (0.001). Mean auricular width showed significant value in males and female with males having little higher value than females. It matched with Basaloglu et al[2] study.

Mean transverse diameter of 1st sacral vertebra was 4.71 and 4.49 in males and females. The values were higher than Basaloglu et al[2] study but matched with Kanika S et al[4] study. In all these studies males had higher values than females.

Mean maximum antero-posterior length of 1st sacral vertebra was 3.02 cm (males) and 3.30 cm (females) No statistical significant difference was found in both genders for transverse and anteroposterior diameter of 1st sacral vertebra.

**Conclusion**

Maximum sacral height, maximum sacral width, maximum auricular length, maximum auricular width ,transverse diameter of 1st sacral vertebra and antero posterior diameter for1st sacral vertebra are important parameters used for sex determination . Sacral height and auricular length had significant sex differential value in Navi Mumbai population with significant *p* value. Our findings matched with the previous studies, with values higher than Basaloglu et al [2] study for 1st sacral vertebral study. Mean sacral

Volume : 5 | Issue : 11 | November 2016 • ISSN No 2277 - 8179 | IF : 3.508 | IC Value : 69.48

length and mean auricular length would give accurate differentiation for sex in Navi Mumbai population which might be used for clinical purpose.

**Reference**


1. Standring S. Grays Anatomy, 39th Ed, Elsevier Churchill Livingstone, London, 2005;749-754
2. Senoglu N, Senoglu M, Oksuz H, Gumusalan Y, Yuksel KZ, Zencirci B et al. Landmarks of the hiatus for caudal epidural block: An anatomical study. British Journal of Anaesthesia 2005; 95 (5):692- 695.
3. Vasantha M, Ravinde M.Morphometric study of sacrum in sex determination in Telengana region people. Int J Res Med Sci. 2014; 2(1):164-174.
4. Kanika Sachdeva, Rajan Kumar Singla, Gurdeep Kalsey, Gaurav Sharma Role of Sacrum in Sexual Dimorphism-A Morphometric Study. J Indian Acad Forensic Med. July- September 2011, Vol. 33, No. 3