ORIGINAL RESEARCH PAPER

Volume-7 | Issue-1 | January-2018 | PRINT ISSN No 2277 - 8179

INTERNATIONAL JOURNAL OF SCIENTIFIC RESEARCH

SALVAGING A CASE OF TRAUMATISED MAXILLARY CENTRAL INCISOR WITH TWO CANALS –A CASE REPORT

Endodontic

Dr.Sandhya.A. Khasnis* Reader, Department of Conservative Dentistry and Endodontics, PMNM Dental College, Bagalkot-587101 *Corresponding Author

Dr. Prem P. Kar Senior Lecturer, Department Of Conservative Dentistry and Endodontics, PMNM Dental College, Bagalkot-587101

Dr. Rohit Nair Post graduate student, Department of Conservative Dentistry and Endodontics, PMNM Dental College, Bagalkot- 587101

Dr. JayaPrakash. D. Patil Professor and Head, Head of the Department, Department of Conservative Dentistry and Endodontics, PMNM Dental College, Bagalkot-587101

ABSTRACT

Root canal systems with abnormal variations present a challenge in diagnosis and clinical management to the practitioner. It is well known that maxillary incisors are usually single-rooted teeth. But there have been case reports in the literature for variations in the number of root canals in maxillary central incisors. Advancements in endodontics help to diagnose unusual anatomical variations. In this case report, magnification and Spiral CT are used during the diagnosis and treatment planning of an endodontically involved maxillary central incisor with two canals.

KEYWORDS

Maxillary central incisor, two canals, Spiral CT, endodontic treatment, magnification

Introduction

The key to successful endodontic treatment is accurate diagnosis, efficient cleaning and shaping and three dimensional obturation of the root canal system. Knowledge of normal and unusual anatomy of root canals is a prerequisite for successful endodontic outcome. Maxillary central incisors are the easiest teeth for root canal treatment due to the presence of single root and root canal, [1] variations in the number of roots and canals are not uncommon. [2-4] This case report presents a case of two rooted and two canalled maxillary central incisor, which is diagnosed with Spiral Computed Tomography and Dental Operating Microscope.

Case Report

A 37 year male patient was referred to Department of Conservative Dentistry and Endodontics, PMNM Dental college and Hospital, with a history of a dull pain in relation to the upper right anterior tooth. His medical history was non contributory. Patient reported with history of trauma to the upper right central incisor few years ago. Clinical examination showed discoloration of the crown, but no mobility. The tooth responded negatively with electric pulp and cold tests. However, the adjacent teeth responded to these tests within normal limits. Tooth was sensitive to percussion. The number of teeth in the dental arch was also normal. Radiographic examination clearly showed two separate roots with a wider distal and a narrow mesial canal [Fig 1a]. The periapical area of right central incisor depicted radiolucency. The CT examination was carried out to confirm this unusual morphology and related endodontic pathology. [Fig 1b,c,d]. After obtaining the patient's consent it was decided to perform nonsurgical root canal treatment. After rubber dam application, a conventional access opening was made under dental operating microscope at a magnification of 16X. (Surgiwell India). Fig 2a and 2b clearly show two separate orifices in 11. The distal canal, which was wider mesiodistally, was located with #15 K-file, immediately after deroofing of the pulp chamber. The mesial canal orifice was located close to the distal orifice, and mesial canal was negotiated by inserting # 10 K-file with a slight mesial orientation. Working length was estimated using an electronic apex locator Root ZX (J Morita Manufacturing Corporation, Kyoto, Japan) and then confirmed by radiography [Fig 2c]. In the first visit, canal was prepared with Protaper (Maillefer Dentsply India) Sx, S1and S2, with Glyde as a lubricant and with copious irrigation with 3% NaOCl. Calcium hydroxide intracanal medicament was placed in the canal. After a week, in the second visit, the canal was free of discharge and asymptomatic. The biomechanical preparation was continued with Protaper till F3 for mesial and F4 for the distal canal. The root canals were dried with paper points and obturation was performed using corresponding gutta-percha points with Apexit Plus root canal sealer. Access cavities were restored with GIC restoration Fig 2d.shows the final X-ray after root canal obturation. After 8 months, the patient has remained asymptomatic, and the follow-up radiograph revealed the healing process of periradicular radiolucency [Fig 2e].

Discussion

There is evidence in the literature for variations in the number of roots and root canals of maxillary central incisor. Sabala et al. [5] reported that tooth aberration occurs 90% bilateral, however Lin et al [6] mentioned that two-rooted maxillary central incisors were mostly unilateral. The present case also reports a unilateral maxillary central incisor with two roots. The probable etiology for such unilateral accessory roots may be the traumatic injury of primary teeth. Root duplication may occur following intrusive luxation of primary teeth, resulting in atraumatic division of the cervical loop and formation of two separate roots. In these cases, a mesial and a distal root can be detected on the radiograph. [7] The diagnosis of any other shape abnormality as germination or fusion was excluded, since according to Shäfer, [8] in case of germination, the tooth structure is usually one with two completely or incompletely separated crowns that have one root and root canal while in fusion, depending upon the stage of development of teeth at the time of union, a single large tooth with complete fusion or only the fusion of roots might occur. [5] It has been observed that the anomalies related to the number and distribution of roots and root canals have a tendency of occurring bilaterally, and the rarer the aberration, the more likely it is expected to be bilateral, [5] In the present case, the crown was normal in size hence germination and fusion were ruled out. This was confirmed with Spiral CT which clearly demonstrated two separate roots and root canals. It was confirmed clinically at 16x magnification [Fig 2a and 2b]. Conventional radiography may not always reveal the presence unusual anatomy due to the superimposition of anatomical structures. [9] Also it is a two dimensional image of a three dimensional structure. Angled radiographs, sudden disapppearnce in the continuity of root canal (fast break) may give a clue for additional canals. [1] Calcium hydroxide has been used as an intracanal medicament in this case due to its disinfecting properties owing to its high alkaline pH. [10]

Conclusion

The present case depicts the importance of identifying of aberrations and variations in the root canal anatomy of an otherwise simplest anatomical tooth like maxillary central incisor. Knowledge of the root canal anatomy, use of advanced diagnostic aids like, Computed tomography and dental operating microscope are most valuable in exploring hidden anatomical aberrations in complex endodontic cases.

Acknowledgements.

My sincere thanks to Dr. Shrinivas. S Vanaki, Principal, PMNM Dental

college, Bagalkot, Dr. R.S.Puranik, Professor and Head, Department of Oral Pathology and Secretary, Institutional Ethical Committee for their guidance and encouragement.

Also, would like to thank Chief librarian Mr. Santoshkumar Kotambari and Mr.Vijaykumar, for providing us with library facilities for this piece of research work.

The authors deny any conflicts of interests, Source of financial support, grants or funding.



(a)

Fig 1a- Preoperative radiograph showing maxillary right central incisor with two canals.

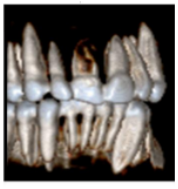

(b)

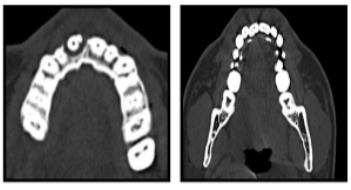

(c) (d)

Fig 1b, 1c, 1d- – Spiral CT image showing two roots and two canals in both maxillary central incisors.

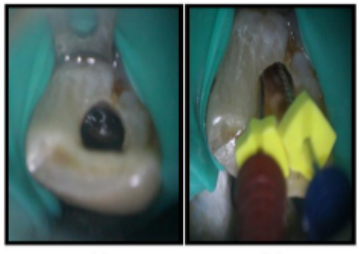

(a) (b)

Fig 2a,2b - Two separate orifices in maxillary central incisor at 16x magnification



(c)

Fig 2c -Working length determination



(d)

Fig 2d - Obturation



(e)

Fig 2e - Post operative radiograph of 8 months showing resolution of radiolucency

References

1. Burns RC HE. Tooth morphology and access cavity preparation. In: Cohen S BR, editor. Pathways of the pulp 8th Edition: St Louis, Mosby 2002: pp. 173-229.
2. Sheikh-Nezami M, Mokhber N. Endodontic treatment of a maxillary central incisor with three root canals. J Oral Sci. 2007;49:245-7.
3. Sinai IH, Lustbader S. A dual-rooted maxillary central incisor. J Endod 1984 Mar; 10: 105-06.
4. Libfeld H, Stabholz A,Friedman S. Endodontic therapy of bilaterally geminated permanent maxillary central incisors. J Endod 1986;12:214-6.
5. Sabala CL, Benenati FW, Neas BR. Bilateral root or root canal aberrations in a dental school patient population. J Endod 1994 Jan;20(1):38-42.
6. Lin WC, Yang SF, Pai SF. Nonsurgical endodontic treatment of a two-rooted maxillary central incisor. J Endod 2006 May;32(5):478-81.
7. Andreasen JO, Flores MT. Injuries to developing teeth. In: Andreasen JO, Andreasen FM, Andreasen L (Eds). Traumatic injuries to the teeth (4th ed). Blackwell Munksgaard 2007:551.
8. Rajendran A., Sivapathasundharam B. Shafer's Textbook of Oral Pathology, 7th ed. India: Elsevier; 2012. p. 40-1.
9. Gröndahl H-G, Huumonen S. Radiographic manifestations of periapical inflammatory lesions. Endodontic Topics 2004;8:55–67.
10. Saad AY. Calcium hydroxide in the treatment of external root resorption. J Am Dent Assoc. 1989;118(5):579-81.