VOLUME-6 | ISSUE-4 | APRIL - 2017 • ISSN No 2277 - 8179 | IF : 4.176 | IC Value : 78.46

Scaphoid non-union and results of the Match stick strut graft technique.

Orthopaedic

KEYWORDS: Scaphoid Fracture; Stable scaphoid non-union; Match stick strut graft; Lateral approach; Mayo wrist score.

Raju Karuppal	Additional professor, Dept of Orthopaedics, Govt.Medical College, Kozhikode, 673008, Kerala, India.
Sibin Surendran	Associate professor, Dept of Orthopaedics, Govt.Medical College, Kozhikode, 673008, Kerala, India.
Sabary Vaasan L	Senior Resident, Dept of Orthopaedics, Govt.Medical College, Kozhikode, 673008, Kerala, India.
Sandhya Somasundaran	Assistant Professor, Dept of Ophthalmology, Govt.Medical College, Kozhikode, 673008, Kerala, India

ABSTRACT

Background: To determine the results of match stick strut graft in stable scaphoid non-union.
Materials and Methods: In this prospective study, 40 patients with stable type non-union of fractures scaphoid were included. All of them were underwent the match stick strut graft. Union rate was evaluated four and six months after the procedure. Mayo wrist score (MWS) was calculated at six months and one year after surgery. **Results:** Mean age of the subjects was 26 ± 7.8 years, ranging from 18 to 35 years. Thirty-six (90%) were men, and four (10%) were women. Four and six months after surgery, 20 (50%) and 37 (92.5%) patients had achieved union respectively. Mean MWS was 75.0 ± 8.8 in all the patientss. Eight patients (20%) were grouped as excellent, 10 (25%) good, 18 (45%) satisfactory, and 4 (10%) poor. **Conclusion:** The match stick strut graft is an effective treatment of stable scaphoid non-union.

Background:

Scaphoid fracture is the most common type of carpal bone fractures. It commonly occurs after a fall on the outstretched hand or in a road traffic accident (1,2). Delay in the diagnosis and inadequate treatment of acute scaphoid fractures can lead to non-union, avascular necrosis and osteoarthritis. In patients with fractures in the waist of scaphoid or the proximal pole, union is more difficult. These areas of the scaphoid have a precarious blood supply. In acute fractures of less than one month old, a union rate of 95% can be achieved using common modalities of treatments. Though there are many new surgical methods have evolved in the treatment of fracture scaphoid, the rate of non-union remains as high as 10%. Scaphoid non-union can present with or without avascular necrosis of the proximal pole. Carpal collapse and degenerative arthritis are the two major sequelae of scaphoid non-union, causing personal and economic costs, and decrease in the hand function (3,4).

Surgical treatment of scaphoid non-union is targeted at correcting the deformity with open reduction and internal fixation by placing a Herbert screw / K wire in the scaphoid together with bone grafting (5) There are different types of bone graft, including nonvascularized (6) and vascularized bone grafts that have recently gained great popularity, particularly in those cases with avascular necrosis (2,7,8).

Internal fixation of the scaphoid using the Herbert bone screw though has fewer complications and appears to offer significant advantages over other methods of treatment it is technically demanding (9). Bone grafting for scaphoid fracture non-union is a well accepted method, with a high percentage of healing, reaching 90% to 95% (10, 11,12).

Studies showed the Matti-Russe method, and it proved to be a good method for the treatment of scaphoid nonunion, showing high percentages of healing and functional improvement (13-16). In Matti-Russe technique, Screw/Kwire application is avoided, hence the need for a second operation for screw removal is not required and the risk of infection is also minimized (17). In the classic Matti-Russe technique,the graft bed is prepared through the cartilage over the non-union site, hence it will cause articular cartilage damage and can negatively affects the functional result. Moreover bone graft is harvested from the iliac crest which has the increased risk of donor site morbidity (18, 19).

In stable type of Scaphoid non union (Mack-Lichtman type I) , axial drilling and match stick strut grafting is a simple and inexpensive technique. The match stick strut graft provides both mechanical stability and enhances bone healing. We evaluated the results of this technique in our patients who underwent match stick strut graft through lateral approach in stable scaphoid non-union.

Objectives

The purpose of this study was to assess the results of match stick strut graft through lateral approach on the wrist function and radiographic union in patients with stable scaphoid non-union.

Patients and Methods

The cohort consisted of 40 consecutive patients treated by the authors at Government Medical College Kozhikode between October 2009 and March 2015. Their data were collected prospectively and the study was approved by the ethical committee. All the patients received match stick strut graft through lateral approach for stable scaphoid waist nonunion at our institution. The inclusion criteria were scaphoid waist non-union and sclerosis/ cystic changes without malalignment and avascular changes.

Exclusion criteria were: 1) unstable scaphoid nonunion, 2) carpal arthritis and carpal collapse sign 3) radiographic signs of avascular necrosis 4) humpback deformity and 5) follow-up less than six months.

The cases were selected after confirming the diagnosis with plain radiographs and MRI. All surgical procedures were performed by the same surgeon (RK) after informed consent was obtained from all patients. Clinical and functional outcomes were assessed by an independent observer who did not participate in the surgical procedure. Range of motion of wrist joint was measured using a hand-held goniometer. We accepted the union when there was no tenderness at the anatomical snuffbox and there was evidence of bony trabeculae crossing the non union site. We evaluated the union in our patients on four and six months after surgery. The patients were assessed based on the Mayo wrist score (MWS) questionnaire on a follow-up after six months. The questionnaire consists of questions assessing pain intensity, functional status, range of motion, and grip strength. Scores are recorded in four groups: 90-100: Excellent, 80-90: Good, 60-80: Satisfactory, below 60: poor.

Pain was categorized in to four levels which includes; no pain, mild occasional, moderate tolerable, and severe to intolerable. Physical activity level was also categorized as returned to regular employment restricted employment, and able to work but unemployed. Range of motion in dorsiflexion, palmar flexion, radial flexion, and ulnar flexion in the affected wrist was measured using a goniometer, and

was reported as a percentage. Grip strength was measured using a Jamar hydraulic hand dynamometer. Union rate was evaluated at twelve, eighteen and twenty four weeks after the procedure. Mayo wrist score (MWS) was calculated for the patients six months and one year after surgery. All the measurements were performed preoperative and at the subsequent follow-ups.

Statistical analysis was performed using SPSS (version 18, Chicago, IL, USA). Data are expressed as mean ± standard deviation for numerical variables and as percent (%) for categorical variables. Independent t-test, paired t-test, and Chi-square were used to analyze the data.

Surgical Technique

All cases were performed with tourniquet on upper arm, under regional block anaesthesia (Supraclavicular). True lateral approach was used (Figure 1). A 4 cms long skin incision was made on the lateral aspect of wrist joint beginning 1 cm proximal to the tip of radial styloid process.



Figure 1: True lateral approach made on the wrist.

Scaphoid was exposed between the first and third extensor compartments (anatomical snuff box) by meticulous dissection, preventing injury to the radial artery and its branches to the scaphoid. A thin curved bone lever is placed at the radio-scaphoid joint for better visualisation of scaphoid (Figure 2).



Figure 2: A thin curved bone lever is placed at the radio-scaphoid joint for better visualisation of scaphoid.

Non union site is visualised. In case of difficulty in localisation, we used operative fluoroscopy with a thin K wire (1.2 mm) to find the fibrous non union site. Under fluoroscopic guidance a 1mm guide wire was passed either using the free hand method or with the help of an alignment guide of Herbert screw through the long axis of the scaphoid. A tunnel was then drilled over the guide wire using cannulated drill bit. The non union site/ cystic cavity were freshened through the tunnel. Match stick strut graft is taken from the radial styloid (Figure 3) through the same incision using narrow osteotomes.



Figure 3: Match stick strut graft was taken from the radial styloid.

It was prepared and pushed into the scaphoid across the nonunion site through the tunnel. The width and length of the graft should be matching to the diameter and length of the tunnel prepared to achieve a tight fit. In cases of cystic type of non-union, the cavity was packed with cancellous graft (taken along with the match stick graft bed) before we pushed the match stick graft. Care was taken not to break the match stick graft while insertion. In rare occurrence of strut graft breakage, another graft of similar dimension was harvested from the same site. The wound was closed in layers and wrist was immobilized in a short-arm thumb spica cast. Sutures were removed after two weeks. After twelve weeks of operation, the cast was removed and postero-anterior (PA) and lateral radiographs were obtained. If bridging bone was not identified by 12 weeks, a short-arm thumb Spica splint was applied for an additional four weeks. If bridging bone was not identified by 18 weeks, we considered the treatment as failure. Patients with union were followed up every three months and wrist range of motion and grip strength and plain radiographs were evaluated at the final follow up of one year (Figure 4).



Figure 4: (a) Cystic type of non union. (b)Radiological union achieved at 16 weeks. (c and d) Treated case shows near normal wrist dorsiflexion and palmar flexion.

Results

A total of 40 patients who underwent match stick strut graft through lateral approach for stable scaphoid non –union were evaluated in this study. Mean age of the patients was 26 ± 7.8 years, ranging from 18 to 35 years. Thirty-six (90%) were men, and four (10%) were women (Table 1).

Table 1: Demographic characteristics of the study group.

	Total	male	female
No of patients	40	36 (90%)	4 (10%)
10 – 20 years	20 %	8	0
21 – 30 years	45 %	16	2
31 – 40 years	35 %	12	2
Mean age of the patients	26 ± 7.8 years,	18 - 35 years	22 -32 years
Average duration of symptoms	20.6 months	22 months	19.2 months
The mean follow-up	13 months	6 - 18 Months	6-24 Months

The mean follow-up was 13 months (ranged 6 - 18 Months).Four and six months after surgery, 20 (50%) and 37 (92.5%) subjects had a united fracture. The mean flexion/extension of the wrist was 70 degrees (ranged 50 - 160 degrees) in comparison with the pre-operation 52 degrees (ranged 35 - 160 degrees) ($P < 0.04$) at the end of one year. Grip strength at final follow-up averaged 28 kg (ranged 12 - 455 kg) indicating a significant improvement from 20 kg (ranged 5 - 41 kg) preoperatively ($P < 0.026$). Mean MWS was 75.0 ± 8.8 in all the subjects, ranging from 54 to 90 six months after surgery. Eight subjects (20%) were grouped as excellent, 10 (25%) good, 18 (45%) satisfactory, and 4 (10%) poor. (Table 2)

Table 2: Mayo wrist score in the study group of 40 patients six months after surgery.

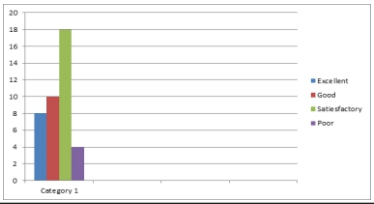

VOLUME-6 | ISSUE-4 | APRIL - 2017 • ISSN No 2277 - 8179 | IF : 4.176 | IC Value : 78.46

All patients achieved a successful bony union by a mean 3.2 months (ranged 3 - 4.5 months). Sixteen weeks after surgery [Table 3],

Table 3: Union rate four and six months after surgery according to crossing of bony trabeculae

Union according to crossing of bony trabeculae	Months		Total
	Four	six	
Yes	38 (95%)	1 (2.5%)	39(97.5%)
No	2 (5%)	1 (2.5%)	1 (2.5%)

fracture in 38 patients (95%) was united, and there were 2 cases of delayed union which was further immobilised for additional four weeks. One of the cases united at the end of 20 weeks. The second case was radiologically not united but clinically asymptomatic. Mean age of the patients was not statistically different between the united and delayed united groups. We had complications like neuropraxia of radial cutaneous nerve injury in one case (2.5%) which was recovered over a period of three weeks, strut graft breakage in one case (2.5%) where we harvested another graft of similar dimension from the same site and one case (2.5%) of radiological non-union. We didn't have complications like radial artery injury, tendon injury or wound infection.

Discussion

There are various methods of surgical treatment for non union scaphoid. Some of them with metallic implants and others with bone graft alone. Bone grafting for the non union of scaphoid was first reported by Adams and Leonard in 1928. The match stick strut graft in stable scaphoid non union provides a good biological milieu for the union with added mechanical stability without any metallic implants. Many of the complications of scaphoid fracture surgeries are in relation to the metallic implant used. Our technique avoids all the complications related to the metallic implants and future surgery for implant removal, if needed.

The present study showed a significant improvement with management of the stable non-union of scaphoid in Grip strength and flexion/extension of the wrist. The functional outcomes in our patients after bony union were excellent or good like Kim et al. (22) report. We had a union rate comparable to vascular bone graft technique that produced a 90% - 100% union rate. This may be attributed to the stable type of non union cases we selected and the biological environment by the match stick strut graft to enhance the union (23). Our study showed a bony union of 97.5% with only 2.5% of non union. The overall complication rate was 2.5%, which was comparable to other studies. Slade and Gillon (24) reported a 96% union rate and 9% complication rate of non-union group by nine months in scaphoid nonunions treated with arthroscopic method. In another study performed by Kolodziej et al. (25), nonunion rate of 28% after a long-term follow-up of 2 - 27 years (mean: 8.8 years) by the Matti-Russe method with no complication. Curettage of non union site is probably important in treating stable scaphoid nonunion and usually performed with cortical window at the nonunion site (26). But in our method we approached it through the tunnel made on the non articular area of the scaphoid hence we could preserve the cartilage and achieved good function. The stable scaphoid non-union should also be further stabilised to resist complex forces during normal functional loading (shearing or translation forces) (27, 28). We immobilised the limb in a scaphoid cast for twelve weeks to provide added stability at nonunion site.

In this study, we used match stick strut graft for non-union fixation and found it to provide adequate stability in stable scaphoid non-union. The match stick strut graft provides both mechanical stability and enhances bone healing. In addition, we can fill the non-union site with cancellous graft taken from the same donor site. Furthermore, failure to unite with this technique doesn't prevent a revision procedure with screw fixation in conventional manner as there is no metallic implant and very little bone loss. This study also shows that the match stick strut graft is a reliable and inexpensive method for the treatment of stable scaphoid non-union, showing high percentages of healing and functional improvement. It is an effective alternative to conventional methods with few complications.

Limitation

This study had few limitations. The number of cases was relatively small and there was no control group. This is due to the low prevalence of stable non-union scaphoid cases. CT scan was not used as a definitive tool for assessing union due to the poor socioeconomic status of the patients.

References:

1. Raju P, Kini SG. Fixation techniques for non-union of the scaphoid. J Orthop Surg (Hong Kong) 2011; 19:80-4.
2. Pao VS, Chang J. Scaphoid non-union: Diagnosis and treatment. Plast Reconstr Surg 2003; 112:1666-77.
3. Triantafillopoulos I, Zoubos A, Babis G, Soucacos P. Orthopaedica et Traumatologica Hellenica. J Hellenic Ass Orthop Traumatol 2005;56.
4. Herbert TJ, Fisher WE. Management of the fractured scaphoid using a new bone screw. J Bone Joint Surg Br 1984; 66:114-23.
5. Reigstad O, Thorklidsen R, Grimsgaard C, et al. Healing of ununited scaphoid fractures by Kirschner wires and autologous structural bone grafts. Scand J Plast Reconstr Surg Hand Surg. 2010; 44(2):106–11.
6. Matti-Russe bone grafting)and vascularized bone grafts (Zaidemberg et al Zaidemberg C, Siebert JW, Angrigiani C. A new vascularized bone graft for scaphoid nonunion. J Hand Surg [Am] 1991; 16: 474–478.
7. Maruthainar N, Rasquinha V, Gallagher P. The treatment of scaphoid non-union: A review of a novel technique using precision bone grafting compared with Herbert screw fixation and bone graft. J Hand Surg Br 2000;25:427-30.
8. Kawamura K, Chung KC. Treatment of scaphoid fractures and non-unions. J Hand Surg 2008;33:988-97.
9. Filan S, Herbert T. Herbert screw fixation of scaphoid fractures. J Hand Surg Br 1996; 78:519-29.
10. Cooney WP. Bone grafting techniques for scaphoid nonunion. Techniques in Hand and Upper Extremity Surg. 1997;1:148–67
11. Doi K, Oda T, Soo-Heong T, Nanda V. Free vascularized bone graft for nonunion of the scaphoid. J Hand Surg Am. 2000;25:507–19.
12. Ritter K, Giachino AA. The treatment of pseudarthrosis of the scaphoid by bone grafting and three methods of internal fixation. Can J Surg. 2000; 43(2):118–24.
13. Triantafillopoulos I, Zoubos A, Babis G, Soucacos P. Orthopaedica et Traumatologica Hellenica. J Hellenic Ass Orthop Traumatol 2005;56.
14. Stark A, Broström L, Svartengren G. Scaphoid non-union treated with the Matti-Russe technique. Long-term results. Clin Orthop Relat Res 1987; 214:175.
15. Mulder J. The results of 100 cases of pseudarthrosis in the scaphoid bone treated by the Matti-Russe operation. J Hand Surg Br 1968;50:110-5.
16. Panchal A, Kubiak EN, Keshner M, Fulkerson E, Paksima N. Comparison of fixation methods for scaphoid nonunions: A biomechanical model. Bull NYU Hosp Jt Dis 2007; 65:271-5.
17. Jiranek WA, Ruby LK, Millender LB, et al. Long-term results after Russe bone grafting: the effect of malunion of the scaphoid. J Bone Joint Surg Am. 1992; 74:1217–28.
18. Stark A, Brostrom LA, Svartengren G. Scaphoid nonunion treated with Matti-Russe technique. Long-term results. Clin Orth. 1987; 14:175–80.
19. Russe O. Fracture of the carpal navicular: diagnosis, non-operative treatment, and operative treatment. J Bone Joint Surg Am. 1960; 42:759–68.
20. Mack GR, Kelly JP, Lichtman DM. Scaphoid non-union. In: Lichtman DM, Alexander AH, editors. The wrist and its disorders. Philadelphia: Saunders; 1997. pp. 234–67.
21. Markiewitz AD, Stern PJ. Current perspectives in the management of scaphoid nonunions. Instr Course Lect. 2005; 54:99–113.
22. Kim JP, Seo JB, Yoo JY, Lee JY. Arthroscopic management of chronic unstable scaphoid nonunions: effects on restoration of carpal alignment and recovery of wrist function. Arthroscopy. 2015; 31(3):460–9.
23. Braga-Silva J, Peruchi FM, Moschen GM, Gehlen D, Padoin AV. A comparison of the use of distal radius vascularised bone graft and non-vascularised iliac crest bone graft in the treatment of non-union of scaphoid fractures. J Hand Surg Eur Vol. 2008; 33(5):636–40.
24. Slade J3, Gillon T. Retrospective review of 234 scaphoid fractures and nonunions treated with arthroscopy for union and complications. Scand J Surg. 2008; 97(4):280–9.
25. Kolodziej RK, Blacha J, Bogacz A, Mazurkiewicz T. Long-term outcome of scaphoid nonunion treated by the Matti-Russe operation. Ortop Traumatol Rehabil. 2006; 8(5):507–12.
26. Buijze GA, Ochtman L, Ring D. Management of scaphoid nonunion. J Hand Surg Am. 2012; 37(5):1095–100.
27. Kaneshiro SA, Failla JM, Tashman S. Scaphoid fracture displacement with forearm rotation in a short-arm thumb spica cast. J Hand Surg Am. 1999; 24(5):984–91. 19.
28. McAdams TR, Spisak S, Beaulieu CF, Ladd AL. The effect of pronation and supination on the minimally displaced scaphoid fracture. Clin Orthop Relat Res. 2003 ;(411):255–9.