Original Research Paper

Volume : 5 | Issue : 7 | July 2016 • ISSN No 2277 - 8179 | IF : 3.508 | IC Value : 69.48

Segmentation of Blood Vessels and Optic Disc from Retinal Images

Medical Science

KEYWORDS :

D.KSreepathi	Senior Consultant, Dr.Agarwal's Eye Hospital, Bangalore, Karnataka
*** Heber Anandan**	Senior Clinical Scientist, Department of Clinical Research, Dr.Agarwal's Eye Hospital, Tirunelveli, Tamilnadu * Corresponding Author
Nageswari	P.G. Scholar in Applied Electronics, Sathyabama University, Chennai, Tamilnadu
J.L Dhanisha	Research Optometrist, Dr. Agarwal's Eye Hospital, Tirunelveli, Tamilnadu

ABSTRACT

The aim of this survey is to list the various disease predictions from retinal fundus images and various methods used to detect the disease. This paper gives a detailed description about the various diseases predicted in retina by comparing retinal fundus image structure. Next, a comparitive study of the various methods followed using image processing to find out the disases from retinal fundus images is provided. The survey at the end, discusses the future work for the possibilities of predicting gastreointestinal problems via retinal fundus images.

1. Introduction

With the advancement in biometric technology, by using image processing techniques, the diseases that lead to death can easily be predicted via retinal fundus images by using image processing techniques. Retinal images are used to predict various diseases. The accuracy of disease prediction is based on the techniques used. For various diseases, various methods were used. So far, Diabetic, Stroke, Blindness due to glaucoma, Cardio Vascular Disease (CVD), Coronary Heart Disease (CHD), Hypertension, Macular Edema had been predicted using retinal fundus images.

2. Retinal images

Normal retina with no disease is shown in Fig.1.



Fig. 1 Normal Retina

2.1 Diabetic Retinopathy affected retina:

Nowadays, diabetes is seen in 9 out of 10 persons. It can be detected in early stage by diabetic retinopathy. Diabetic retinopathy (DR) also known as diabetic disease that when damage occurs to the retina due to diabetes. It can lead to blindness. It affects up to 80% of people who have diabetes [1]. If they were diagnosed properly 90% of people can be saved from blindness. Fig. 2 shows the affected retinal fundus image.



Fig. 2 Diabetic Retinopathy affected Retina

Diabetic Retinopathy is having two major stages fig. 3.

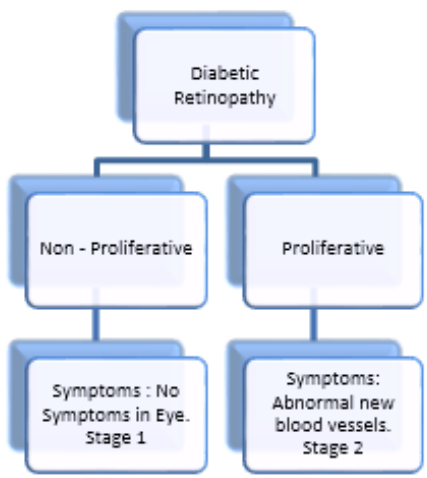

Fig. 3 Two stages of DR

The retinal images that shows the two stages is shown in the following fig. 4

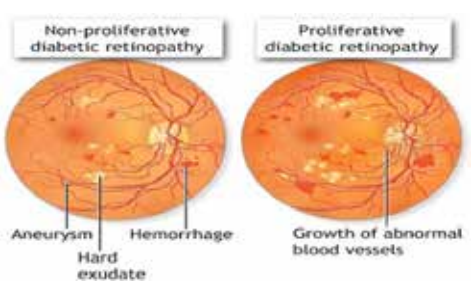

Fig. 4 Retina of two stage DR

2.2 Glaucoma affected retina:

Following fig. 5 shows the normal eye structure with the area where glaucoma occurs.

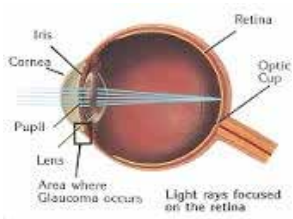

Fig. 5 area where glaucoma occurs

The reason for glaucoma is loss of retinal nerve fiber layers due to increase in intra ocular pressure inside the eye lead to blindness. In India 11 million people are affected by glaucoma [2].

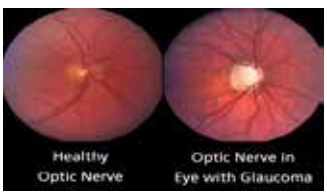

Fig. 6 Glaucoma affected retina

Hypertensive retinopathy affected retina:

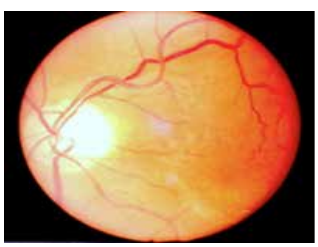

Fig. 7 Hypertensive retina

Macular Edema affected Retina:



Fig. 8 Macular Edema retina

2.3 Stroke affected Retina:

An eye affected due to stroke is also known as a retinal artery occlusion caused by a blockage in the blood vessels due to blood clot or build up of cholestrol in blood vessel. Fig. 9 shows the retinal image of stroke prediction.

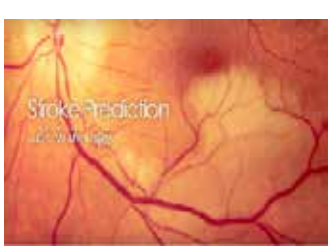

Fig. 9 Stroke prediction

Branch retinal vein occlusion (BRVO) is a blockage in the small veins in retina.

Central retinal vein occlusion (CRVO) is a blockage of the main vein in retina.



Fig. 10 Blood vessel leakage

2.4 Cardio Vascular Disease (CVD) affected retina:

If cholestro block in blood vessel may lead to cardio vascular disease. Fortunatly eye is the window for heart disease. Fig. 11 shows the retina affected by cardio vascular disease.



Fig. 11 Retina affected by CVD

3. Disease Prediction using retinal images

Via retinal images, many diseases can be detected in the early stage. For this, the technique used is image processing on retinal fundus images. Fundus means interior surface of the eye [4].

3.1 Image processing for predicting diseases:

The steps involved are disease diagnosis, disease prediction and disease progress monitoring.

Disease Diagnosis: Detecting abnormal symptoms in the retina.

Disease Prediction: Observing retinal disorders and related diseases or blindness.

Disease Progress Moitoring: Particular interval of time monitor the affected retinal fundus images.

3.2 Various Segmentations in retinal fundus images:

To identify the disease, various segmentations are applied such as segmenting optic disc, macula and fovea and blood vessels.

Segmenting optic disease is used to find the diabetic retiopathy and glaucoma.

Segmenting Macula and Fovea is used to find the macular degeneration and macular edema.

Segmenting blood vessels is used to find out the hypertension, cardio vascular disease and stroke.

3.3 Architecture of Retinal image processing:

The procedures applied for processing the retinal fundus images are shown in the fig. 12.

Volume : 5 | Issue : 7 | July 2016 • ISSN No 2277 - 8179 | IF : 3.508 | IC Value : 69.48

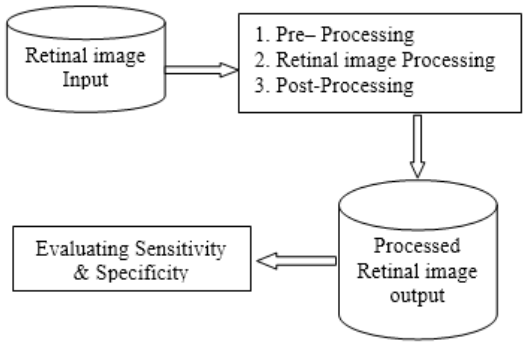

Fig. 12 Architecture of Retinal image processing

3.4 Datasets used for retinal images:
First of all, the retinal images are the datasets considered as primary input for any disease prediction. The most widely used datasets[4] are listed below.

STARE

DRIVE

ONHSD

ARIA

IMAGERET

STARE : STructured Analysis of the REtina[6]

DRIVE : Digital Retinal Images for Vessel Extracion [7]

ONHSD : Optic Nerve Head Segmentation Dataset [8]

ARIA : Automatic Retina Image Analysis [9]

3.5. Accuracy of Segmentation:
The parameters used are size, shape area of the input image to evaluate the segmentation accuracy. This is done by true data which is manually defined by human observers. Thus, once the true data is available, a variety of metrices can be used to evaluate the segmentation process.

3.6. Image Preprocessing for Enhancement:
First of all, the image is enhanced before any process. For that, MATAB is used. Because, the images may be in poor quality due to patient's movement and iris color, as well as non uniform illumination.

The main preprocessing techniques are Mask Generation, Color Channels Processing, Color Normalization and Contrast Enhancement [12].

MASK GENERATION:



Fig. 13 a) color image b) mask c) excluded background

COLOR CHANNEL PROCESSING:

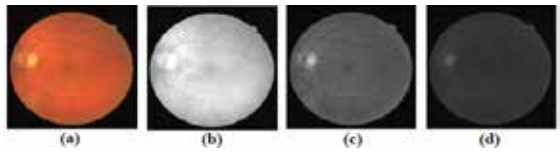

Fig. 14 a) original imag b) red c) green d) blue channels

COLOR NORMALIZATION:

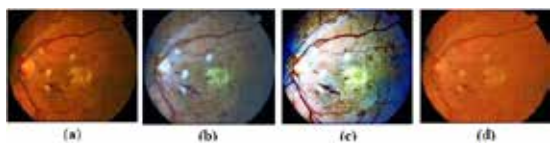

Fig. 15 Color normalization on abnormal retina

CONTRAST ENHANCEMENT:

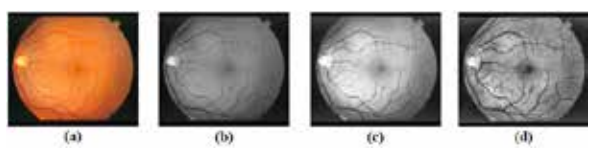

Fig. 16 Contrast Enhancement a) Input image b) green band
c) Histogram equalization d) CLAHE of (b)

3.7 Segmentation of Optic Disc:
Optic disc is found in the right-hand or left-hand side of the fundus image. Optic disc is in oval or round in shape and one sixth of the width rang approximately 2mm in diameter [14].

Analyzing the properties of optic disc serves as an indicator of various disease predictions. The centroid of optic disc is optic cup and the centroid covered with rim. The ratio between the optic cup and rim (fig. 17) is an important metrice for disease prediction.

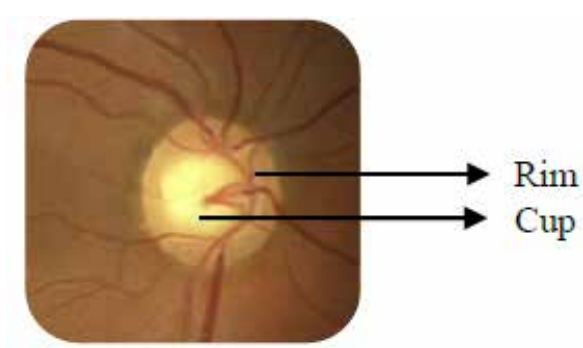

Fig. 17 optic disc cup and rim

4. Discussion and Future Work
An automated method to detect diabetic retinopathy with non-dilated pupil is done by Fuzzy C-means (FCM) clustering [5]. One main weakness of the algorithm is that it depends on the detection of optic disc and vessel removal. If it requires more accuracy the algorithm can be used with morphological techniques.

The performance of the segmentation method is evaluated using the metrices sensitivity and accuracy. The chart (fig. 17/) explains the various segmentation algorithms for sensitivity and accuracy.

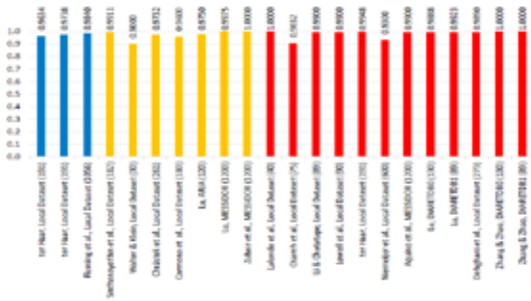

Fig. 17 sensitivity of various algorithm

Blue bar – vessel convergence method

Yellow bar – property based method

Red bar – template based method

In the future, by using these matrices, identifying the gasterointestinal disease via the fundus images is possible. By applying advanced technique of segmentation and fuzzy algorithms it can be easily identified. Due to gastrointestinal problem if there exist any change in the eye, the disease can be easily rectified from the initial stage. For this, fundus images of retina of gastro patients will be compared with the normal retinal images. Then find out the factor that is varying in the two images.

5. Conclusion

In this survey, the various factors used for the disease prediction via colour fundus image of retina is studied. The parameters that are used to detect the disease in the earlier stage is compared with various algorithms and methods followed to detect the disease. From this survey, publicly available databases were shown. This survey will be a great help for the future work of predicting the gastrointestinal image via retinal fundus image.

References

[1] Sumeet Dua, Naveen Kandiraju, Hilary W. Thompson., "Design and Implementation of a Unique Blood-vessel Detection Algorithm towards Early Diagnosis of Diabetic Retinopathy" IEEE International Conference on Information Technology: Coding and Computing (ITCC'05).

[2] Pavitra, T.C. Manjunath, Dharmanna Lamani and S. Chandrappa, Ranjan Kumar H.S., "Different clinical parameters to diagnose Glaucoma Disease: A Review" International Journal of Computer Applications(0975 – 8887), Vol. 116, No. 23, April 2015.

[3] Mark Christopher, Michael D. Abramoff, et al. "Stereo Photo measured ONH shape predicts development of POAG in subjects with ocular Hypertension" The Association for Resarch in vision and Ophthalmoogy.

[4] Ali Mohamed Nabil Allam, et al. "Automatic Segmentation of Optic Disc in Eye Fundus Images: A Survey" Electronic letters on computer vision ad image Analysis" 14(1): 1-20, 2015.

[5] Akara Sopharak, Bunyarit Uyyanonvara, Sarah Barman, "Automatic Exudate Detection from Non-Dilated Diabetic Retinopathy Retinal Images Using Fuzzy C – means Clustering". Sensors 2009,9(3), 2148 – 2161; DOI 10.3390/s90302148.

[6] M. Goldbaum, "The STARE Project," 2000. [Online]. Available:http://www.parl.clemson.edu/~ahoover/stare/index.html. [Accessed 28 July 2013].

[7] J. J. Staal, M. D. Abramoff, M. Niemeijer, M. A. Viergever and B. van Ginneken, "Ridge Based Vessel Segmentation in Color Images of the Retina," IEEE Trans. Med. Imag., vol. 23, pp. 501-509, 2004. DOI: 10.1109/TMI.2004.825627

[8] MESSIDOR - TECHNO-VISION Project, "MESSIDOR," 28 March 2008. [Online]. Available: http://messidor.crihan.fr. [Accessed 31 July 2013].

[9] J. Lowell, A. Hunter, D. Steel, B. Ryder and E. Fletcher, "Optic Nerve Head Segmentation," IEEE Trans. Med. Imag., vol. II, no. 23, 2004. DOI: 10.1109/TMI.2003.823261.

[10] Y. Zheng, M. H. A. Hijazi and F. Coenen, "Automated Disease/No Disease Grading of Age-Related Macular Degeneration by an Image Mining Approach," Investigative Ophthalmology & Visual Science, vol. 53, no. 13, pp. 8310-8318, November 2008. DOI: 10.1167/iovs.12-9576.

[11] D. J. J. Farnell, F. N. Hatfield, P. Knox, M. Reakes, S. Spencer, D. Parry and S. P. Harding, "Enhancement of blood vessels in digital fundus photographs via the application of multiscale line operators," J. Franklin Institute, vol. 345, no. 7, pp. 748-765, October 2008. DOI: 10.1016/j.patrec.2006.09.007.

[12] K. A. Goatman, A. D. Whitwam, A. Manivannan, J. A. Olson and P. F. Sharp, "Colour Normalisation of Retinal Images," Proc. Medical Image Understanding Analysis, 2003.

[13] F. A. Hashim, N. M. Salem and A. F. Seddik, "Preprocessing of Color Retinal Fundus Images," in IEEE 2013 2nd Int. Japan-Egypt Conf. Electron. Commun. Comput., 2013. DOI: 10.1109/JEC-ECC.2013.6766410

[14] F. ter Haar, "Automatic localization of the optic disc in digital colour images of the human retina," 2005.

[15] Parul, Mrs. Neetu Sharma, "A segmentation improved statistical model for retinal disease identification", International Journal for innovative Research in Science & Technology Vol. 2 2349 – 6010 June 2015.