ORIGINAL RESEARCH PAPER

Volume-8 | Issue-1 | January-2019 | PRINT ISSN No 2277 - 8179

INTERNATIONAL JOURNAL OF SCIENTIFIC RESEARCH

SKIN ADNEXAL TUMORS-A FIVE YEARS STUDY IN A TERTIARY CARE HOSPITAL

Pathology

Dr G Sudhakar M. D (Pathology), Associate Professor, Department of pathology, Guntur Medical ollege, Guntur

Dr.M.Koteswari* Assistant Professor, Department of pathology, Guntur Medical College, Kannavari thota, Guntur-522004,AP *Corresponding Author

ABSTRACT

Skin adnexal tumors are very difficult to diagnose and most of the benign tumors present as asymptomatic lesions. Malignant skin adnexal tumors are rare and they exhibit more aggressive clinical course and have potential of metastasis. So it is important to diagnose benign and malignant nature of lesion. Histopathlogical examination along with clinical findings like anatomic location, number and distribution of lesions helps in diagnosis of skin adnexal lesions. Microscopic architectural features are most important in differentiating benign and malignant tumors. Immunohistochemistry may helps in confirmation of the diagnosis.

KEYWORDS

adnexal tumors of skin, benign, histopathology, malignant

INTRODUCTION

Skin adnexal tumors arises from multipotent stem cells present in skin and adnexa, these tumors express one or more lines of appendageal differentiation to exhibit histological features analogous to hair follicles, sebaceous glands, and eccrine,apocrine sweat glands[1,2]. Diagnosis principally depends on histopathology and they are classified according to predominant morphological component. So broadly skin adnexal tumors are classified into tumors with apocrine and ecrine differentiation, tumors with follicular differentiation, tumors with sebaceous differentiation[1,2,3].

Most of benign tumors are smooth surfaced, symmetrical papules or nodules the same colour as patients skin or darker. Malignant tumors are rare compared to benign counterparts and irregularly shaped, and ulcerated. Adnexal carcinomas of low cytological grade have good prognosis if lesion is small and completely excised[3,4]. Those with high cytological grade may metastasize widely and exhibit more aggressive clinical course. Presence of Multiple tumors can be considered as marker for visceral malignancy e.g. multiple trichilemmoma in breast malignancy[4,5].

AIMS & OBJECTIVE

To study the histopathological nature and to correlate incidence, age, sex and location of skin adnexal tumors with other studies.

MATERIAL & METHODS

This is a retrospective study. Adnexal tumours reported from July 2013 to July 2018 in the department of pathology in our institute were included in the study. Skin adnexal tumors were 68 out of 26875 total biopsies received. All slides stained with routine hematoxylin & eosin and special stains accordingly. In this study we have analyzed the frequency and microscopic features with differentiating features to avoid potential pitfalls between benign and malignant skin adnexal tumors .

RESULTS

Incidence out of total biopsies received from July 2013 to July 2018 in the department of pathology was 26875.Among them 68 were skin adnexal tumors comprising 0.25%. Age groups ranging from 10-90 years and common age group was 51-60 years .Among all cases male are 53.4% and Female were 46.6% with Male female ratio-1.14:1[Figure 1].

Figure 1: Sex ratio of skin adnexal tumors

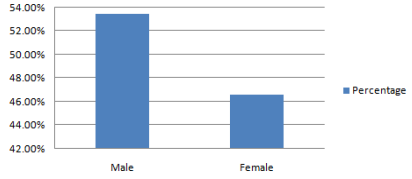

Most common site of skin adnexal tumors is head and neck, account for 64%,followed by trunk and upper limb 29%,abdomen and lower limb 7%[Figure 2]

Figure 2: Most common sites of skin adnexal tumors

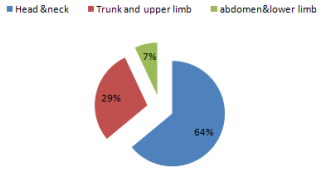

Out of 68 skin adnexal tumors, benign tumors are 65 comprising 95.5% and malignant tumors were 03 comprising 4.5%[Figure 3].

Figure 3: Incidence of benign and malignant tumors

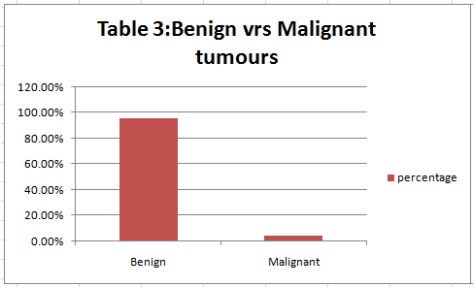

Largest group of tumors are sweat gland tumors (40.1%). Next common group of tumors were hair follicle tumors (36.2%) . Sebaceous, Undifferentiated and others comprises (23.7%)[Figure 4].

Figure 4: Percentage of tumors basing on differentiation

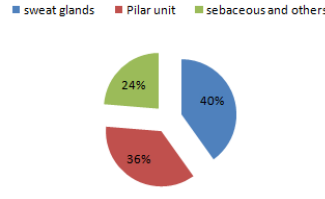

Among benign tumors, hidradenoma and pilomatricoma were most common tumors.Sebaceous carcinoma is the common malignant tumor among all carcinomas

Among sweat gland tumors most common are eccrine acrospiroma 58%, followed by chondroid syringoma 19% eccrine hydrocytoma 16% and others 7% [Figure 5].

Figure 5: Microscopic pictures of common sweat gland tumors

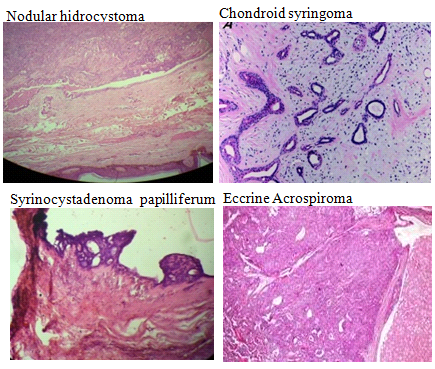

Among follicular tumours, pilomatricoma comprises 49%,trichoepithelioma 39%,proliferating pilar tumours 8% and others 4%[Figure 6].

Figure 6: Microscopic pictures of common hair follicular tumors

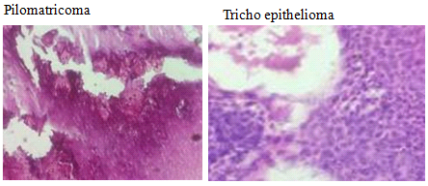

In tumors with sebaceous differentiation most common benign tumors are sebaceous adenoma and sebaceous carcinoma is the common malignant tumor[Figure 7].

Figure 7: Microscopic pictures of common Sebaceous gland tumors

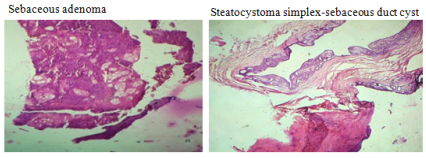

DISCUSSION

Adnexal tumors of skin are uncommon in routine practice and may cause diagnostic problems. Their diagnosis has important therapeutic implications[4,5,6].The present study was compared with other studies. Incidence among all biopsy samples was 0.25% and incidence of benign tumors and malignant tumors were 95.5% and 4.5% respectively[7,8,9].This was similar to findings of Radhika et.al and Yakoob et al. Sex ratio, male to female was 1.14:1 and this is found to be similar to Nair et al and saha et al.Commonest age group in present study was 51-60years[7,8,9].This was similar to findings of Jayalakshmi et al. Most common location of skin adnexal tumors were head and neck in the present study as mentioned by Radhika et al. Sweat gland tumors are the commonest tumors followed by pilar unit tumors and sebaceous tumors as mentioned by Yakob et al,Reddy et al. In present study most common benign tumor was hidradenoma followed by pilomatricoma and sebaceous carcinoma was most common malignant tumour[9,10,11].

CONCLUSION

Overall incidence of skin adnexal tumors was very low and incidence of benign tumor was more common than malignant. Clinical presentation of skin adnexal tumors were very non specific .Accurate histopathological diagnosis of benign and malignant is very important in therapeutic and prognostic point of view.Architectural patterns and infiltrative growth features helps to differentiate benign and malignant tumors.

REFERENCES

1. Klein Wiccan E,Seykora Jt.Tumours of the epidermal appendages.In:Elder DE,Elenitsas R,Johnson BL Jr Murphy GF(eds).Lever's Histopathology of the skin.Lippincott,Williams & Wilkins,Philadelphia.2005;867-914.
2. Rosai J.Skin Tumors and Tumor like conditions In: Ackerman's Surgical Pathology.Mosby,St.Louis,140-154.
3. Ramirez Claudia C,Berman Brian .Cutaneous Sign and Syndromes Associated with internal Malignancies.SkinMed.2005:4(2);84-90
4. Yoqoob N, Ahmad Z,Muzaffar S,Gill MS,Soomro IN,Hasan SH.Spectrum of Cutaneous Appendage Tumors at Aga Khan University Hospital .J Pak Med Assoc.2003 Sep;53(9):427-431.
5. Samalia MOA.Adnexal Skin Tumors in Zaria,Nigeria Ann Afr Med.2008 Mar:7(1):6-10.
6. LeBoit PE, Burg G, Weedon D, Sarasain A, editors. World Health Organization, Classification of Tumours. Pathology and Genetics of Skin Tumours. Lyon: IARC Press; 2006.
7. Kamiya H, Oyama Z, Kitajima Y. "Apocrine" poroma: review of the literature and case report. J Cutan Pathol. 2001;28(2):101–104.
8. Brownstein MH, Mehregan AH, Bikowski JB, et al. The dermatopathology of Cowden's syndrome. Br J Dermatol. 1979;100(6):667–673.
9. Hardisson D, Linares MD, Cuevas-Santos J, Contreras F. Pilomatrix carcinoma: a clinicopathologic study of six cases and review of the literature. Am J Dermatopathol. 2001;23(5):394–401.
10. Elder DE, Elenitsas R, Johnson BL, Murphy GF. Lever's Histopathology of the Skin. 9th ed. Baltimore (MD): Lippincott Williams & Wilkins;2005.
11. Obaidat NA, Alsaad KO, Ghazarian D. Skin adnexal neoplasms—part 2: an approach to tumors of cutaneous sweat glands. J Clin Pathol.2007;60(2):145–159.