Research Paper

Volume : 2 | Issue : 12 | December 2013 • ISSN No 2277 - 8179

Small for Gestational Age

Medical Science

KEYWORDS : IUGR, doppler blood flow, velocimetry, umbilical artery, middle cerebral artery

V. Leanza	Surgery Department, obstetric and gynaecologic Unit, Santo Bambino Hospital, Catania University
G. Leanza	Surgery Department, obstetric and gynaecologic Unit, Santo Bambino Hospital, Catania University
A. Carbonaro	Surgery Department, obstetric and gynaecologic Unit, Santo Bambino Hospital, Catania University
A. D'Agati	Surgery Department, obstetric and gynaecologic Unit, Santo Bambino Hospital, Catania University
O. VALENTI	Surgery Department, obstetric and gynaecologic Unit, Santo Bambino Hospital, Catania University
M.C. Teodoro	Surgery Department, obstetric and gynaecologic Unit, Santo Bambino Hospital, Catania University
M. Attard	American University of Malta
C. Pafumi	Dept. of Obst and Gynecol of University of Catania – Italy – Via Torre del Vescovo, 2 – 95122 – Catania – Italy

ABSTRACT

Lots of diagnostic procedures are assessed to evaluate intrauterine retardation (IUGR), among them ultrasounds are the most relevant ones. Foetal surveillance includes assessment of growth, detection of the Doppler blood flow and volume of amniotic fluid. There is an evidence of the association between IUGR and foetal blood perfusion. Pregnancies with early onset of IUGR remain a challenge not solved yet, even if the velocimetry of the foetal middle cerebral artery is considered mandatory for neurological risk when altered. In mid-late onset, IUGR cerebral and umbilical blood Doppler is useful to detect the potential damage of the foetus and avoid the hypoxic risk. Ductus venous flow is also an indicator of foetal jeopardy in case of abnormal umblical artery waves. Review of literature shows that middle cerebral, umbilical arteries, ductus venosus and uterine arteries are the most relevant vessels to be evaluated in order to establish the foetal well-being when IUGR arises. Obstetric management aims to lead what is the better choice: prematurity with associated Infant Respiratory Distress Syndrome (IRDS) or, on the contrary, waiting with correlated either stillbirth risks or catch-up growth advantage.

Introduction

Intrauterine growth retardation is considered a reduction of the foetal growth in comparison with a normal range (1-2-3). The so-called small for date foetuses includes three groups:

- healthy small foetuses,
- chromosomally abnormal foetuses,
- foetuses suffering from utero-placental insufficiency leading to restriction in foetal growth.

This differentiation is mandatory for a correct management when intrauterine growth retardation (IUGR) is detected with ultrasounds (4). We must consider that when a foetus is constitutionally small in accordance with parents' stature the risk of morbidity or perinatal death is not relevant and clinic monitoring is superimposable to physiological pregnancy. When the foetus is chromosomally abnormal, there is neither monitoring evaluation nor suitable treatment to lead a normal condition of the fetus: in this case growth retardation is due to intrinsic factors. When fetus is genetically normal but suffering from utero-placental insufficiency and IUGR, a correct diagnostic procedure and a reliable management are compulsory to avoid further fetal damage or stillbirth. Placental dysfunction, hindering the normal transfer of oxygen, nutrients and waste products, has an important influence to the physiopathology of IUGR. The alterations of utero-placental circulation imply metabolic, endocrinological, hematologic and cardiovascular modifications that occur when the growth restriction is clinically evident (5). The decrease of perfusion causes a reduction of glycogen store and a conversion from aerobic to anaerobic metabolism with accumulation of lactate and ketone bodies. Hypoxemic hypoxia has effects on endocrine axes with hypothyroidism, bone changes and hyperadrenocortisolism. Hypoxia has negative consequences for blood viscosity because red cells are less deformable and increase their number. The cardiovascular response to hypoxia is a redistribution of blood flow with a reduced flow in periphery and a cerebral vasodilatation, the so-called brain-sparing reflex. These compensatory changes can be evaluated by Doppler ultrasound which provides great information regarding screening, prediction, diagnosis and management of IUGR.

Material and method

This review summarizes the current knowledge about IUGR pregnancies and its relationship with the severity of the disease. **Search of PubMed, Cochrane library and relevant articles from** 1992 to 2012.

Results

Diagnosis of IUGR starts with abdominal palpation using Leopold maneuvers and the measurement of symphysis fundal height (6). They do not properly predict fetuses with growth restriction but they are an efficient tool to identify pregnancy at risk. Suspected IUGR is detected by ultrasounds monitoring fetal weight, asymmetric growth and amniotic fluid volume (7). During the first trimester gestational age is estimated by crown-rump length (CRL), after this period this parameter is not suitable and gynaecologists use abdominal circumference (AC), biparietal diameter (BPD), head circumference (HC), femur length (FL), transcerebellar diameter (TCD) (8). According to literature AC is the most accurate biometric variable to recognize growth restriction. A difference in measurements estimated at the interval of 2 weeks inferior of 11 mm is a landmark of fetal growth delay (5). These biometrical parameters, combined into formulas, improve accuracy of estimated fetal weight

(EFW). Sonographically EFW < 5th percentile is considered a sign of fetal growth restriction. Shepard and al. (9) apply BPD and AC value for identify IUGR, whereas when foetal size is very small, Hadlock's formula is preferable (10) (HC, AC and FL). The increase of HC/AC ratio means that it is an asymmetric growth (11) and its value below 10th percentile indicates a fetal growth delay. IUGR is associated with an inadequate amniotic volume estimated by ultrasounds. Oligohydramnios , defined when the single deepest pocket (SDP) is less than 2 cm or the amniotic fluid index (AFI) is less than 5 cm, is a marker of accelerating placental disease. The decreased amniotic fluid volume is not a reliable diagnostic test to identify growth-restricted fetuses, whereby the assessment of IUGR needs more detecting methods (12).

Doppler ultrasounds improve diagnostic detection owing to velocimetry which assesses uteroplacental circulation and evaluates umbilical artery, uterine artery, middle cerebral artery and ductus venosus. Doppler assessment of umbilical arteries identifies vascular impedance of fetal compartment of placenta (13). A saw-tooth appearance (Fig. 1) is the normal flow waveform from umbilical artery, the increasing resistance to blood perfusion results in a reduced end- diastolic flow (6) . If the placental dysfunction is more than 60-70 % end- diastolic velocities are absent or even reversed. These severe cases correlate with higher risk of perinatal deaths (3). Umbilical arteries waveform are classified into 3 blood flow classes (BFC) (14) :

- BFC 0: normal blood flow velocity with pulsatility index less than 2 SD (within the limits);
- BFC 1: positive diastolic flow velocity with PI between 2 and 3 SD;
- BFC 2: positive diastolic flow velocity with PI more than 3 SD;
- BFC 3A: absent end-diastolic flow velocity;
- BFC 3B: reverse end-diastolic flow velocity.

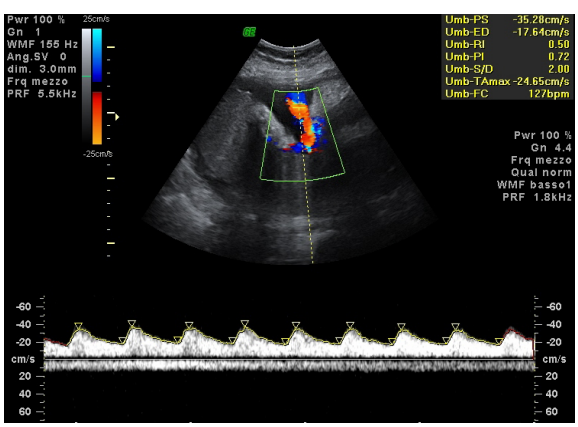

Fig. 1 UMBILICAL ARTERY SAW-TOOTH SHAPED BLOOD FLOW

The maternal side of uteroplacental circulation is evaluated by Doppler ultrasounds of uterine arteries. During the first half of pregnancy the trophoblastic invasion of decidua turns the vascular bed into a low resistance circulation. This change is defined by Doppler imaging as an increased diastolic flow and uterine arteries lose their notched Doppler waveform (13). If pregnancy is complicated by uteroplacental dysfunction, Doppler velocimetry shows an increased uterine artery Doppler index and / or persistent uterine artery notch in the late second and third trimesters (mostly after 32 weeks) (15). Uterine artery score (UAS) according to Hernandez-Andrade (16) defines abnormal uterine artery Doppler:

- UAS 0: normal blood velocity waveform (PI less than 2 SD and arteries haven't notch);
- UAS 1: one abnormal finding (PI more than 2 SD or presence of early diastolic notch in one artery);
- UAS 2 : two abnormal findings;
- UAS 3 : three abnormal findings;
- UAS 4 : four abnormal findings (PI more than 2 SD and early diastolic notch in both uterine arteries).

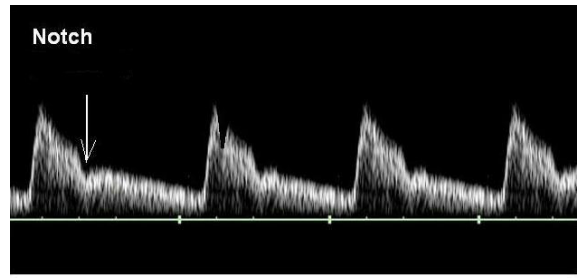

Fig 2. UTERINE ARTERY WITH A NOTCHED WAVEFORM

The continuous hypoxic insult due to utero-placental insufficiency determines a redistribution of blood flow improving the circulation in vital organs (brain, heart and adrenals) and reducing it in periphery. Brain sparing effect was considered a protective mechanism but recent studies prove its association with neurological damage, in fact the first stage is followed by failure (17). Thanks to new technologies foetal cerebral circulation is monitored easily by Doppler ultrasound. Middle cerebral artery is still considered the gold standard for the assessment of foetal brain blood flow. Physiologically cerebral circulation is a high resistance territory, when hypoxia occurs the organism replies with an active brain vasodilatation. This active autoregulation is recorded by Doppler as an increased end-diastolic flow in the middle cerebral artery reflecting the low pulsatility index (PI) (18). Middle cerebral artery peak systolic velocity (MCA-PSV) is a good predictor of perinatal mortality and seems to be more accurate than other parameters, such as PI (19). The brain-sparing reflex is better evaluated by cerebroplacental ratio (CPR) defined as MCA-PI / UA-PI because it reflects the degree of placental insufficiency. In a normal condition its value is above 1, when there is early cerebral vasodilatation the rate decreases until 1 or lower if the process is advanced (20).

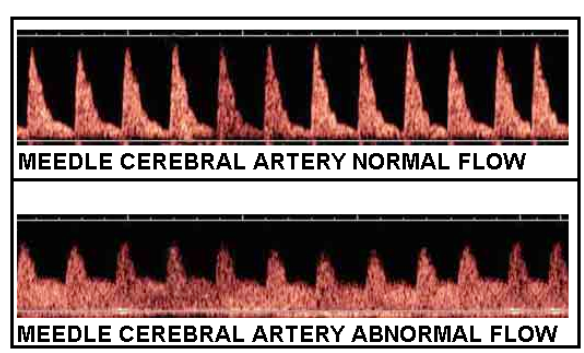

Fig. 3 MIDDLE CEREBRAL ARTERY FLOW

Other cerebral territories could be evaluated to add further information but the anatomic localization limits their use. Clinical studies explored anterior cerebral arteries (ACA) and it was demonstrated that their parameters were altered before those of middle cerebral arteries (21-23). Among venous vessels galen vein and transverse sinus focused an increased velocity and pulsatility index and these patterns are associated with a worse perinatal outcome (24). Ductus venosus is recorded by Doppler ultrasounds to give information about right ventricle and possible compensation. In regular conditions, ultrasound waveform has 2 peaks which represent the ventricular systole and diastole followed by a lower point due to atrial contraction. In IUGR foetuses the ventricular end-diastolic pressure increases, diastolic velocity decreases and the A-wave, corresponding to end-diastolic atrial contraction, decreases or disappears or, in extreme cases, becomes negative. These changes mean a worsening of placental dysfunction and they predict an unfavorable outcome (13).

Discussion

Pregnancies complicated by intrauterine growth restriction are linked with a high risk to develop hypoxic damages and to increase perinatal mortality. The purpose of obstetric management is to recognize IUGR foetuses, to monitor foetal health during pregnancy and to take decisions about timing of delivery (25).

The first challenge is distinguishing between a small for gestational age healthy foetus and those truly IUGR. Ultrasonographic biometry and Doppler evaluation of placental and foetal circulation are useful to identify IUGR foetuses. The most sensitive biometric parameter in detecting IUGR is AC. When fetometry estimates a small foetus, the first step is the assessment of placental circulation. Umbilical artery Doppler should be performed as primary examination because it distinguishes a growth restricted foetus caused by hypoxic damage from a genetically non hypoxic small foetus. Low AC (below 10th percentile) associated with an increased umbilical artery systolic/diastolic ratio (above 90th percentile) improves IUGR detection, besides these values are combined with amniotic fluid evaluation (6). Surveillance of growth restricted foetuses depends on clinical pattern and umbilical artery BFC. It is recommended to monitor umbilical artery Doppler velocimetry, amniotic fluid volume and foetal heart rate (recorded by cardiotocography) fortnightly, when umbilical artery Doppler is normal. For BFC 1 these parameters should be evaluated twice-weekly; for BFC 2 three times weekly; for BFC 3 admission, CTG twice daily and Doppler assessment daily (14). Abnormal umbilical artery Doppler according to several monitoring examinations guides timing of delivery. It is recommended at 34 weeks if Doppler ultrasounds record absent end-diastolic flow (26), at 32 weeks when reversed end-diastolic flow is detected (27). Middle cerebral artery evaluation offers evidence about foetal response to hypoxic damage, so pregnancy outcome is improved because it is useful to choose timing of delivery wisely. In an early IUGR several foetuses show signs of brain sparing and have a high risk to develop postnatal neurological damage. Delivery is recommended when intracranial oedema arises. After 32 weeks of pregnancy fetal cerebral circulation monitoring offers the better time to deliver avoiding long term neurological injury (17).

ACKNOWLEDGMENTS

Valentina Pafumi has carried out English language editing for this article.

Special Thanks to Salvatore Sciarretta(English Professor-Catania University) and Pafumi Valentina for their precious help in translating this work.

REFERENCE

1. Ropacka-Lesiak M, Breborowicz G. Management of pregnancy complicated by intrauterine fetal growth restriction Ginekol Pol. 2012 May;83(5):373-6 | 2. Sciarretta S., Leanza V. Fundamental Obstetric And Gynecologic Elements (Test Book) Edizione S.p.e. Catania.ISBN 978-88-96808-05-4 2011 | 3. Leanza V. Ostetricia- Edizioni Minerva Medica Editor S.P.A. 2009. (Test Book) (ISBN 10: 88-7711-631-5) (ISBN 13: 978-88-7711-631-4). | 4. AL Qahtani N. Doppler ultrasound in the assessment of suspected intra-uterine growth restriction. Ann Afr Med 2011-2012 ;10:266-71. | 5. Miller J., Turan S., Baschat A. Fetal Growth restriction Seminary in perinatology 2008 32: 274-280 | 6. K. Haram, E. Søfteland, R. Bukowski Intrauterine growth restriction International Journal of Gynecology and Obstetrics (2006) 93, 5-12 | 7. Baschat AA. Pathophysiology of fetal growth restriction: implications for diagnosis and surveillance. Obstet Gynecol Surv 2004;59:617– 627. | 8. Geirsson RT. Ultrasound: the rational way to determine gestational age. Fetal Matern Med Rev 1997;9:133– 146. | 9. Shepard MJ, Richards VA, Berkowitz RL et al. An evaluation of two equations for predicting fetal weight by ultrasound. Am J Obstet Gynecol 1982; 142: 47–54. | 10. Hadlock FP, Harrist RB, Carpenter RJ et al. Sonographic estimation of fetal weight. The value of femur length in addition to head and abdomen measurements. Radiology 1984; 150: 535–540. | 11. Dashe JS, McIntire DD, Lucas MJ, Leveno KJ. Effects of symmetric and asymmetric fetal growth on pregnancy outcomes. Obstet Gynecol 2000;96:321–327. | 12. Chauhan SP, Sanderson M, Hendrix NW et al. Perinatal outcome and amniotic fluid index in the antepartum and intrapartum periods: A meta-analysis. Am J Obstet Gynecol 1999; 181: 1473–1478. | 13. Society for Maternal-Fetal Medicine Publications Committee, with the assistance of Eliza Berkley, MD; Suneet P. Chauhan, MD; and Alfred Abuhamad, MD Doppler assessment of the fetus with intrauterine growth restriction American Journal of Obstetrics & Gynecology April 2012:300-308. | 14. GS Ghosh, S Gudmundsson Uterine and umbilical artery Doppler are comparable in predicting perinatal outcome of growth-restricted fetuses BJOG An International Journal of Obstetrics and Gynaecology 2009 424-430. | 15. Juliana Gebb, Fellow, Pe'er Dar Colour Doppler ultrasound of spiral artery blood flow in the prediction of pre-eclampsia and intrauterine growth restriction Best Practice & Research Clinical Obstetrics and Gynaecology 25 (2011) 355–366. | 16. Hernandez-Andrade E, Brodszki J, Lingman G et al. Uterine artery score and perinatal outcome. Ultrasound Obstet Gynecol 2002; 19: 438–442. | 17. Edgar Hernandez-Andrade, Jesus Andres Benavides Serralde and Rogelio Cruz-Martinez Can anomalies of fetal brain circulation be useful in the management of growth restricted fetuses? Prenatal Diagnosis 2012, 32, 103–112. | 18. Mari G, Deter RL. Middle cerebral artery flow velocity waveforms in normal and small for-gestational age fetuses. Am J Obstet Gynecol 1992;166:1262-70. Level II-3. | 19. Mari G, Hanif F, Kruger M, Cosmi E, Santolaya-Forgas J, Treadwell MC. Treadwell. Middle cerebral artery peak systolic velocity: A new Doppler parameter in the assessment of growth-restricted fetuses. Ultrasound Obstet Gynecol 2007;29:3;310-6. | 20. Baschat AA, Gembruch U. The cerebroplacental Doppler ratio revisited. Ultrasound Obstet Gynecol 2003;21:124–127. | 21. Benavides-Serralde A, ScheierM, Cruz-Martinez R, et al. Changes in Central and Peripheral Circulation in Intrauterine Growth-Restricted Fetuses at Different Stages of Umbilical Artery Flow Deterioration: New Fetal Cardiac and Brain Parameters. Gynecol Obstet Invest 2011;71:274–280. | 22. Cruz-Martinez R, Figueras F, Hernandez-Andrade E, et al. Longitudinal brain perfusion changes in near-term small-forgestational-age fetuses as measured by spectral Doppler indices or by fractional moving blood volume. Am J Obstet Gynecol 2010;203(42):e1–e6. | 23. DubielM, Gunnarsson GO, Gudmundsson S. Blood redistribution in the fetal brain during chronic hypoxia. Ultrasound Obstet Gynecol 2002;20:117–121. | 24. Cheema R, Dubiel M, Breborowicz G, et al. Fetal cerebral venous Doppler velocimetry in normal and high-risk pregnancy. Ultrasound Obstet Gynecol 2004;24:147–153. | 25. Karel Marsˇa´ l Obstetric management of intrauterine growth restriction Best Practice & Research Clinical Obstetrics and Gynaecology 23 (2009) 857–870. | 26. American College of Obstetricians and Gynecologists. Intrauterine growth restriction; ACOG practice bulletin no. 12. Washington, DC: ACOG; 2000. Level III. | 27. Hartung J, Kalache KD, Heyna C, et al. Outcome of 60 neonates who had ARED flow prenatally compared with matched control group of appropriate-for-gestational age preterm neonates. Ultrasound Obstet Gynecol 2005;25: 566-72. Level II. |