ORIGINAL RESEARCH PAPER

Volume-7 | Issue-3 | March-2018 | PRINT ISSN No 2277 - 8179

INTERNATIONAL JOURNAL OF SCIENTIFIC RESEARCH

SONOGRAPHIC ,DOPPLER AND ELASTOGRAPHIC EVALUATION OF GANGLION CYSTS

Radiodiagnosis

Dr Bharat Lohchab* Resident, Dept. of Radio-diagnosis, Jawaharlal Nehru Medical College, Sawangi (Meghe), Wardha, Maharashtra, India - 442001 *Corresponding author

Dr. Suresh Phatak Professor and Head of department, Dept. of Radio-diagnosis, Jawaharlal Nehru Medical College, Sawangi (Meghe), Wardha, Maharashtra, India - 442001

ABSTRACT

Objective- To evaluate ultrasonographic , doppler and elastographic appearances of ganglion cysts.

Material and methods- A cross sectional prospective study was carried out in the department of radio-diagnosis, AVBRH sawangi (meghe), Wardha for a period of 2 years . Twenty patients with clinical diagnosis of ganglion cysts referred to the department were selected. Hitachi aloka arietta 70S ultrasound machine with high frequency linear probe (12-18 MHz) and strain elastography was used for evaluation of patients.

Result- Out of the 20 ganglion cysts , 14 were on volar surface of wrist , 4 were on dorsal surface while 2 were on medial aspect of ankle. 15 ganglia were unilocular; 5 were multilocular with internal septa . All ganglion cysts showed BGR appearance on elastography.

Conclusions- USG elastography is useful in detection of ganglion cysts.

KEYWORDS

Cyst, Ganglion, Sonography, Doppler , Elastography

INTRODUCTION-

Ganglion cysts are benign cystic masses that occur in relation to musculoskeletal structures [1]. They are thin-walled cysts with mucinous material within. They develop in relation to joints or tendon sheaths, the hand and wrist being the most frequent sites of development[2,3]. They are found more often in young women especially in and around the hand [4]. They can cause a variety of clinical symptoms depending on their location due to mass effect on adjacent structures. A proportion of patients may have a history of trivial trauma. There is a 2:1 female predominance. Both hands are equally affected. Most of the time, these cysts occur spontaneously and grow progressively; however, approximately 15% of patients describe a relationship between the appearance of the cyst and an injury [1,5,6,]. There are many classifications of ganglion cysts such as using the relation of structure. The cysts located within the bone are called as intraosseous ganglion cysts, those found adjacent to bone called as periosteal ganglion cysts, and those found in soft tissue are called as soft tissue Ganglion cysts. The cysts those within the joint are known as intra-articular ganglion cysts and those adjacent to a joint are juxta-articular ganglion cysts [7]. It is also well established that ultrasound is an excellent imaging modality to confirm the presence of a mass and to differentiate cystic from solid lesions[8,9]. A ganglion cyst is usually described as a well demarcated, avascular, anechoic mass with posterior acoustic enhancement which arises from a tendon sheath or joint capsule on ultrasound. It may be lobulated and may even contain internal septations or dependent debris[10]. However , a small cyst may show hypoechoic appearance without a typical posterior acoustic enhancement[11].

MATERIAL AND METHODS

Collection of data – This prospective study includes total of 20 patients referred for ultrasound were analysed in 2 years period with clinical diagnosis of ganglion cyst. Real time ultrasound followed by strain elastography was performed using Hitachi aloka Arietta 70S ultrasound machine with 12-18 MHz linear transducer.

Conventional sonographic examination

Each lesion was assessed with ultrasound descriptors i.e. Shape, orientation, margin, lesion boundary, echo texture, posterior acoustic features and vascularity.

Sonographic elastography

Once the optimum B mode image was obtained, elastograms were acquired taking due care that the lesion remained in the imaging plane. The images from conventional sonography and sonographic elastography were displayed side by side as a single image. Using TSUKUBA scoring system, lesions were given score on elastography scale.

Results

Bar diagram 1: showing age group of patients

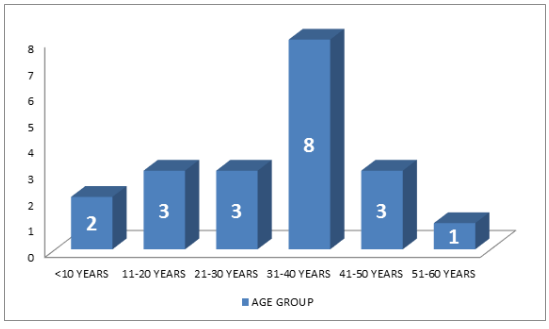

Pie chart 1: sex distribution of patients

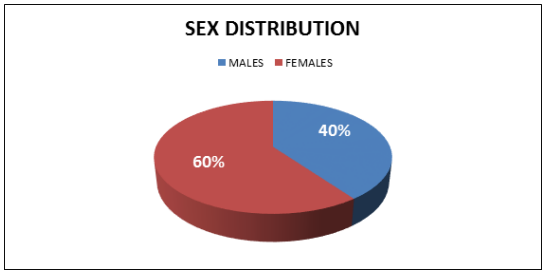

Table 1- location of ganglion cysts

	NO.OF PATIENTS	% OF PATIENTS
Volar surface of wrist	14	70 %
Dorsal surface of wrist	4	20%
Medial side of ankle joint	2	10%

Table 2-ultrasound, doppler and elastographic features of ganglion cysts

Unilocular cysts	15	75%
Multilocular cysts with internal septa	5	25%
Clear fluid as content	16	80%
Internal echoes (debris) as content	4	20%
Vascularity on doppler	0	0%
BGR appearance on elastography	20	100%

Bar diagram 2: margin characterstics of ganglion cysts

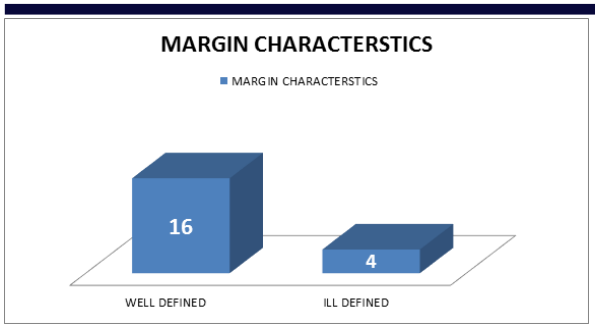

Out of the 20 ganglion cysts , 14 were on volar surface of wrist , 4 were on dorsal surface while 2 were on medial aspect of ankle. 15 ganglia were unilocular; 5 were multilocular with internal septa . Out of 20 cysts 16 had clear fluid as its content whereas 4 ganglia had internal echoes (debris) . 15 ganglia showed posterior acoustic enhancement; 16 had well-defined margins; whereas 4 had ill defined margins. None of ganglion cyst showed vascularity on Doppler .

Discussion-

Tsukuba scoring system

A score of 1 indicated even strain for the entire hypoechoic lesion (i.e., the entire lesion was evenly shaded in green). A score of 2 means strain in most of the hypoechoic lesion, with some areas of no strain (i.e., the hypoechoic lesion had a mosaic pattern of green and blue), a score of 3 implies that strain at the periphery of the hypoechoic lesion, with sparing of the center of the lesion (i.e., the peripheral part of lesion was green, and the central part was blue). A score of 4 shows no strain in the entire hypoechoic lesion (i.e., the entire lesion was blue, but its surrounding area was not included. A score of 5 indicated no strain in the entire hypoechoic lesion or in the surrounding area (i.e., both the entire hypoechoic lesion and its surrounding areawere blue). BGR represents typical artifactual three layered aspect (blue-green-red) encountered with cystic lesions. In strain patterns, score 1, 2 and 3 emp¬hasized benign features whereas masses with scores of 4 and 5 were considered as malignant. BGR appearance is seen in cystic lesions. [12].

In our study , there was female predominance where 60% cases were females and rest were males . This was in accordance with the study done by George Wang et al (2007) where they had similar findings. [11].

With regard to age distribution, our study showed most number of patients (40%) were in age group of 31-40 years . This was similar with the study done by George Wang et al (2007) where the average age of the patients was 36 years [11].

Out of the 20 ganglia, 14 (70%) were present on volar aspect , 4 (20%) were on dorsal aspect. This is similar to the study done by George Wang et al (2007) where out of 20 ganglia examined sonographically, 75% ganglia were volar and rest 25% were dorsal [11].

In our study margin was well defined in 16 (80%) ganglia whereas only 4 (20%) had ill defined margins. This was also in accordance with the study done by George Wang et al (2007) where they had similar findings [11].

In our study , out of 20 ganglia 80% had clear fluid as content whereas only 20% showed internal echoes(debris). However different findings were noted in study done by Robert Ortega et al (2001) where only 10% ganglia had echogenic dependent component[10].

Out of 20 ganglia our study showed only 5 ganglia (25%) were multilocular with internal septations whereas study done by Robert Ortega et al (2001) showed 50% ganglia had septations[10].

Limitation-

One of the main limitations of this study is that the acquisition of elastograms as well as analysis is observer dependent. The magnitude of initial compression could affect the elasticity map. Another limitation was small sample size of study.

Conclusion

It can hence be concluded that ultrasound strain elastography is quite accurate in identifying Ganglion cysts.

Figure 1

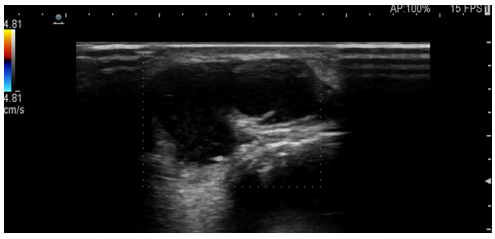

Figure 1- Ganglion cyst on volar aspect of wrist in 28 year old male patient showing particulate debris in cyst and no vascularity on doppler

Figure 2-.

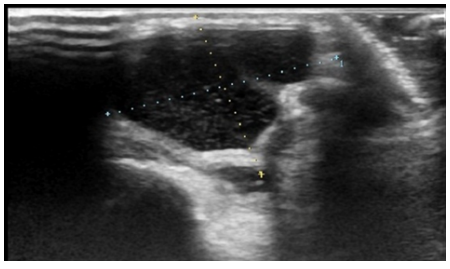

Figure 2- Ganglion cyst in a 36 year-old female . Sonography shows a 6X5 mm hypoechoic ganglion cyst on volar aspect of wrist with incomplete septa, internal echoes (debris)as content and showing post acoustic enhancement

Figure 3

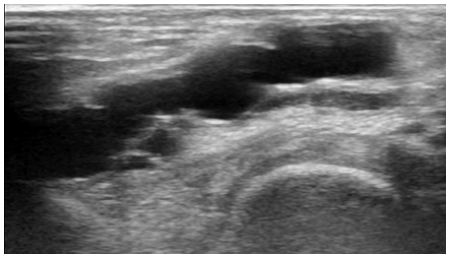

Figure 3- Ganglion cyst in a 32 year old female patient showing ill defined margins on USG

Figure 4-

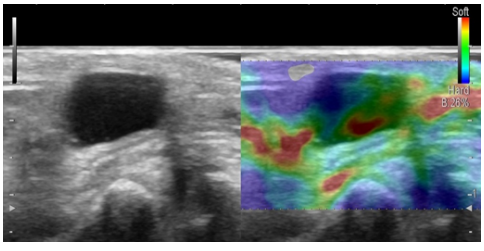

Figure 4- Strain Elastography of a ganglion cyst on medial asspect in ankle region showing typical BGR pattern indicating cystic nature of lesion.

Figure 5

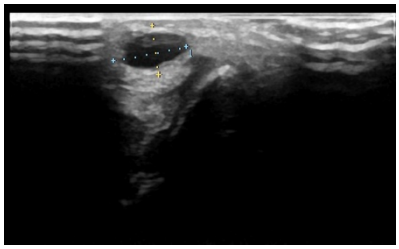

Figure 5- Sonography of unilocular ganglion cyst on dorsal aspect of wrist in a 14 year old male patient showing well defined margins without any internal septations and echoes within.

REFERENCES

[1] Kim SK, Park JM, Choi JE et-al. Intratendinous ganglion cyst of the semimembranosus tendon. Br J Radiol. 2010;83 (988): e79-82.
[2] Nelson CL, Sawmiller S, Phalen GS. Ganglion of the wrist and hand. J Bone joint Surg 1972; 54(A): 1459-64
[3] De Flaviis L, Nessi R, Delbo P, Calori G, Balconi G. High resolution sonography of wrist ganglia. J Clin Ultrasound 1987; 15: 17-22.
[4] Thornburg LE. Ganglions of the hand and wrist. J Am Acad Orthop Surg. 1999;7 (4): 231-8
[5] Angelides AC, Wallace PF. The dorsal ganglion of the wrist: its pathogenesis, gross and micromicroscopic anatomy, and surgical treatment. J Hand Surg Am 1976; 1:228–235
[6] Barnes WE, Larsen RD, Posch JL. Review of ganglia of the hand and wrist with analysis of surgical treatment. Plast Reconstr Surg 1964; 34:570–578
[7] Beaman FD, Peterson JJ 2007. MR imaging of cysts,ganglia,and bursae about the knee. RCNA ; 45:969-982
[8] Beggs I. Ultrasound of soft tissue masses. Imaging 2002;14:202–8.
[9] Teefey SA, Middleton WD, Patel V, et al. The accuracy of high-resolution ultrasound for evaluating focal lesions of the hand and wrist. J Hand Surg [Am] 2004; 29A:393–9.
[10] Ortega R, Fessell DP, Jacobson JA, et al. Sonography of ankle ganglia with pathologic correlation in 10 pediatric and adult patients. AJNR Am J Roentgenol 2002;178:1445–9
[11] Wang G, Jacobson JA, Feng FY, et al. Sonography of wrist ganglion cysts: variable and noncystic appearances. J Ultrasound Med 2007;26:1323–8.
[12] Itoh A, Ueno E, Tohno E, Kamma H, Takahashi H, Shiina T, et al. Breast disease: Clinical application of US elastography for diagnosis. Radiology. 2006; 239:341-50