ORIGINAL RESEARCH PAPER

Volume-7 | Issue-3 | March-2018 | PRINT ISSN No 2277 - 8179

INTERNATIONAL JOURNAL OF SCIENTIFIC RESEARCH

SONOGRAPHIC EVALUATION OF YOLK SAC SIZE AND ITS OUTCOME IN FIRST-TRIMESTER PREGNANCY

Radiology

Dr. Muralidhar G. Kamalapur* Consultant Radiologist, Srinivas Hospital, Mukka, Surathkal, Mangalore. Karnataka. *Corresponding Author

Dr. Preetam Patil Associate Professor, Department of Radiology, S.D.M College of Medical Sciences & Hospital, Dharwad.

Dr. Santosh Dasar Associate Professor, Department of Radiology, S.D.M College of Medical Sciences & Hospital, Dharwad.

ABSTRACT

Aims: Present study is aimed to see whether yolk sac diameter above or below the normal range is associated with an adverse outcome of pregnancy.

Material and Methods: 200 viable singleton pregnancies between 6-11weeks were evaluated retrospectively for the yolk sac diameter on ultrasound with pregnancy outcome.

Results: Miscarriage was seen in 27(17.31%) of patients with YSD less than 3mm, 2(5.0%) with yolk sac diameter between 3-5.6mm and 3(75%) of patients with yolk sac diameter above 5.6mm. Amongst patients presenting with bleeding, miscarriage rate was highest with YSD more than 5.6mm (100%) and least with YSD between 3 to 5.6mm (50%).Amongst patients with bleeding, continuation to normal pregnancy was highest with YSD between 3 to 5.6mm (50%) and least in patients with YSD more than 5.6mm (00%).Conclusion: Cases with yolk sac diameter less than 2mm or more than 6mm are at increased risk for miscarriage.

KEYWORDS

Ultrasound, Miscarriage, yolk sac diameter , first trimester

Introduction

The secondary yolk sac is the first sonographically visible extra embryonic structure[1]. It is formed in the fourth menstrual week and is seen in normal pregnancies, the primary yolk sac is not visible on ultrasound[2]. Yolk sac provides metabolic, immunologic, endocrine, nutritional and hemopoietic functions during organogenesis. It reaches its highest level of functional activity between 4-7 week of development[3].

In this present study, we evaluate the yolk sac diameter with the outcome of the gestation in early pregnancy period between 6 to 10 weeks and see if too small or too large yolk sacs are associated with an adverse perinatal outcome.

Materials and methods

A study was performed on 200 patients; singleton pregnancies with gestational age between 6 to 10 weeks and maternal age between 19 to 35 years were included in the study. Patients with a gestational age more than 35years, history of recurrent abortions, uterine anomalies, history of previous ectopic pregnancy, pregnancy through IVF techniques, fetal bradycardia, enlarged amniotic sac, irregular and echogenic yolk sac, maternal diabetes, hypertension, and hyperthyroidism were excluded from the study.

Scanning technique:

Informed consent was taken from the patient. The scan was performed by transabdominal route on a GE Voluson E6, GE Healthcare, ultrasound machine and Phillips HD11XE, Phillips Medical Systems, using curvilinear transducer (2-5mhz).Uterus, adnexa, and ovaries were scanned first, gestational sac and yolk sac was identified and yolk sac diameter (YSD) was measured by placing the callipers at the inner margins of the yolk sac. YSD was grouped into three groups less than 3mm, 3 to 5.6mm and more than 5.6mm. Patients were followed up to 12 weeks and were considered normal pregnancy if they went beyond 12 weeks and if they didn't be considered an abortion.

Results:

A total of 200 patients were included in this study with age group between 18 to 35 years and gestational age between 06 to 10 weeks. Patients with gestational age between 6-8weeks constituted 78.5%. Patient distribution on YSD, less than 3mm (156 patients), 3-5.5mm (40 patients) and more than 5.6mm (04 patients).

Mean YSD amongst various gestational age groups were 6weeks (1.99mm), 7weeks (2.30mm), 8weeks (2.41mm), 9weeks (2.6mm) and 10weeks (3.10mm). Graph 1

Bleeding was noted in 46(29.49%) of patients with YSD less than 3mm, 4(10%) with YSD between 3mm-5.6mm and 3(75%) with YSD above 5.6mm.(Graph 2) Miscarriage was seen in 27(17.31%) of patients with YSD less than 3mm, 2(5.0%) between 3mm-5.6mm and 3(75%) in patients with YSD above 5.6mm. Graph 3

The rate of bleeding was least 4(10%) in YSD between 3mm-5.6mm and in gestational age of 10weeks 2(12.50%).The rate of miscarriage was least 2(5.0%) in patients with YSD between 3mm-5.6mm and in gestational age of 10weeks 1(6.25%).

Amongst patients presenting with bleeding, miscarriage rate was highest with YSD more than 5.6mm (100%) and least with YSD between 3 to 5.6mm (50%). Amongst patients with bleeding leading to continuation of normal pregnancy was highest with YSD between 3 to 5.6mm(50%) and least in patients with YSD more than 5.6mm (00%).(Table 1)

Bleeding and rate of miscarriage was highest in the gestational age group of 7weeks with mean YSD of 2.3mm and least at 10weeks with mean YSD of 3.2mm. (Table 2)

Graph 1: Mean yolk sac diameter across various gestational age groups

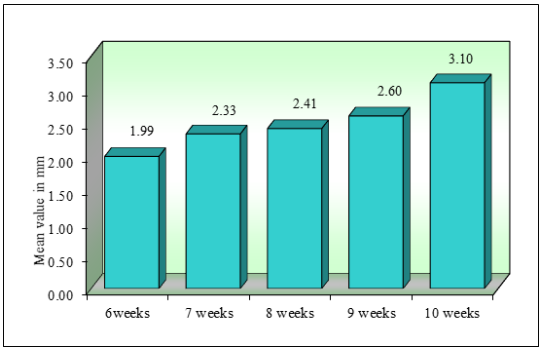

Graph 2: Comparison of Yolk sac diameter with patients presenting with bleeding

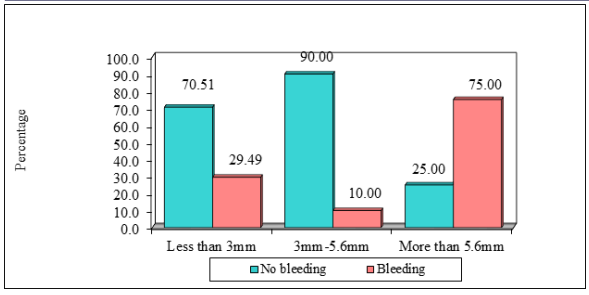

Graph 3: Comparison of yolk sac diameter with patients having miscarriage

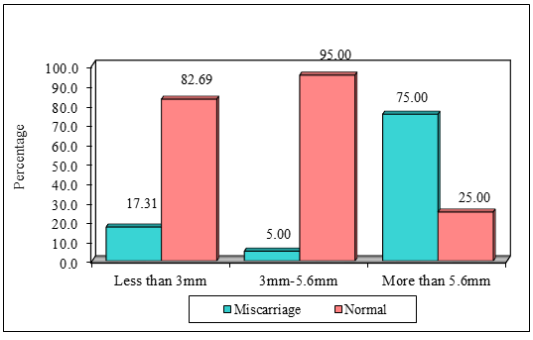

Table 1
Correlation of yolk sac diameter with pregnancy outcome in patients presenting with bleeding.

Yolk sac diameter	Total Patients with bleeding	Patients who had Miscarriage	Pregnancy continued as normal.
Less than 3mm	46	27 (58.6%)	19 (41.3%)
3 to 5.6mm	04	02 (50.0%)	02 (50.0%)
More than 5.6mm	03	03 (100.0%)	00 (00.0%)
Total	53	32 (60.03%)	21 (39.6%)

Table 2
Correlation of gestational age and mean yolk sac diameter amongst patients presenting with bleeding and having miscarriage.

Gestational age	Number of patients	Mean diameter of yolk sac in mm	Patients with bleeding	Patients having miscarriage
6weeks	49	1.99	11 (22.45%)	05(10.20%)
7weeks	51	2.30	18 (35.29%)	12(23.53%)
8weeks	57	2.43	15 (26.32%)	10(17.54%)
9weeks	27	2.90	07 (25.93%)	04(14.81%)
10weeks	16	3.20	02 (12.50%)	01(6.25%)
Total	200		53(26.50%)	32(16.00%)

Discussion

Yolk sac appears about around 5 weeks and is seen on ultrasound when mean sac diameter is more than 8 to 13mm; it has an echogenic rim with a sonolucent centre[4].Gestational sac with yolk sac carry good prognosis compared to sacs with no yolk sac, it also serves as an important landmark to identify fetal cardiac activity[5].

Yolk sac measures 3-5mm in its internal diameter, it increases in size from the 5th week the 10th week and reduces in its size[1]. Reduced vascularity at its peak volume is the reason for its degeneration, reduced arterial signals and a simultaneous increase in umblico-placental blood flow suggests a transition from the yolk sac to placenta[3].

Various studies are performed to evaluate yolk sac size and compare with outcome in early pregnancies. In a study by T Küçük et al found that adverse pregnancy outcome was noted in patients with abnormal yolk sac size[6]. Papaionnou et al in their study found yolk sac diameter (YSD) to be above 95th centile in 1/5th of miscarriages[7].Failure to visualize yolk sac is to be considered a risk factor in pregnancy[8]. In pregnancies having missed abortions which had embryonic cardiac activity was found to be large, small and irregular shaped yolk sacs[9].

In our study bleeding was noted in 46(29.49%) of patients with YSD less than 3mm, 4(10%) with YSD between 3mm-5.6mm and 3(75%) with YSD above 5.6mm. The rate of bleeding was least 4(10%) in YSD between 3mm-5.6mm and in gestational age of 10weeks 2(12.50%). The rate of miscarriage was least 2(5.0%) in patients with YSD between 3mm-5.6mm and in gestational age of 10weeks 1(6.25%).

In a study by B. Soyoung et al found 94% favourable pregnancy result if the triple ultrasound markers, gestational sac size >/= 12mm, yolk sac size 2-6mm and presence of fetal cardiac activity, 08 of 10 patients who had yolk sac size > 6mm had miscarriage[10]. Y. Yan et al in their study found the on-going pregnancy rate to be 93% in the 3-5.5mm yolk sac diameter group and 47.4 % in YSD < 3mm[11].

In our study miscarriage was seen in 27(17.31%) of patients with YSD less than 3mm, 2(5.0%) and 3(75%) of patients with YSD above 5.6mm. Amongst patients presenting with bleeding abortion rate was highest with YSD more than 5.6mm (100%) and least with YSD between 3 to 5.6mm (50%). Amongst patients with bleeding, the continuation of normal pregnancy was highest with YSD between 3 to 5.6mm(50%) and least in patients with YSD more than 5.6mm (00%).

Some studies have suggested no correlation between yolk sac diameter and miscarriage, but some studies have shown that a small yolk sac or an absence of yolk sac was a predictor of miscarriage[12].Measurement methods used by various studies were different, some studies measured in three orthogonal planes, some, the outer borders and some the inner margins[11].One of the reasons for conflicting results in correlating YSD with miscarriage is the different measurement methods chosen by different authors[12].

Conclusion

The secondary yolk sac is an important structure in early pregnancy; it serves as an important source of nutritional, endocrinological and metabolic requirements during organogenesis. Alteration in size has its effect on pregnancy outcome, if not all but in some cases. Cases with yolk sac diameter less than 2mm or more than 6mm should be followed up regularly for sac size regression or enlargement.

REFERENCES

1. Tan S, Pektaş M.K, Arslan H, Sonographic Evaluation of the Yolk Sac.J Ultrasound Med 2012; 31:87–95.
2. Mara E, Foster G.Spontaneous regression of a yolk sac associated with embryonic death. J Ultrasound Med. 2000; 19(9):655-6.
3. Tan S, Tangal N G, Pektas M K, Özcan A Ş, Keskin H. L, Akgündüz G, Teber M A, Arslan Halil. Abnormal sonographic appearances of the yolk sac: which can be associated with adverse? perinatal outcome? Med Ultrason 2014;16:15-20.
4. Berdahl D.M,Blaine J,Voorhis B.V, M.D, Dokras A, Detection of enlarged yolk sac on early ultrasound is associated with adverse pregnancy outcomes.Fertility and Sterility. 2010; 94:1535-1537.
5. Nyberg D.A, Laurence A,Mack L.A,Harvey D,Wang K.Value of the Yolk Sac in Evaluating Early Pregnancies.J Ultrasound Med.1988;7:129-135.
6. T Küçük, NK Duru, MC Yenen, M Dede, A Ergün, I.Başer. J Yolk sac size and shape as predictors of poor pregnancy outcome. Perinat Med. 1999; 27(4):316-20.
7. Papaioannou G.I, Syngelaki. A, Maiz N, Jackie A. Ross , Nicolaides K.H. Ultrasonographic prediction of early miscarriage Human Reproduction,2011; 26: 1685–1692.
8. Falco P, Zagonari S, Gabrielli S, Bevini M, Pilu G, Bovicelli L. Sonography of pregnancies with first-trimester bleeding and a small intrauterine gestational sac without a demonstrable embryo.Ultrasound Obstet Gynecol. 2003;;21(1):62-5.
9. Tan S,Ipek A,Pektas M.K, Arifoglu M,Akif Teber M, Karaoglanoglu.M.Irregular Yolk Sac Shape Is It Really Associated With an Increased Risk of Spontaneous Abortion? J Ultrasound Med.2011; 30:31–36.
10. Soyoung Bae, M.D.,a and Joseph Karnitis, M.D. Triple ultrasound markers including fetal cardiac activity are related to miscarriage risk. Fertility and Sterility.2011; 96:1145-1148.
11. Yi Y, Lu G, Ouyang Y, lin G,Gong F ,Li X.A logistic model to predict early pregnancy loss following in vitro fertilization based on 2601 infertility patients. Reproductive Biology and Endocrinology201614:15:1-7.
12. Wie J.H,Choe S,BS,Kim S.J,Shin J.C, Kwon J.Y,Park I.Y.Sonographic parameters for prediction of Miscarriage.J Ultrasound Med.2015;34:1777-1784.