ORIGINAL RESEARCH PAPER

VOLUME-6 | ISSUE-6 | JUNE-2017 | ISSN No 2277 - 8179 | IF : 4.176 | IC Value : 78.46

INTERNATIONAL JOURNAL OF SCIENTIFIC RESEARCH

SPECTRUM OF NEOPLASTIC AND NON NEOPLASTIC LESIONS OF SALIVARY GLAND IN A TERTIARY CARE CENTRE IN WESTERN PART OF INDIA- A OBSERVATIONAL STUDY.

Pathology

DR. ARNAV KR. ROYCHOUDHURY ASSISTANT PROFESSOR, DEPT. OF PATHOLOGY, ADESH INSTITUTE OF MEDICAL SCIENCES & RESEARCH, BATHINDA

DR. REETA DHAR PROFESSOR, DEPT. OF PATHOLOGY,MGM MEDICAL COLLEGE & HOSPITAL, NAVI MUMBAI

DR. NIDHI BANSAL ASSISTANT PROFESSOR, DEPT. OF IMMUNOHEMATOLOGY & BLOOD TRANSFUSION,GGS MEDICAL COLLEGE, FARIDKOT

ABSTRACT

Introduction: Salivary glands are the site of origin of non neoplastic and neoplastic lesions. The histopathology of these are more various and diverse.Salivary gland tumours affect the parotid gland in more than 70% of cases, submandibular gland 5-10%, sublingual gland 1% and minor glands 5-15%. ***Aim of the study:*** To clinicopathologically study the various neoplastic and non neoplastic lesions of salivary glands. Materials and methods: The study was conducted in the department of pathology at Mahatma Gandhi Mission Hospital, Navi Mumbai during the period from October 2008 to October 2014, a total of 11,197 specimens were received for histopathological examinations, of which 50 specimens were of salivary gland lesions. ***Results:*** Chronic sialadenitis was the commonest (53.8%) non neoplastic lesion, Pleomorphic adenoma (64.8%) was the commonest benign tumor, Mucoepidermoid carcinoma (13.5%) was the most common malignant tumor of the salivary glands. Parotid was the commonest site accounting for 67.5% of all tumors followed by minor salivary glands (29.7%) and submandibular gland (2.7%). A female preponderance was seen in almost all tumors except Warthin's tumor with peak age incidence of 2nd to 6th decade. Conclusion: From the present study, it is evident that histopathological examination of salivary gland lesions is the most important modality in establishing the final diagnosis in predicting prognosis and typing of non neoplastic and neoplastic lesions of salivary glands.

KEYWORDS:

Sialadenitis, Pleomorphic, Mucoepidermoid, Warthin

INTRODUCTION

Salivary glands are the site of origin of non neoplastic and neoplastic lesions. The histopathology of these are more various and diverse.[1] The salivary glands seem at first sight to be relatively simple organs , yet the neoplasms that arise from them display a rich variety of microscopic appearance often within a single lesion.[2] Salivary gland is subjected to different types of pathological processes constituting a variety of lesions ranging from inflammatory lesions to neoplasms.[3] The neoplasms constitute about 3% of tumours and despite their low incidence are very heterogenous. Their remarkable morphologic variability combined with rarity renders these tumours difficult to diagnose.[4]

Salivary gland tumours affect the parotid gland in more than 70% of cases, submandibular gland 5-10%, sublingual gland 1% and minor glands 5-15%.[6] They can show a striking range of morphological diversity between different tumour types and sometimes within an individual tumour mass. In addition, hybrid tumours, dedifferentiation and the propensity for some benign tumours to progress to malignancy can confound histopathological interpretation.[7,8] However there are no reliable criteria to differentiate, on clinical grounds the benign from the malignant lesions and morphologic evaluation is necessary.[9] Hence the present study is undertaken to study the spectrum of histomorphological features of various neoplastic and non neoplastic salivary gland lesions.

MATERIALS & METHODS

The study was conducted in the department of pathology at Mahatma Gandhi MissionHospital, Navi Mumbai.The surgically resected salivary gland specimens between the periods of October 2007 and October 2014 prospectively as well as retrospectively.A total of 50 specimens of salivary gland lesions were studied. This study includes non neoplasticand neoplastic lesions of the salivary glands. The specimens consisted of biopsies , partial and total parotidectomies. Specimens were received in formalin and sections were processed and embedded in paraffin after gross examination. Haematoxylin and Eosin staining were done as routine in all the cases. Alcian Blue and Mucicarmine special stains were done wherever needed. Pathologic review included assessment of local invasiveness alongwith clinicopathological correlation in relation to age, sex and site of the tumour incidence with emphasis on the histological typing.

RESULTS

The present study was conducted over a period of 7 years from October 2007 to October 2014 in the department of pathology MGM Medical college and Hospital, Navi Mumbai.

Chronic sialadenitis (Fig. 1, 2) was the commonest non neoplastic lesion accounting for 7 cases (53.8%) out of 13 non neoplastic lesions. Pleomorphic adenoma[5] (Fig.3, 4, 5) was the most common benign tumor accounting for 24 cases (85.7%) of all benign tumors and 64.8% of all neoplastic tumors of the salivary glands. Mucoepidermoid carcinoma(Fig. 6, 7) was the commonest malignant tumor accounting for 5 cases (55.5%) out of 9 cases of the malignant tumors and 13.5% of all salivary gland tumors. A female preponderance was seen in almost all tumors except Warthin tumor (Fig.10) and a peak age incidence of 2nd to 6th decade. The commonest site was the parotid gland in 67.5% of all tumors followed by minor salivary glands and submandibular glands in 29.7% and 2.7% respectively. The most common clinical presentation was in the form of mass alone accounting for 31 cases(62%) followed by mass associated with pain in 8 cases(16%), with the duration being mostly less than 1 year.

In conclusion from the present study, it is evident that histopat hological examination of salivary gland lesions is the most important modality in establishing the final diagnosis in predicting prognosis and typing of non neoplastic and neoplastic lesions of salivary glands.

DISCUSSION

This study was conducted over a period of 7 years from October 2009 to October 2014 in the department of Pathology, Mahatma Gandhi medical college and hospital. Retrospective study of 16 cases and prospective study of 34 cases was done with respect to incidence, age, sex, clinical presentation, gross and microscopic features.

Table I: Incidence per year of salivary gland tumors in different studies.

SERIES	TOTAL NO. OF TUMORS	PERIOD OF STUDY (in years)	NO. PER YEAR
Ahmed et al[13]	100	2	50
Rewusuwan et al[15]	198	4	49
Edda et al[12]	268	10	27
Thomas et al[10]	190	9	21
Ito et al[15]	496	29	17

Nagarkar et al [11]	36	4	09
Agarwal et al [16]	147	17	08
Gupta et al [18]	113	21	05
Fenn et al [17]	57	15	04
Present study	37	7	5.28

In the present study incidence per year is 7.1% cases which correlates with Agarwal et al [16], Gupta et al [18] and Fenn et al [17].

Table II: Frequency of Neoplastic lesions (benign and malignant).

SERIES	TOTAL	BENIGN	MALIGNANT
Ito et al [14]	335	67.5%	32.5%
Edda et al [12]	125	53.4%	46.6%
Ahmed et al [13]	100	86%	14%
Nagarkar et al [11]	36	75%	25%
Present study	37	75.6	24.3%

Benign tumors predominate over the malignant tumors which was observed in the present study as well as those in the series.

Table III: Age distribution in different studies.

SERIES	BENIGN	MALIGNANT
Thomas et al [10]	39	47
Ahmed et al [13]	35.7	42.4
Edda et al [12]	38	44
Rewusuwan et al [15]	72	49
Agarwal et al [16]	35	42
Present study	35	42

Results in the study are consistent with other Indian studies. In most of the studies benign tumors occur at a lower age group than compared to malignant tumors.

Table IV: Sex distribution in different studies.

SERIES	TOTAL	BENIGN	MALIGNANT
Ahmed et al [13]	1.17:1	1.1:1	1.1:1
Edda et al [12]	1:1.3	1:1.4	1:1.1
Rewusuwan et al [15]	1:1.3	1:1.2	1:1.5
Present study	1:1.04	1.16:1	1:1.17

There was a slight female preponderance seen in this study similar to other studies.

Table V: Location of tumors in various sites in different studies.

SERIES	PAROTID	SUBMANDIBULAR	MINOR SALIVARY GLANDS
Rewusuwan et al [15]	79%	18%	2%
Edda et al [12]	34%	33.2%	32.8%
Buddhiraj et al [19]	82.8%	13.8%	3.4%
Ahmed et al [13]	70%	18%	12%
Present study	67.5%	2.7%	29.7%

The site distribution is consistent with that of Buddhiraj et al [19] and Ahmed et al [13] with predilection for parotid gland.

CONCLUSION

In conclusion from the present study, it is evident that histopathological examination of salivary gland lesions is the most important modality in establishing the final diagnosis in predicting prognosis and typing of non neoplastic and neoplastic lesions of salivary glands.

HISTOPATHOLOGICAL FIGURES:

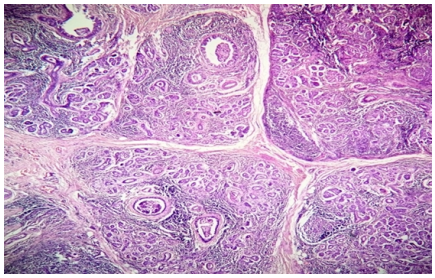

Fig. 1: H&E (10x) Chronic Sialadenitis showing dense lymphocytic infiltration.

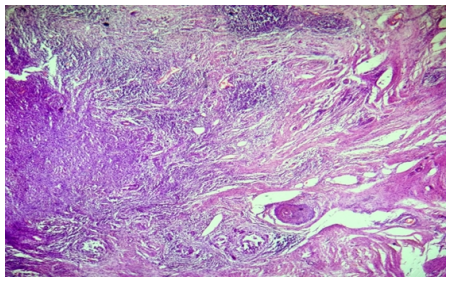

Fig. 2: H&E (40x) Kuttner's tumour (chronic sclerosing sialadenitis) showing fibrosis, sclerosis along with dense lymphoplasmacytic infiltration.

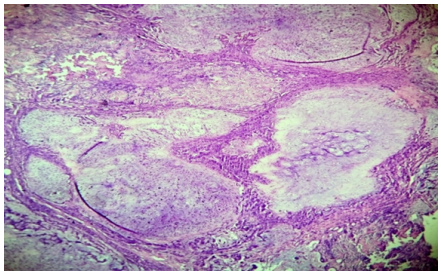

Fig. 3: H&E (40x) Pleomorphic Adenoma showing epithelial and myoepithelial against a chondromyxoid stroma

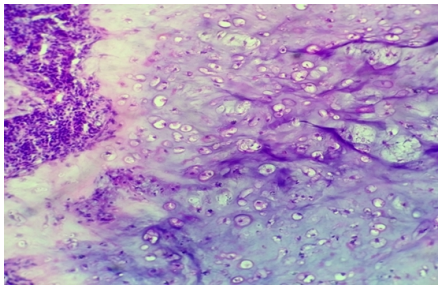

Fig. 4: H&E (100x) Pleomorphic Adenoma showing chondroid stroma comprising of mature chondrocytes.

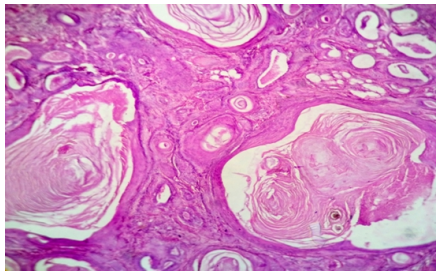

Fig. 5: H&E (100x) Pleomorphic Adenoma showing squamous differentiation comprising of well formed keratin pearls.

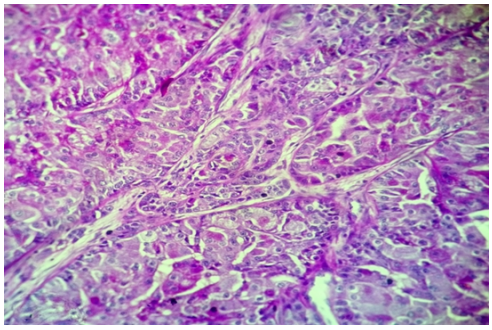

Fig. 6: H&E (100x) Mucoepidermoid carcinoma showing squamoid cells along with foamy cells.

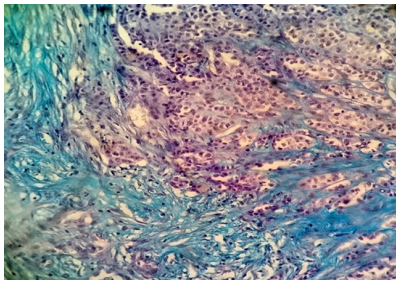

Fig. 7: Mucoepidermoid carcinoma showing squamoid cells along with foamy cells and mucin pools, AB (100x).

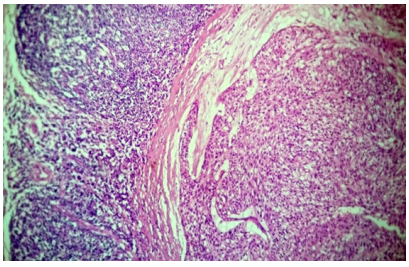

Fig.9: H & E (40x) Polymorphous low grade adenocarcinoma showing well circumscribed infiltrating tumor with tubular, ductular and glandular pattern.

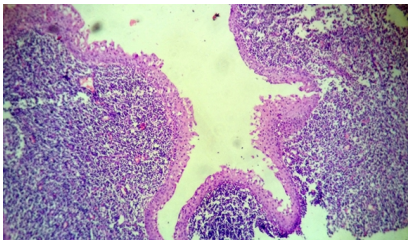

Fig. 10: H & E (40x) Warthin's tumor showing oncocytic cells in two cell layer (cuboidal basal cells and columnar luminal cells) with accompanying lymphoid stroma.

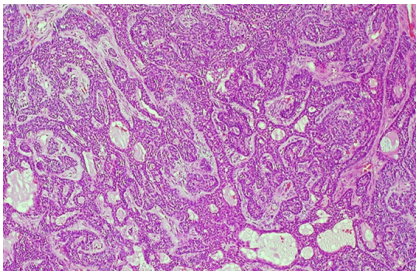

Fig. 11: H & E (40x) Basal cell adenoma showing islands of neoplastic epithelial cells with peripheral palisading.

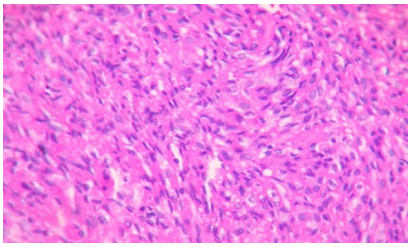

Fig. 12: H & E (40x) Myoepithelioma showing interlacing fascicles of spindle shaped cells with eosinophilic cytoplasm.

References:

1. Speight P, Barret A. Salivary gland tumors. Oral diseases 2002;8:229-40.
2. RHW Simpson. Classification of tumors of the salivary glands. Histopathology 1994;24:187-91.
3. TP Sajeevan, Joshua Elizabeth, TR Saraswathi, K Ranganathan. An analysis of salivary gland lesions – an institutional experience. J Oral Maxillofac patho 2003;7:21-4.
4. Maria P Foschini and Vincenzo Eusebi. Value of immunohistochemistry in diagnosis of salivary gland tumors. Pathology case reviews 2004;9:270-5.
5. Fabio A Alves, Daniel E.C Perez, Osley P Almeida, Marcio A Lopes, Luiz P Kowalski. Pleomorphic adenoma of submandibular salivary gland. Arch Otolaryngol Head neck surg 2002;128:1400.
6. Chan JK, Cheuk W. Salivary gland tumours. In: Fletcher CDM, editor. Diagnostic histopathology of tumours. 3rd ed. China: Churchill Livingstone Elsevier; 2007.p. 239-325.
7. Barnes L, Eveson JW, Reuichart P, Sidrawsky D. WHO classification of tumours. Pathology and Genetics of Head and Neck Tumours:Lyon: IARC Press; 2005. p. 209-81.
8. Lingel MW, Kumar V. Head and Neck. In: Kumar V, Abbas AK, Fausto N, editors. Robbins and Cotran Pathologic basis of disease, 7th ed. Philadelphia: Saunders; 2004. p.790-1.
9. Iwafuchi H, Mori N, Takahasi T, Yatabe Y. Phenotypic composition of salivary gland tumors. Mod Pathol 2004;17:803-10.
10. K M Thomas, M S R Hutt and J Borgestein. Salivary gland tumors in Malawi. Cancer 1980;46:2328-34.
11. Nagarkar NM, Bansal S,Dass A,Singhal SK, Harsh Mohan. Salivary gland tumors- our experience. Indian journal of otolaryngology and Head and neck surgery 2004;56:31-4.
12. Edda A M Vuhahula. Salivary gland tumors in Uganda:clinical pathological study. African Health sciences 2004;4:15-23.
13. Shafkat A, Mohammad L, Rouf A. Clinicopathological study of primary salivary gland tumors in Kashmir. JK Practitioner 2002;9:231-3.
14. F A Ito, K Ito, P A Vargas, O P de Almeid and M A Lopes. Salivary gland tumors in a Brazilian population: a retrospective study of 496 cases. Int J Oral Maxillofac Surg 2005;34:533-6.
15. Rewusuwan S, Settakorn J, Mahanupab P. Salivary gland tumors in Maharaj Nakorn Chiang Mai hospital: A retrospective study of 198 cases. Chiang Mai Med Bull 2006; 45:43-5.
16. Agarwal RV, Solanki BR, Junnarkar RV. Salivary gland tumor. Ind J Cancer 1967;4:209-13.
17. Fenn AS, Gammon KL, Krishnan KV, Rao PSV. Salivary gland tumor. Ind J Surg 1982;44:101-4.
18. Gupta SK, Sengupta P, Sarkar SK. Primary tumors of salivary glands. J Ind Med Assoc. 1975;65:277-80.
19. Buddhraj SN, Pasupathy, Perianayagam. Salivary gland tumors in Pondicherry. Ind J Surg 1974;36:235-9.