ORIGINAL RESEARCH PAPER
Volume-6 | Issue-11 | November-2017 | ISSN No 2277 - 8179 | IF : 4.176 | IC Value : 78.46
INTERNATIONAL JOURNAL OF SCIENTIFIC RESEARCH

SPECTRUM OF UNUSUAL PRESENTATIONS OF MUCORMYCOSIS

Pathology

Dr. Ram Nawal Rao* M.D, Additional Professor, Pathology Department, Sanjay Gandhi Postgraduate Institute of Medical Sciences, Lucknow 226014, UP, India *Corresponding Author

Dr. Pallavi Prasad M.D, Senior Resident, Pathology Department,Sanjay Gandhi Postgraduate Institute of Medical Sciences, Lucknow 226014, UP, India

Dr. M S Ansari MCH, Professor, Department of Urology, Sanjay Gandhi Postgraduate Institute of Medical Sciences, Lucknow, India.

Dr Raj Kumar MCH, Professor and Head, Department of Neurosurgery, Sanjay Gandhi Postgraduate Institute of Medical Sciences, Lucknow, India.

ABSTRACT

Introduction: Mucormycosis is a relatively rare opportunistic fungal infection and occurs chiefly in immunocompromised hosts. The objective of the present study is to document the clinical profile of Mucormycosis occurring at various sites in patients of a tertiary health care centre.
Materials and Methods: Our series compromised of 16 cases seen over a period of 8 years. Detailed history, clinical examination, laboratory investigations were carried out in all the cases.
Results: The study group consisted of 12 males and 4 females aged 6-75 years (mean 37.2 years). Cultures were positive for Mucorales in 9 cases. 12 patients were treated with antifungal drugs and five warranted surgical intervention.
Conclusions: Mucormycosis is a rare opportunistic fungal infection with rapidly progressive and fulminant course, carrying a fatal outcome. In most cases, a strong clinical suspicion, rapid accurate diagnosis with the help of pathological confirmation and aggressive surgical treatment carries a better outcome.

KEYWORDS

Mucormycosis, Fungal, Amphotericin, Malignancy, Zygomycosis

Introduction:
Mucormycosis is a rare infection caused by fungi known as Mucoromycotina belonging to the order Mucorales. It is also called zygomycosis and known to be the third most common angio-invasive fungal infection in immunocompromised patients,thecommoner ones being candidiasis and aspergillosis[1,2]. Prognosis is influenced by quick diagnosis and the underlying presdisposing factors[3,4]. We report 16 cases of Mucormycosis occurring at unusual sites.

Materials and methods:
We collected the data of the cases from the Hospital Information system of SGPGI. From January 2010 to august 2017, a total of 16 cases of mucormycosis were retrieved. The diagnosis was made on histopathological examination of paraffin embedded H & E, PAS and methenamine silver stained slides. Presence of septate or pauciseptate, broad, thin-walled fungal hyphae branching at right angles were further taken up for microscopic examination in a 20% KOH mount and fungal culture.The patient age, gender, underlying disorders, clinical features, risk factors, diagnostic underlying conditions, site of infection, clinical signs and symptoms of infection, radiological findings, treatments, and outcome were recorded.

Results:
The study group consisted of 12 males and 4 females, aged 6-75 years (mean 37.2 years). Out of 16 cases, 5 occurred in kidneys**(Fig 1a,1b,1c,1d, 1e)**, 2 in lungs, brain**(Fig 2a 2b)**, nose and 1 in bronchus, orbit and liver each**(Fig 2c, 2d)**. 2 cases presented as subcutaneous swellings over patella and hand**(Fig 1f)**. Renal transplant was identified as the predisposing risk factor in 4 cases, diabetes mellitus in 6 cases, NODAT in 2 cases and in 7 cases, no underlying risk factor could be ascertained. The histopathological diagnosis of mucormycosis was made in all cases and in 1 case, concomitant aspergillus was also identified. However, cultures were positive for mucorales in 9 cases, it was not done in 2 cases and in the remaining, it failed to show growth of any fungal element**(Table1)**.

12 patients were treated with antifungal agents (amphotericin B, voriconazole, posaconazole, capsofungin). Duration of the treatment varied from 1 – 30 days. Additional surgery was performed in all 5 cases with renal infection and 1 case with orbital involvement. 5 patients died after histopathological diagnosis and in one case, the diagnosis was made on post-mortem liver biopsy.

Discussion:
Mucormycetes (formerly called zygomycetes) includes various genera - Rhizopus, Lichtheimia (formerly Absidia), Apophysomyces, Cunninghamella, Saksenaea, Rhizomucor, and Mucor [5]. It is a fatal infection occurring in immunocompromised hosts. The different forms of mucormycosis are rhino-orbital-cerebral, pulmonary, disseminated, cutaneous, gastrointestinal and miscellaneous [6-8].

The causative organism gains entry into the body via the upper aerodigestive tract. The invasive form grows along the internal elastic lamina of arteries, penetrates the endothelium and causes thrombosis, stroke and tissue necrosis [9], causing local destruction of the affected organs. Mucormycosis primarily causes tissue and blood vessel invasion. The fungal proliferation is further aided by the hypoxic environment[10]. The sporangiospores gain entry through inhalation or contaminated wounds or burns of patients with predisposing conditions such as diabetes or immunosuppression or trauma [11]. In our study, diabetes was identified as the predisposing factor in 6 cases, renal transplant immunosupression in 4 cases. However, the disseminated infection occurs in patients with malignancies, transplantations, metabolic diseases, malnutrition, chemo, radio and/or immunosuppressive therapy[12]. One of our case which had mucor infection in liver presented to clinician with signs of acute liver failure and severe pneumonia. However, she succumbed within a week of admission.

Successful therapy of isolated renal mucormycosis (IRM) necessitates surgical debridement of infected and necrotic tissue, Amphotericin B medication, and treatment of predisposing factors [13]. Amphotericin B administration in combination with nephrectomy is the treatment of choice in such patients[14]. Our patient of IRM was a young immunocompetent female who responded well to treatment.The overall survival is recorded to be around 65% [15]. All 5 renal mucormycosis cases in our study underwent surgery along with antifungal treatment.

Finally, primary cutaneous mucormycosis is a comparatively uncommon entity and carries better prognosis in organ transplant patients[16]. It tends to occur earlier after transplantation and shows better outcomes as compared to other forms of mucormycosis [17]. Both of our cases with cutaneous infection were renal transplant recipients and the diagnosis was made on fine needle aspiration cytology. Hence, in all cases, definitive diagnosis should be made by

clinical evaluation, histopathological examination of infected tissues, culture and imaging studies.

Renal Zygomycosis can also occur in healthy immuno competentindividuals. Bilateral renalzygomycosisshould be suspected in any patient who presents withhematuria, oligoanuria, flank pain and otherwise unexplaineddiffuse acute abdominal pain, especially if hehas an epidemiological link to India.If the sepsis and flank pain are not explained by acutepyelonephritis, immediate contrast enhanced CT scanshould be done, if the patient's serum creatinine isnormal or else a noncontrast CT is also supportive. Nephrectomy should not be delayed while special fungal stains take 24–48 hr to get validated.Each hour is crucial in renal zygomycosis. Time tonephrectomy is a strong predictor of mortality. Even after nephrectomy, an aggressive approach iswarranted with regard to the management of acidosis, electrolyte imbalance and septicemia. Liposomal Amphotericin B should be used insteadof conventional preparation especially if the disease isbilateral and the patient has elevated serum creatinine (18).

CONCLUSION:

We concluded that the mucormycosis is an aggressive and devastating infection of immunocompromised hosts. A high index of clinical suspicion, followed by histopathological examination of surgical tissue, treatment of the underlying predisposing factors, antifungal therapy and surgery wherever indicated are required in such cases. The present study highlights the clinicopathological spectrum of mucormycosis occurring at various unusual sites.

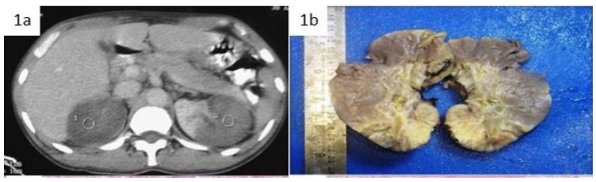

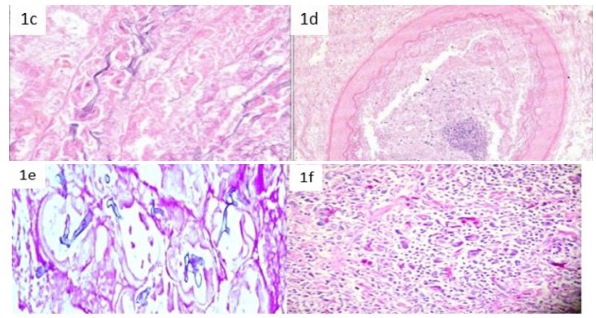

Fig (1a) Figure 1a: A CT scan demonstrating bilateral hypodense kidneys with preserved blood flow at the left upper pole, 1b : Nephrectomy specimen show necrostic renal parenchyma, 1c: Histopathology from the kidney specimen showing right angle broad based branching non septate hyphe in the tubules and glomeruli suggestive of renal Zygomycosis, the glomeruli were degenerated and disrupted along with vascular invasion in the intrarenal vessels (1d) by mucormycosis (h&e), 1e: CSM showed Mucormycosis. 1f : PAS on section from hand swelling showed mucormycosis

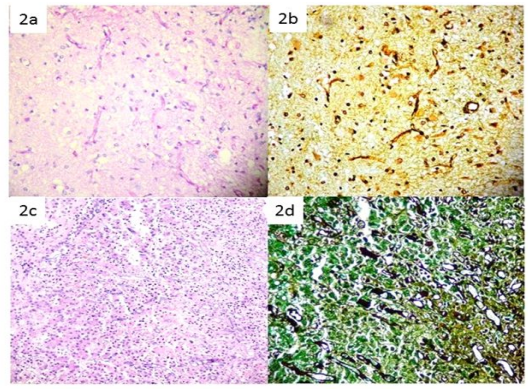

Figure (2a): Temporal region show Broad based fungal Hyphae (h&e), 2b: CSM stain showed mucormycosis, 2c: Liver biopsy show broad based fungal hyphae with inflammatory cells and 2d: CSM stain showed mucormycosis.

Table 1: Description of Mucormycosis cases at unusual presentation in body

S. No	Age	Sex	Site	Clinical History	Clinical Diagnosis	Histopathological Feature	Culture	Treatment
1	49	M	Right lung biopsy& Lobectomy	Post renal transplant, Hep B+, Hep C +DM	Malignancy	Fungal inflammation, necrosis, giant cells s/o Zygomycosis	No growth	Voriconazole Taxim, Levoflox Wysolone
2	68	M	Bronchus	Hypertension, right lobe liver abscess	Liver abscess	Zygomycosis	Not done	NA
3	35	M	Orbit	Visual loss (rt eye followed by left), DM, headache, B/L frontal lobe involvement, GTCS, loss of consciousness	Malignancy	Angioinvasive Zygo+aspergillus	Growth of apergillous, NoZygo as sample was received after AMB treatment	Surgical exentration AMB injection
4	43	M	Kidney	Renomegaly, bilateral renal infarct, acute renal failure, Fever, dysuria, bilateral pleural effusion, ascites	Infective disease, vasculitis, acute pyelonephritis	Zygomycosis	Growth of Zygo after 24 hrs of incubation	No response to medical, bilateral nephrectomy done, Died
5	45	M	Kidney	Flank pain, high grade fever, dysuria, chills, rigor, recent onset of hyperglycemia, right nephromegaly	Fungal Infection	Coagulative necrosis, Angioinvasive mucormycosis	Growth of zygo after 72 hrs of incubation	Surgery+ Amphotericin B
6	14	M	Fronto-parietal lobe	Recurrent seizures, drowsiness, weakness left half of body. MRI : well-encapsulated abscess in rightfrontoparital region	Fungal abscess	Fungal abscess s/o pheohyphomycetes	Growth ofPheo (black mycelial fungus) after >1wk of incubation	Injection amphoteriviin Voriconazole
7	23	F	Kidney biopsy followed by subcapsular nephrectomy	Fever, nausea, vomiting, flank pain,CT : wedgre-shaped non-enhancing area in upper and mid pole s/o infarct, Righ lung pneumonia	Fungal pyelonephritis	Fungal inflammation, cortical necrosis, granuloma, angioinvasion	No growth	Right nephrectomy Amphotericin Posaconazole Stable on discharge
8	28	M	Patella	Case of renal transplant, NODAT, hba1c=6.1%, 1.5x1.5cm swelling	Fungal disease	Fungal granuloma s/o pheohypomycosis	No growth	Voriconaole
9	53	M	Temporal lobe	C/o DM, Hypertension, pus-discharge at surgical site (frontotemporal craniotomy for tubercular abscess)	Tuberculosis	Granuloma, giant cells, fungal inflammation	Growth of mucor - mycosis after 48 hrs of incubation	Posaconazole

10	28	M	Right hand	Renal transplant recipient on TAC/MMF/prednisolone, hypertension, post-transplant hyperglycemia	Fungal Infection	Granuloma, necrosis, fungal inflammation	Growth of black mycelial fungus (phaehypomycosis) after 1 week of incubation	Voriconazole
11	75	M	Sinonasal mass	DM, hypertension, CKD, mass in left maxillary sinus and forehead, passage of clots from left nostril, difficulty in opening left eye.	Malignancy Fungal infection	Granulation tissue s/o mucormycosis	Growth of mucormycosis and aspergillus after 1 week of incubation	Died
12	28	M	Lung	Renal transplant recipient H/o pulmonary TB-took ATT, fever with chills, cough with expectoration	Tuberculosis	Necrosis, giant cells, angioinvasion, fungal inflammation s/o mucormycosis	No growth	Amphotericin Capsofungin, Died
13	15	M	Kidney	Fever, chills and rigor, Left kidney enlarged, hypoechoic	Fungal infection, malignancy, TB	Necrosis, fungal inflammation s/o mucormycosis	No growth (done thrice)	Amphotericin
14	6	F	Liver Postmortem	Altered sensorium, seizures, fever, loss of appetite, jaundice, acute liver failure, severe pneumonia, ARDS	Acute liver failure	Mucormycosis	Not done	Died
15	23	F	Left kidney	DM, Hereditory spherocytosis post splenectomy status admitted in medical genetics for high grade fever with chills	Renal infarction	Necrosis, giant cells, inflammation s/o mucormycosis	Growth of mucor after 1 week of incubation	Antifungals Antibiotics Dead
16	62	F	Nasal cavity	Left side proptosis, diminished vision, HT	Malignancy, fungus abscess	Necrosis, inflammation s/o mucormycosis	Growth of mucor after 1 week of incubation	Amphotericin

References :

1. M. Torres-Narbona, J. Guinea, P. Munoz, E. Bouza. Zygomycetes and zygomycosis in the new era of antifungal therapies. Rev Esp Quimioter, 20 (2007), pp. 375-386.
2. M. Chayakulkeeree, M.A. Ghannoum, J.R. Perfect Zygomycosis: the re-emerging fungal infection. Eur J Clin Microbiol Infect Dis, 25 (2006), pp. 215-229.
3. Roden MM, Zaoutis TE, Buchanan WL, Knudsen TA, Sarkisova TA, Schaufele RL, Sein M, Sein T, Chiou CC, Chu JH et al. Epidemiology and outcome of zygomycosis: a review of 929 reported cases. Clin Infect Dis 2005; 41: 634–653.
4. Skiada A, Pagano L, Groll A, Zimmerli S, Dupont B, Lagrau K, Lass-Florl C, Bouza E, Klimko N, Gaustad P et al. Zygomycosis in Europe: analysis of 230 cases accrued by the registry of the European Confederation of Medical Mycology (ECMM) Working Group on Zygomycosis between 2005 and 2007. Clin Microbiol Infect 2011; 17: 1859–1867.
5. Alvarez E, Sutton DA, Cano J, Fothergill AW, Stchigel A, Rinaldi MG, et al. Spectrum of zygomycete species identified in clinically significant specimens in the United States. J Clin Microbiol 2009;47:1650–6.
6. Baker RD. The phycomycoses. Anna N Y Acad Sci 1970; 174: 592-605.
7. Morduchowicz G, shmueli D, Shapira Z et al. Rhinocerebral Mucormycosis in renal transplant recipients: report of three cases and review of the literature. Rev Infect Dis 1986;8:441-6.
8. Yohai RA, Bullock JD, Aziz AA, et al. Survival factors in rhino-orbito-cerebral Mucormycosis. Surv ophthalmo 1994;39:3-22.
9. Santos Gorjón P, Blanco Pérez P, Batuecas Caletrío A, Muñoz Herrera AM, Sánchez González F, de la Fuente Cañibano R. Rhino-orbito-cerebral mucormycosis: a retrospective study of 7 cases. Acta Otorrinolaringol Esp. 2010 Jan-Feb;61(1):48-53.
10. Scheckenbach K, Cornely O, Hoffmann TK, Engers R, Bier H, Chaker A, et al. Emerging therapeutic options in fulminant invasive rhinocerebral mucormycosis. Auris Nasus Larynx 2010;37:322-8.
11. Clóvis Klock, Ivan Tadeu Rebouças, Ane Cristine Zenella Monteiro. Rhino-cerebral zygomycosis in a diabetes mellitus patient. Case report. Congreso de Anatomía Patológica. 2005 Oct;18:1-3.
12. R.M. Prabhu, R. Patel Mucormycosis and entomophthoramycosis: a review of the clinical manifestations, diagnosis and treatment Clin Microbiol Infect, 10 (Suppl 1) (2004), pp. 31-47.
13. K. L. Gupta, K. Joshi, K. Sud, et al. Renal zygomycosis: an under-diagnosed cause of acute renal failure. Nephrol Dial Transplant 1999; 14 (11): 2720-2725.
14. Elliott Levy and Margaret J. Bia. Isolated Renal Mucormycosis: Case Report and Review. J. Am. Soc. Nephrol. 1995; 5:2014-2019.
15. Verma R, Vij M, Agrawal V, Jain M. Renal mucormycosis in immunocompetent patients: report of three cases. Basic ApplPathol.2011; 4:66–70.
16. Nouri-Majalan N, Moghimi M: Skin mucormycosis presenting as an erythema-nodosum-like rash in a renal transplant recipient: a case report. J Med Case Reports, 2008; 2: 112.
17. Page AV, Evans AJ, Snell L, Liles WC: Primary cutaneous mucormycosis in a lung transplant recipient: case report and concise review of the literature. Transpl Infect Dis, 2008; 10(6): 419–25.
18. Priyadarshi Ranjan, Ram Nawal Rao, Ranjana Singh, Rakesh K. Gupta, Rakesh Kapoor andRaj K. Sharma. Emerging role of radiological criteria for antemortem diagnosis of renalzygomycosis: an uncommon cause of acute renal failure. NDT Plus (2011) 0: 1–4. doi: 10.1093/ndtplus/sfr059.