Research Paper

Volume : 4 | Issue : 9 | Sept 2015 • ISSN No 2277 - 8179

# Spontaneous splenic rupture during staging of colon cancer: a case report and review of the literature

Medical Science

**KEYWORDS :** spleen, spontaneous splenic rupture, sigmoid tumour.

**Gaby Jabbour** — Department of Surgery, Hamad General Hospital, Doha, Qatar

**Ahmad Nizar Hachem** — Department of Surgery, Hospital Verge de la Cinta, Tarragona, Spain

**Syed Muhammad Ali** — Department of Surgery, Hamad General Hospital, Doha, Qatar

## ABSTRACT

*We present a case of spontaneous splenic rupture during staging of colon cancer in a female patient who presented with an obstructing sigmoid tumour. We also review the pertinent literature. A 54-year-old woman presented with vomiting, abdominal pain and distention. The diagnostic work-up comprised clinical examination, computed tomography, colonoscopy, stenting, and a sodium diatrizoate and meglumine diatrizoate enema. Twenty-four hours later, the patient presented to the emergency department with acute abdominal pain and hemodynamic instability. A diagnosis of spontaneous splenic rupture was made and a splenectomy together with Hartmann procedure (resection of the rectosigmoid colon with closure of the rectal stump and formation of an end colostomy) performed. The patient had an uneventful postoperative course and was discharged on day 8. She received 12 cycles of adjuvant chemotherapy (oxaliplatin, high-dose leucovorin and 5-fluorouracil) thereafter and was disease free 18 months postoperatively.*
*To the best of our knowledge, this is the first reported case of spontaneous splenic rupture occurring during staging of colon cancer.*

**Introduction**

Spontaneous splenic rupture was first described in 1874 by Atkinson [1]. It can affect a diseased spleen or a previously normal spleen (Orloff and Peskin's criteria [2]). Associated pathologies include hematologic, infectious, and metabolic diseases.

Sodium diatrizoate and meglumine diatrizoate is a water soluble combination of contrast media that is scarcely absorbed: only 3% generally being absorbed after oral administration. However, even in the absence of perforation, absorption of greater amounts of these compounds (demonstrated by opacification of the renal calyces and ureters) has been observed in some patients. We herein present a case report of spontaneous splenic rupture following an enema of sodium diatrizoate and meglumine diatrizoate, which was administered to determine whether any synchronous lesions were in the colon beyond an obstructing sigmoid tumour. This case is remarkable in that radio-opaque material was seen in the urinary tract. We also present a review of pertinent published reports.

**Case report**

A 54-year-old, previously healthy Spanish woman presented to the emergency department with vomiting, abdominal pain and distention. On physical examination she had remarkable abdominal tenderness and distention.

Computed tomography showed dilation of the colon at the level of the splenic flexure caused by an obstructing sigmoid neoplasm (Fig. 1). Colonoscopy performed up to 22 cm revealed a 4 cm stenosis caused by an obstructing tumour involving the whole circumference. Stenting was performed using a 120–25 mm uncoated self-expanding Wallflex stent (Boston Scientific) (Fig. 2). A radiocontrast enema study, performed subsequently to exclude the presence of any synchronous lesions beyond the obstructing tumour, revealed no abnormalities. Interestingly, contrast material was visible in the urinary tract bilaterally, both kidneys being evenly displayed (Fig. 3).

Twenty-four hours after undergoing this procedure, the patient presented to the emergency department with acute abdominal pain and hemodynamic instability. An urgent abdominal CT scan showed splenic rupture with massive haemoperitoneum; the stent appeared to be functioning normally (Figs. 4, 5). Urgent laparotomy revealed splenic rupture with haemoperitoneum and a splenectomy together with Hartmann's procedure (resection of the rectosigmoid colon with closure of the rectal stump and formation of an end colostomy) were performed. Upon further questioning, the patient denied any trivial trauma or other possibly relevant events. Review of an ultrasound examination performed pre-operatively to exclude liver metastasis showed no evidence of splenic abnormalities (Fig. 6).

Histopathological examination showed an infiltrating low-grade adenocarcinoma with no lymph node infiltration (0/23): T4 N0 M0 and splenic rupture with congestive splenitis and small calibre hyaline vasculature. No underlying splenic disease was identified. The patient had an uneventful postoperative course and was discharged on day 8. She received 12 cycles of adjuvant chemotherapy (oxaliplatin, high-dose leucovorin and 5-fluorouracil) and was disease free 18 months postoperatively.

PubMed and Google Scholar were used to search for similar published cases. No reports of splenic rupture following administration of rectal contrast material during staging of colorectal cancer were identified.

**Discussion**

Diatrizoate meglumine and diatrizoate sodium solution is a water-soluble iodinated radiopaque mixture for oral or rectal use. It is scarcely absorbed by the gastrointestinal (GI) tract, absorption following oral administration being only 3%. Even in the absence of perforation, absorption of greater amounts (demonstrated by opacification of the renal calyces and ureters) has been observed in some patients; that is, GI absorption of unusually large amounts allows incidental visualization of the urinary tract. Administration of greater than 1000 mL of such contrast media can cause increased enteral absorption. In addition, stent placement can cause small mucosal tears that can lead to increased contrast absorption.

There are two main types of splenic rupture: spontaneous (pathological or normal spleen) and traumatic. Atraumatic rupture of the spleen has been reported: it is a rare and serious condition if unrecognized [3]. Clinical signs of splenic rupture include tenderness and guarding in the left upper quadrant of the abdomen along with features of haemorrhagic shock [4]. In the absence of a history of trauma, other differential diagnoses should be considered, particularly perforated peptic ulcer. Occasionally, patients may have a variety of symptoms, suggesting angina pectoris, myocardial infarction, pulmonary embolism, and ectopic pregnancy.

Orloff and Peskin critically reviewed 71 cases of spontaneous splenic rupture that had been reported in English up until 1958 [2]. They proposed four criteria for defining what they referred to as spontaneous splenic rupture:

- Thorough, repeated questioning has failed to reveal a history of trauma or unusual effort that could injure the spleen.
- No evidence of disease in other organs that is known to affect the spleen such that it could rupture.
- No perisplenic adhesions or splenic scarring suggestive of previous trauma or rupture.
- Other than the findings of haemorrhage and rupture, the spleen should be normal on both gross and histological examinations.

Reported pathologies associated with spontaneous splenic rupture include hematologic (anticoagulant therapy, leukaemia), infectious (infectious mononucleosis, hepatitis), and metabolic diseases (amyloidosis, sarcoidosis).

**Conclusion**

In summary, spontaneous splenic rupture following a radiocontrast enema during staging of colorectal cancer is very rare. Because colonoscopy was incomplete in this case (up to 22 cm; that is, not reaching the splenic flexure), the colonoscopy procedure could not have caused minor trauma to the spleen. However, the role of the stent in the unusually great absorption of contrast or in splenic rupture is unclear. Baillie stated "careful enough questioning will always reveal a story of injury" [5]. However, a thorough history revealed no trauma or trivial injury. It is possible that the association we have here reported between radiocontrast enema, colonoscopy and splenic rupture is not causal.

**Competing interests**

The authors declare that they have no competing interests.

**Consent**

Written informed consent was obtained from the patient for publication of this case report and any accompanying images.

**Figure 1: Abdominal CT scan image showing an obstructing sigmoid tumour.**



**Figure 2: Photograph of colonoscopic stenting of the obstructing sigmoid tumour.**



**Figure 3: Radiocontrast study showing contrast in the urinary tract.**

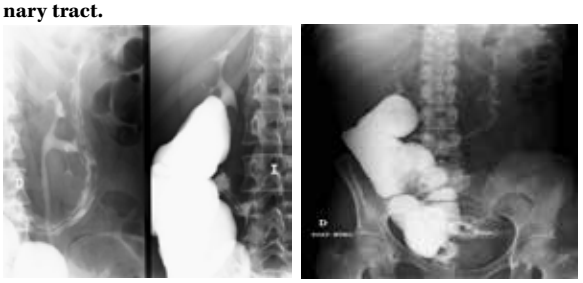

**Figures 4, 5: Abdominal CT scan images showing haemoperitoneum and normally functioning stent.**

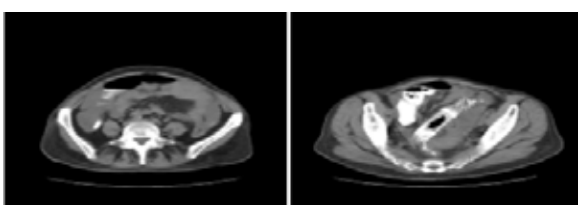

**Figure 6: Pre-operative ultrasound showing normal spleen**




## REFERENCE

1. Atkinson, E. (1874) Death from idiopathic rupture of the spleen. BMJ, 2: 403–4. | 2. Orloff, M. J. and Peskin, G. W. (1958) Spontaneous rupture of the normal spleen—a surgical enigma. Int Abstr Surg, 106: 1–11. | 3. Hyun, B. H., Varga, C. F. and Rubin, R. J. (1972) Spontaneous and pathologic rupture of the spleen. Arch Surg, 104: 652–7. | 4. Jahadi, M. R., Bailey, W. and Crenshaw, A. 91975) Atraumatic splenic rupture simulating ruptured sigmoid diverticulitis. Dis Colon Rectum, 18: 59–61. | 5. Baillie, R. W. (1952) Delayed haemorrhage following traumatic rupture of the normal spleen simulating spontaneous rupture. Postgrad Med J, 28: 494. |